



Clinical Characteristics and Management of Benign Transient Non-Organic Ileus of Neonates: A Single-Center Experience

Hye Kyung Chang,¹ Hong Koh,² Young Ju Hong,³ Eun Young Chang,³ Seok Joo Han,³ and Jung-Tak Oh³

¹Department of Surgery, Seoul St. Mary's Hospital, The Catholic University of Korea College of Medicine, Seoul;

Departments of ²Pediatrics and ³Pediatric Surgery, Severance Children's Hospital, Yonsei University College of Medicine, Seoul, Korea.

Received: March 14, 2013

Revised: April 22, 2013

Accepted: April 26, 2013

Corresponding author: Dr. Jung-Tak Oh,
Department of Pediatric Surgery,
Severance Children's Hospital,
Yonsei University College of Medicine,
50 Yonsei-ro, Seodaemun-gu,
Seoul 120-752, Korea.
Tel: 82-2-2228-2124, Fax: 82-2-313-8289
E-mail: jtoh@yuhs.ac

· The authors have no financial conflicts of interest.

Purpose: The term benign transient non-organic ileus of neonates (BTNIN) is applied to neonates who present symptoms and plain radiographic findings of Hirschsprung's disease, but do not have aganglionic bowel and are managed well by conservative treatment. It can often be difficult to diagnose BTNIN because its initial symptoms are similar to those of Hirschsprung's disease. The aim of this study is to evaluate the clinical characteristics and proper treatment of BTNIN. **Materials and Methods:** A retrospective review was made on the clinical data of 19 neonates who were treated for BTNIN between January 2008 and December 2011 at a single facility. **Results:** Abdominal distension occurred in every patient (19/19). Other common symptoms included emesis (5/19), explosive defecation (5/19), and constipation (4/19). The vast majority of patients (15/19) experienced the onset of symptoms between 2 and 4 weeks of age. Radiograph findings from all of the patients were similar to Hirschsprung's disease. A barium study showed a transition zone in 33.4% (6/18) of the patients. However, rectal biopsy revealed ganglion cells in the distal rectum in 88.2% (15/17) of the patients, and anorectal manometry showed a normal rectoanal inhibitory reflex in 90% (9/10). All patients responded well to conservative treatment. Symptoms disappeared at the mean age of 4.9±1.0 months, and the abdominal radiographs normalized. **Conclusion:** BTNIN had an excellent outcome with conservative treatment, and must be differentiated from Hirschsprung's disease. A rectal biopsy and anorectal manometry were useful diagnostic tools in the differential diagnosis.

Key Words: Ileus, neonate, Hirschsprung's disease, transient

INTRODUCTION

First described in 1886, Hirschsprung's disease is generally suspected in neonates and infants with abdominal distension and constipation.¹ Pediatricians or pediatric surgeons often encounter patients whose symptoms are similar to Hirschsprung's disease, however, ganglion cells are present in their rectal biopsies and their clinical course are different from the Hirschsprung's disease. These patients are variously labeled with pseudo-Hirschsprung's disease, neonatal intestinal pseudo-obstruction, intestinal neuronal dysplasia, hypoganglionosis, and internal anal sphincter achala-

© Copyright:

Yonsei University College of Medicine 2014

This is an Open Access article distributed under the terms of the Creative Commons Attribution Non-Commercial License (<http://creativecommons.org/licenses/by-nc/3.0>) which permits unrestricted non-commercial use, distribution, and reproduction in any medium, provided the original work is properly cited.

sia. Most of these terms are now considered variants of Hirschsprung's disease.²

Interestingly, however, some patients could not be classified as the variants of Hirschsprung's disease because their symptoms disappear spontaneously without any specific treatment, even though their symptoms and radiologic findings are not distinguishable from the Hirschsprung's disease. Yamauchi, et al.³ first coined the term benign transient non-organic ileus of neonates (BTNIN) in 2002. This entity is likely more common than originally thought, but the detailed characteristics are not fully understood. The aim of this study is to describe our experiences with BTNIN and evaluate the clinical characteristics and proper treatment of BTNIN.

MATERIALS AND METHODS

A retrospective review was made on the clinical data from

Table 1. Clinical Characteristics of the Patients

Characteristics	
Cases	19
Sex (M/F)	11/8
Gestational age (wks)	37.7±2.1
Birth weight (kg)	3.1±0.4
Feeding	
Breast	17*
Formula	2
Symptoms	
Abdominal distension	19
Vomiting	5
Explosive defecation	5
Constipation	4
Diarrhea	2
Onset of symptoms	
2-4 wks of age	15
<1 wk of age	4

*Two patients were changed to mixed feeding (breast and formula) due to insufficient amounts of breast milk.

Table 2. Diagnostic Studies for Benign Transient Non-Organic Ileus of Neonates

	Total	Normal	Abnormal
Barium study	18	12 (66.7%)	6*
Rectal biopsy	17	15 (88.2%)	2 [†]
Suction	14	12	2
Full thickness	1	1	0
Anorectal manometry	10	9 (90%)	1 [‡]

*Presence of transition zone.

[†]Absence of ganglion cells.

[‡]Absence of rectoanal inhibitory reflex.

patients who were treated for BTNIN at Severance Children's Hospital in Seoul, Korea between January 2008 and December 2011. A diagnosis of BTNIN was established based on previously published criteria: presence of a non-organic ileus of the neonate excluding Hirschsprung's disease, Hirschsprung's disease-allied disorders, and functional ileus associated with meconium obstruction.³ Nineteen patients were treated during the study period, and no patients were excluded from the study. Patients' demographics, symptoms, diagnostic studies, and clinical courses were analyzed.

This study was approved by the Institutional Review Board of Severance Children's Hospital.

RESULTS

Clinical characteristics

The clinical characteristics of the patients are shown in Table 1. All of the patients were healthy neonates, and only one patient was born at less than 35 weeks gestational age with a birth weight of 2.5 kg. All but two patients were breast-fed. Abdominal distension occurred in all of the patients. Emesis (5/19), explosive defecation (5/19), and constipation (4/19) were other common symptoms. The onset of majority (79%) of patients' symptoms was between 2 and 4 weeks of age. Four patients' symptoms began within the first week of life.

Diagnostic studies (Table 2)

Plain radiograph findings from all of the patients were similar to Hirschsprung's disease (Fig. 1A, B and C). A barium study was performed on 94.7% (18/19) of the patients, and 33.4% (6/18) of those patients showed the transition zones (Fig. 1D, E and F). Twenty-four hour delayed radiographs were available in 16 patients, and 62.5% (10/16) showed retained contrast. However, rectal biopsies identified ganglion cells in the distal rectum in 88.2% (15/17) of the patients without findings of any other diseases. The two patients without identified ganglion cells did not undergo repeated rectal biopsies because of normal findings on the barium studies and rapid improvement in symptoms. Anorectal manometry also showed a normal rectoanal inhibitory reflex in 90% (9/10) of the patients.

Clinical outcomes

All patients responded well to conservative treatment of intermittent glycerin enema. The frequency of glycerin enemas

depended upon the symptoms, and ranged from daily to once weekly. No other medications were administered to relieve the symptoms, and the feeding strategy did not change because the symptoms gradually improved. After 4.4 ± 1.1 months of conservative treatment, the symptoms disappeared by the mean age of 4.9 ± 1.0 months (range, 2.8-6.6 months). The abdominal radiographs also normalized (Fig. 1G, H and I).

DISCUSSION

Although the term of 'benign transient non-organic ileus of

neonate' is not well established yet, it should be considered in the differential diagnosis of Hirschsprung's disease. First reported in 2002,³ BTNIN did not receive much attention from pediatric surgeons because of its favorable clinical course, and very few supportive articles have been published.^{4,5} However, the age at the definitive surgery of Hirschsprung's disease is far younger than previous decade and one-stage procedure has been popular.⁶⁻⁸ These new treatment strategies require early and reliable diagnosis.⁹⁻¹¹ Consequently, it is more important than ever to differentiate Hirschsprung's disease from other nonsurgical conditions.⁹⁻¹¹

The most important characteristics of BTNIN are its similarity to Hirschsprung's disease. In our present study, the

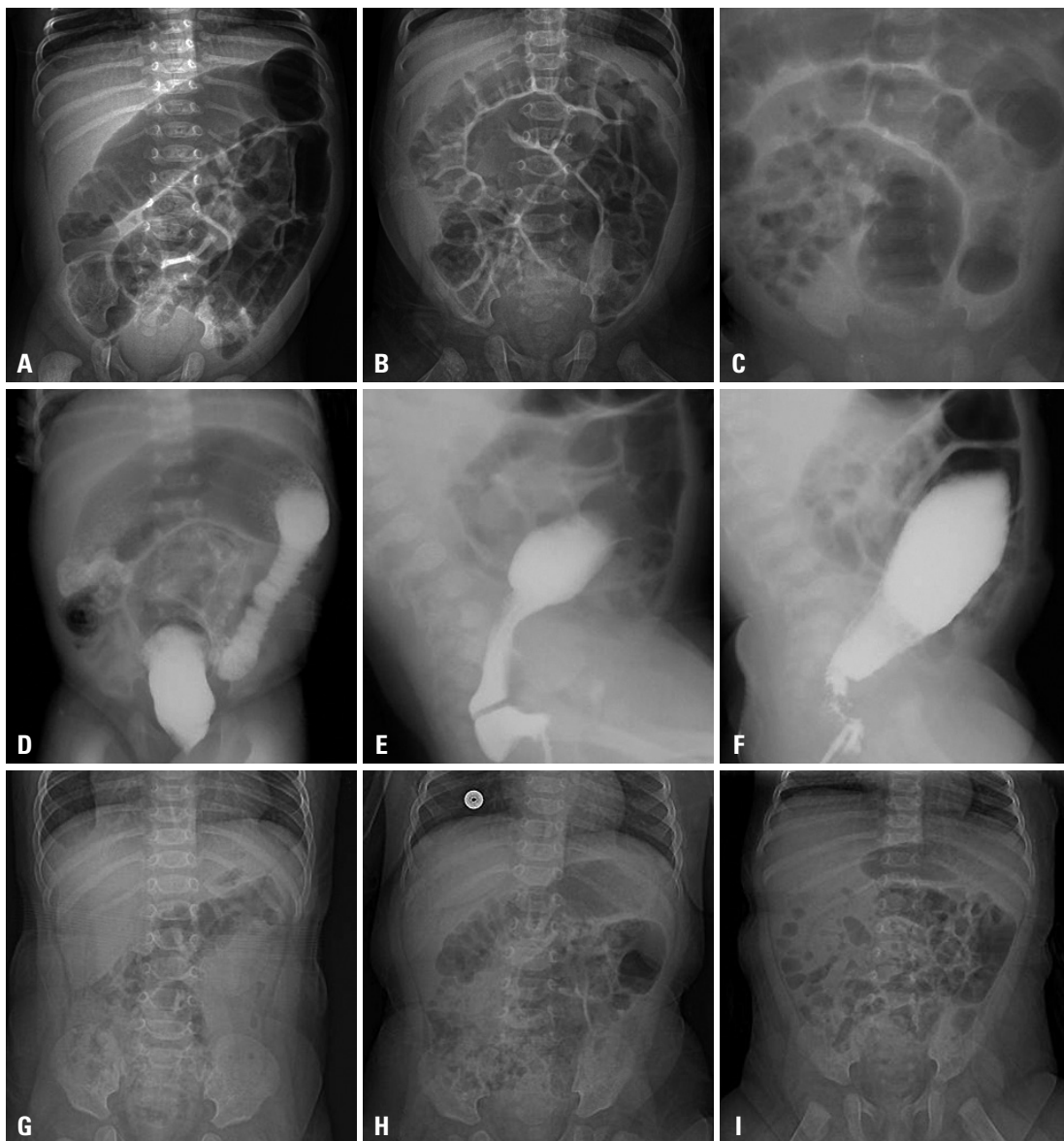


Fig. 1. Plain radiograph findings similar to Hirschsprung's disease appeared (A, B and C). Barium studies (D, E and F) showed transition zones. After conservative treatment, symptoms disappeared, and the radiographs normalized (G, H and I). Figures (A, D, F), (B, E, H) and (C, F, I) are taken from the same patients, respectively.

initial symptoms in order of frequency were abdominal distension, emesis, explosive defecation, and constipation. Unfortunately, however, these symptoms alone are not distinguishable from those of Hirschsprung's disease. In addition, plain radiographs of the abdomen are also very similar to Hirschsprung's disease. One-third of our patients showed the typical transition zone in barium studies. However, the presence of ganglion cells in rectal biopsies and the presence of the rectoanal inhibitory reflex in anorectal manometry were excellent discriminators in favor of BTNIN.

BTNIN responds well to conservative treatment and demonstrates an excellent prognosis. The average duration of treatment was only 4.4 months in our study and has been reported to be 5 months in a previous study.³ Conservative treatment should be periodic or intermittent glycerin enema. Prokinetic medication has not shown any remarkable effect.³

The etiology of BTNIN has not been fully understood, but it could not be classified as the variants of Hirschsprung's disease or meconium related disorders. BTNIN occurs in the neonatal period with no association with birth weight or complications during pregnancy.³ Our results identified only one patient born at less than 35 weeks gestational age with a birth weight of 2.5 kg. Most patients with BTNIN showed normal appearance of ganglion cells without hyper- or hypoganglionosis. In addition, the clinical outcome of BTNIN in this study was more favorable than the other variants of Hirschsprung's disease.

The one possible cause of BTNIN was allergy-related disorder.^{4,5} Kubota, et al.⁴ suggest that cow's milk allergy is the main cause of BTNIN. In their study, patients who were diagnosed with BTNIN showed a positive drug-induced lymphocyte stimulation test for cow's milk. The majority of these patients had symptom relief after conversion to formula. Allergic proctitis, a specific form of cow's milk allergy, could induce symptoms mimicking Hirschsprung's disease.⁵ Eosinophilic infiltration and inflammatory cell infiltration in the lamina propria of rectum have been identified, and rectal suction biopsy is very useful to differentiate this from other disorders.

However, our results did not support the aforementioned etiology. Although we had the limitation that allergy test for cow's milk was not performed, most patients in our study were breast-fed and improved without a formula change. Although cow's milk allergy could happen in breast-fed infants, the proportion of breast feeding in our study was too high to consider cow's milk allergy as the sole etiology of BTNIN.¹²

Allergic proctitis could not be considered as the possible cause of BTNIN because no patients showed eosinophilic infiltration in the rectal biopsies in our study. Considering that BTNIN occurs in the neonatal period and disappears with age, immaturity of the ganglion cells is suspected as the likely pathophysiology.¹³

In this retrospective study, we could not perform advanced histopathologic evaluations. Furthermore, the number of patients was not sufficient to generate any statistical results. These are also the limitations of this study. Nevertheless, we think that our results showed important clinical characteristics and management of BTNIN.

In summary, our data suggest that BTNIN has symptoms very similar to but should be differentiated from Hirschsprung's disease. Rectal biopsy and anorectal manometry were useful diagnostic tools. Patients with BTNIN had excellent outcomes with conservative treatment, and symptoms disappeared by 5 months of age. The pathophysiology of this disease is not fully understood, and further studies are required.

REFERENCES

1. Haricharan RN, Georgeson KE. Hirschsprung disease. *Semin Pediatr Surg* 2008;17:266-75.
2. Puri P, Gosemann JH. Variants of Hirschsprung disease. *Semin Pediatr Surg* 2012;21:310-8.
3. Yamauchi K, Kubota A, Usui N, Yonekura T, Kosumi T, Nogami T, et al. Benign transient non-organic ileus of neonates. *Eur J Pediatr Surg* 2002;12:168-74.
4. Kubota A, Kawahara H, Okuyama H, Shimizu Y, Nakacho M, Ida S, et al. Cow's milk protein allergy presenting with Hirschsprung's disease-mimicking symptoms. *J Pediatr Surg* 2006;41:2056-8.
5. Lee JH, Choe YH, Lee SK, Seo JM, Kim JH, Suh YL. Allergic proctitis and abdominal distention mimicking Hirschsprung's disease in infants. *Acta Paediatr* 2007;96:1784-9.
6. Dasgupta R, Langer JC. Transanal pull-through for Hirschsprung disease. *Semin Pediatr Surg* 2005;14:64-71.
7. Kim HY, Oh JT. Stabilization period after 1-stage transanal endorectal pull-through operation for Hirschsprung disease. *J Pediatr Surg* 2009;44:1799-804.
8. Langer JC, Durrant AC, de la Torre L, Teitelbaum DH, Minkes RK, Caty MG, et al. One-stage transanal Soave pullthrough for Hirschsprung disease: a multicenter experience with 141 children. *Ann Surg* 2003;238:569-83.
9. de Lorijn F, Kremer LC, Reitsma JB, Benninga MA. Diagnostic tests in Hirschsprung disease: a systematic review. *J Pediatr Gastroenterol Nutr* 2006;42:496-505.
10. Jamieson DH, Dundas SE, Belushi SA, Cooper M, Blair GK. Does the transition zone reliably delineate aganglionic bowel in Hirschsprung's disease? *Pediatr Radiol* 2004;34:811-5.
11. Lewis NA, Levitt MA, Zallen GS, Zafar MS, Iacono KL, Rossman

- JE, et al. Diagnosing Hirschsprung's disease: increasing the odds of a positive rectal biopsy result. *J Pediatr Surg* 2003;38:412-6.
12. Järvinen KM, Suomalainen H. Development of cow's milk allergy in breast-fed infants. *Clin Exp Allergy* 2001;31:978-87.
13. Burki T, Kiho L, Scheimberg I, Phelps S, Misra D, Ward H, et al. Neonatal functional intestinal obstruction and the presence of severely immature ganglion cells on rectal biopsy: 6 year experience. *Pediatr Surg Int* 2011;27:487-90.