



Spinal dysraphism with anorectal malformation: lumbosacral magnetic resonance imaging evaluation of 120 patients

Seong Min Kim^a, Hye Kyung Chang^b, Mi Jung Lee^c, Kyu Won Shim^d, Jung Tak Oh^b,
Dong Seok Kim^d, Myung Joon Kim^c, Seok Joo Han^{b,*}

^aDepartment of Surgery, Yongin Severance Hospital, Yonsei University College of Medicine, Yongin, South Korea

^bDepartment of Pediatric Surgery, Severance Children's Hospital, Yonsei University College of Medicine, Seoul 120-752, South Korea

^cDepartment of Pediatric Diagnostic Radiology, Severance Children's Hospital, Yonsei University College of Medicine, Seoul 120-752, South Korea

^dDepartment of Pediatric Neurosurgery, Severance Children's Hospital, Yonsei University College of Medicine, Seoul 120-752, South Korea

Received 29 June 2009; revised 5 October 2009; accepted 30 October 2009

Key words:

Spinal dysraphism;
Tethered spinal cord;
Anorectal malformation;
Sacral ratio;
Magnetic resonance
imaging

Abstract

Purpose: We evaluated the prevalence of spinal dysraphism (SD) in patients with anorectal malformation (ARM) by magnetic resonance imaging (MRI).

Methods: From January 2002 to March 2009, 120 patients with ARM who underwent anorectal reconstruction were evaluated for SD with sacral plain film, spinal ultrasonography (US), and lumbosacral MRI. We adopted Krickbeck international classification of ARM.

Results: Spinal dysraphism was present in 41 (34.2%) of 120 patients with ARM, 3 (13.0%) of 23 patients with perineal fistula, 7 (29.2%) of 24 patients with vestibular fistula, 4 (36.4%) of 11 patients with rectovesical fistula, 18 (40.9%) of 44 patients with rectourethral fistula, and 9 (60.0%) of 15 patients with cloacal anomaly ($P = .04$). Among 41 patients having SD detected by MR, 26 patients (26/41; 63.4%) underwent detethering surgery for tethered spinal cord. The mean sacral ratio (SR) in patients who underwent detethering surgery (0.54 ± 0.19) was significantly lower than in patients who did not undergo detethering surgery (0.69 ± 0.13 ; $P < .001$). The optimal cutoff for the SR value predicting SD requiring detethering surgery was 0.605, with sensitivity of 65.4% and specificity of 77.7%.

Conclusions: Spinal dysraphism is common in patients with ARM, and its prevalence is higher in patients with complex ARM. Spinal anomalies can occur even with benign types of ARM and, therefore, that all patients should be screened. Magnetic resonance imaging is useful in detecting occult SD that may be missed by conventional radiologic evaluation, physical examination, and spinal US. We further recommend a lumbosacral MRI examination in those whose SR is lower than 0.6.

© 2010 Elsevier Inc. All rights reserved.

* Corresponding author. Tel.: +82 2 2228 2130; fax: +82 2 313 8289.

E-mail address: sjhan@yuhs.ac (S.J. Han).

The association of anorectal malformations (ARMs) and spinal cord anomalies has been well documented. Recent advances in radiology make it possible for physicians to diagnose spinal dysraphism in patients with ARM more frequently than in the past. Spinal ultrasonography (US) has been considered as an effective screening test. However, magnetic resonance imaging (MRI) is probably the diagnostic modality of choice for evaluating the spine because MRI has excellent resolution of soft tissue of the neuromuscular and skeletal system [1,2]. For example, congenital lesions of the sacrum, including sacral agenesis and meningocele, are optimally imaged with MRI [3]. The results of many studies have described the prevalence of spinal dysraphism in patients with ARM; however, whether the prevalence varies by type of ARM has not been well described, which was noted in only one large retrospective study that has dealt with this topic [4]. Therefore, our objective was to describe the prevalence of spinal dysraphism and tethered spinal cord as diagnosed by lumbosacral MRI in patients with ARM and to determine the prevalence by type of ARM.

1. Material and methods

From January 2002 to March 2009, 142 patients underwent corrective surgery for ARM. As a part of preoperative evaluation, we prospectively performed lumbosacral MRI, regardless of the type of ARM, in all patients who had already been evaluated with plain radiography of the sacrum with or without spinal US. In evaluating the results of plain films of the sacrum, a pediatric radiologist not involved in patient care or follow-up evaluated morphologic abnormalities of the bony sacrum such as dysmorphism, fused vertebra, and hemisacrum. For the purposes of this study, we measured the sacral ratio (SR) in the anteroposterior and lateral sacral films as previously described [5]. Spinal US was performed whenever possible for evaluation of the spinal cord and abnormal mass lesions in the lumbosacral area. The MRI protocol included whole spine sagittal T2-weighted images; lumbar spine axial and sagittal T1-weighted and T2-weighted images; axial and sagittal gadolinium-enhanced T1-weighted images if necessary; and pelvic axial, sagittal, and coronal T2-weighted images when investigation of the pelvic musculature was necessary. In addition, for those who had not been evaluated by MRI previously, we invited the patients to undergo MRI of the lumbosacral area. The pre-MRI sedation protocol consisted of oral chloral hydrate at 100 mg/kg (maximum dose, 2.5 g) given for sedation before MRI, then the patients were transferred to MRI suite with intravenous sedative kit (midazolam and flumazenil). *Spinal dysraphism* was defined as the abnormalities with imperfect fusion of the midline neural and bony structures. Spinal dysraphism in this study included spina bifida aperta, spina bifida cystica, and spina bifida occulta. *Spina bifida aperta* was defined as herniation

of meninges through the defect of the posterior arch characterized by a non-skin-covered back mass such as meningo(myelo)cele. *Spina bifida cystica* was defined as herniation of meninges through the defect of the posterior arch characterized by a skin-covered back mass such as lipomeningomyelocele. *Spina bifida occulta* (occult spinal dysraphism) was defined as other form of spinal dysraphism without back mass (herniation of meninges) such as low-lying conus, tethered spinal cord, spinal lipoma, and anterior sacral meningocele [6]. Neurosurgical operation was recommended for patients with a radiographically demonstrated lipomatous lesion in the filum within the first 6 months of life or, in older children, as soon as the lesion was discovered. Even in those cases, our pediatric neurosurgeons carefully evaluated the presence of symptoms and the size of lipoma before they decide to perform a detethering operation. We did not perform a detethering operation for those who have small, tiny lipomas or asymptomatic low conus medullaris, and who do not want surgery even in those cases with a definite surgical indication. Nonoperative follow-up with biannual examinations was recommended for patients with nonprogressive symptoms or only asymptomatic low conus medullaris. The most notable symptoms in patients with ARM in this study were orthopedic and urologic symptoms. Orthopedic symptoms included progressive scoliosis and cavovarus deformity of the foot with or without leg length discrepancy. Urologic impairment was based on the result of the urodynamic study (neurogenic bladder, vesico-ureteral [VU] reflux). Neurologic symptoms included low extremity muscle weakness and patchy sensory loss. Type of ARM was categorized by the Krickenbeck international classification [7]. We analyzed patient characteristics (age, sex, type of anorectal defect) and prevalence of spinal dysraphism and tethered spinal cord and compared the results of lumbosacral MRI and conventional methods of evaluation such as sacral plain films and spinal US. All patients or their parents (or legal guardians) provided written informed consent for lumbosacral MRI examination of the study. The study was approved by the Yonsei University Graduate School of Medicine Ethics Review Board (Seoul, Korea).

2. Results

During the study period, 120 patients completed lumbosacral MRI evaluation and were enrolled in this study. The remaining 22 patients were not included in this study because we could not obtain consent for MR examination from parents or their guardians during follow-up. There were 72 males (60.0%) and 48 females (40.0%), with a male-to-female ratio of 1.5:1. Mean \pm SD age at anorectal reconstruction was 5.9 ± 10.9 months. The type of ARM included rectourethral fistula in 44 patients (36.7%), vestibular fistula in 24 patients (20.0%), perineal fistula in 23 patients (19.2%), cloacal anomaly in 15 patients (12.5%),

rectovesical fistula in 11 patients (9.2%), and rare or regional variants in 3 patients (2.5%). The mean age at MR evaluation in this study was 3.5 months (range, 1 day to 71.7 months). The results of lumbosacral MRI revealed spinal dysraphism in 41 (34.2%) of 120 patients, including none of the 3 patients (0.0%) with rare or regional variants; 3 (13.0%) of 23 patients with perineal fistula; 7 (29.2%) of 24 patients with vestibular fistula; 4 (36.4%) of 11 patients with rectovesical fistula; 18 (40.9%) of 44 patients with rectourethral fistula; and 9 (60.0%) of 15 patients with cloacal anomaly. Patients with more complex ARM were more likely to have spinal dysraphism ($P = .04$; linear-by-linear association, $P = .001$; Fig. 1A). Among the 120 patients who underwent MRI, 26 patients (21.7%) underwent detethering surgery for the diagnosis of clinically significant tethered spinal cord, including none of the 3 patients (0.0%) with rare or regional variants, in 2 (8.7%) of 23 patients with perineal fistula, 3 (12.5%) of 24 patients with vestibular fistula, 11 (25.0%) of 44 patients with rectourethral fistula, 3 (27.3%) of 11 patients with rectovesical fistula, and 7 (46.7%) of 15 patients with cloacal anomaly. The proportion of patients undergoing detethering surgery was higher in patients with complex types of ARMs, but this did not reach statistical significance ($P = .07$; linear-by-linear association, $P = .001$; Fig. 1B). Low conus medullaris was found in 25 (20.8%) of 120 patients, fatty filum or lipomatous mass lesion in the caudal spine in 24 patients (20.0%), pure dysplastic bony sacrum in 24 patients (20.0%), hydrosyringomyelia in 13 patients (10.8%), dermal

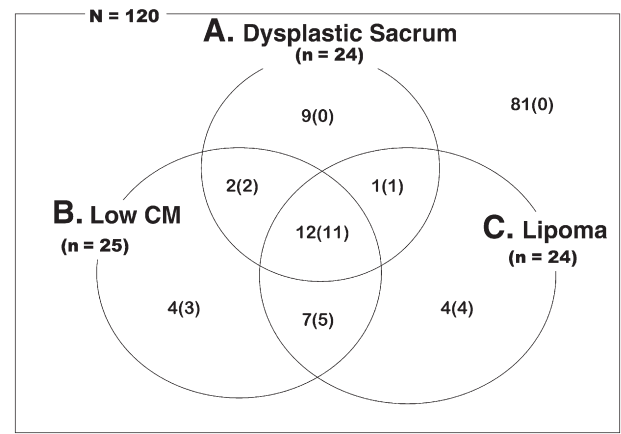
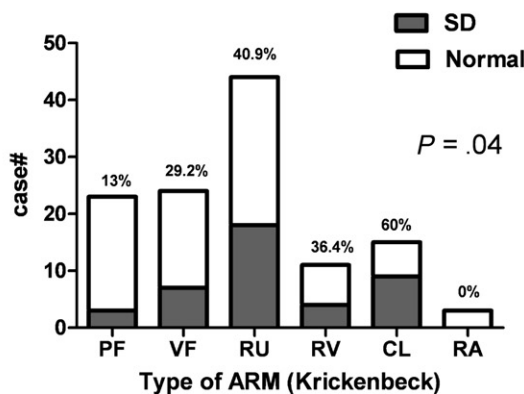


Fig. 2 Diagram of patients with major spinal dysraphism by MRI. Of 120 patients with ARMs who underwent MRI, dysplastic bony sacrum was found in 24 patients (20.0%), low conus medullaris in 25 patients (20.8%), and lipoma (fatty filum or lipomatous mass lesion) in 24 patients (20.0%). Four patients with spinal dysraphism detected by MRI are being followed up by serial MRI without detethering surgery. Numbers in parentheses indicate patients who underwent detethering surgery. CM indicates conus medullaris.

sinus tract in 3 patients (2.5%), and meningo(myelo)cele in 2 patients (1.7%) (Fig. 2). Mean \pm SD of SR in the 120 patients was 0.65 ± 0.15 . The sacral ratio was not significantly different according to the type of anorectal defect ($P = .27$; Fig. 3A). Mean SR measured was 0.76 ± 0.01 in rare or

A
Spinal Dysraphism (SD) on MRI according to the Krickenbeck international classification

34.2% of the patients (41/120)



B
% Detethering surgery according to the Krickenbeck international classification

21.7% of the patients (26/120)

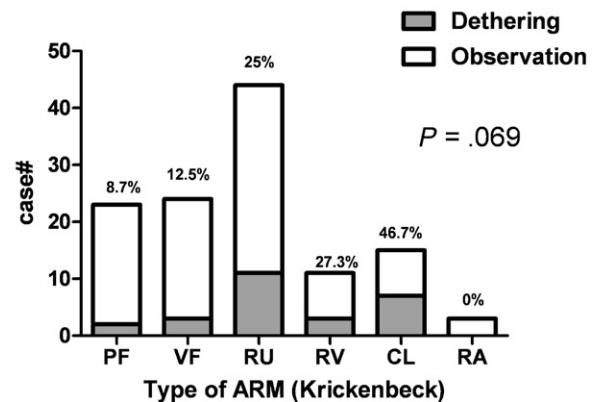


Fig. 1 Spinal dysraphism and detethering surgery according to the Krickenbeck international classification. (A) The results of lumbosacral MRI revealed spinal dysraphism in 34.2% of the patients (41/120), including in 13.0% (3/23) of patients with perineal fistula, 29.2% (7/24) with vestibular fistula, 40.9% (18/44) with rectourethral fistula, 36.4% (4/11) with rectovesical fistula, 60.0% (9/15) with cloacal anomaly, and none of 3 patients with rare or regional variants ($P = .04$). (B) Among the 120 patients undergoing MRI, 26 (21.7%) patients underwent detethering surgery for the diagnosis of clinically significant tethered spinal cord. There was a trend toward an increased proportion of patients requiring detethering surgery with complex ARMs, but this did not reach statistical significance ($P = .07$). All patients with spinal dysraphism based on the results of MRI, who did not undergo detethering surgery, are being followed up by biannual physical examinations and lumbosacral MRI. CL indicates cloacal anomaly; PF, perineal fistula; RA, rare or regional variant; RU, rectourethral fistula; RV, rectovesical fistula; SD, spinal dysraphism; VF, vestibular fistula.

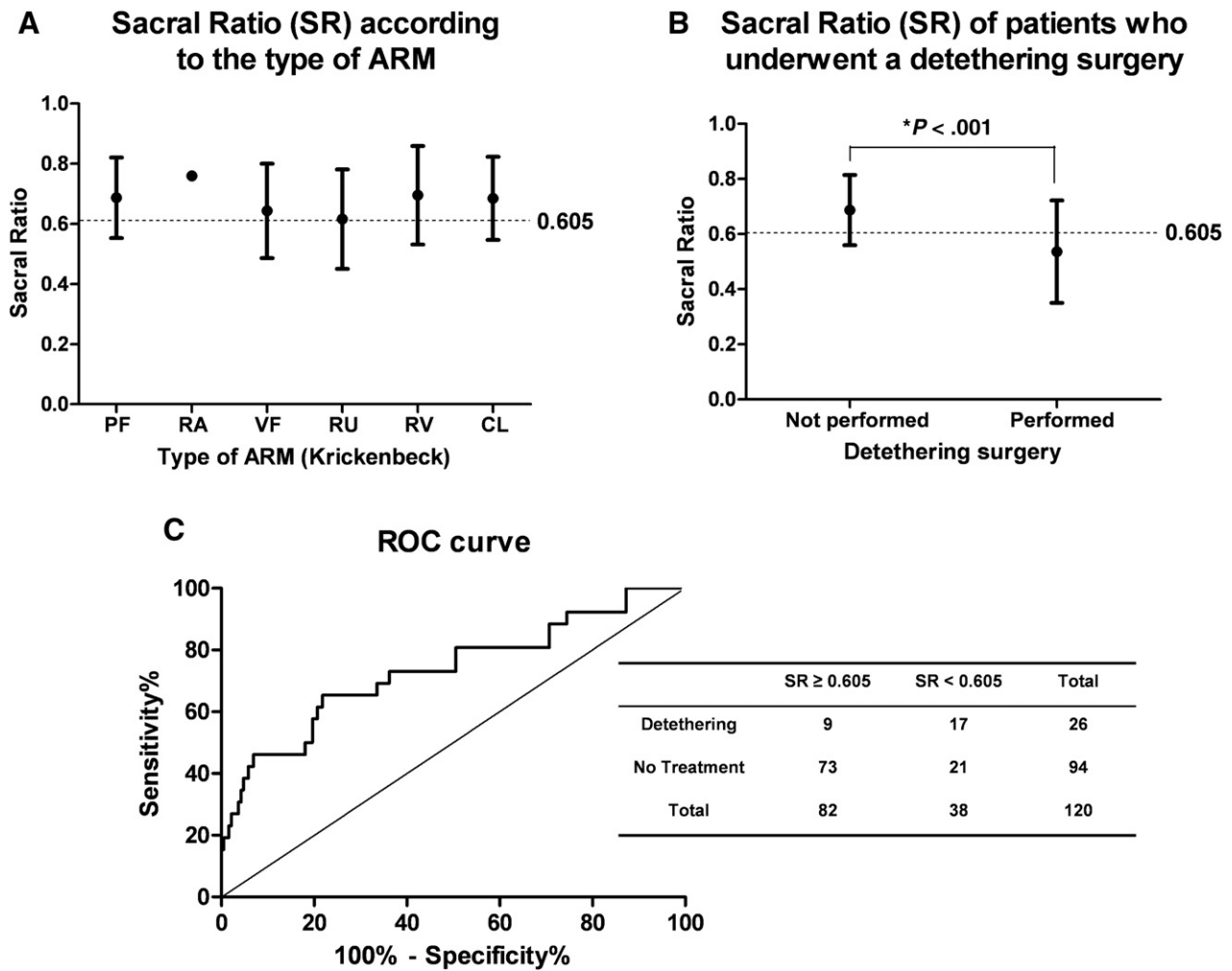


Fig. 3 Sacral ratio in the diagnosis and treatment of ARM. (A) The mean SR did not differ by type of ARM. The dotted line for SR of 0.605 represents the cutoff selected from the receiver operating characteristic curve in C. (B) The mean SR in patients who underwent detethering surgery was significantly lower than in patients who did not undergo detethering surgery. The dotted line for SR of 0.605 represents the cutoff selected from the receiver operating characteristic curve in C. (C) Optimal cutoff SR value from the receiver operating characteristic curve associated with detethering surgery was 0.605 (area under the receiver operating characteristic curve, 0.73 with 95% confidence interval, 0.61-0.85; $P < .001$) with sensitivity of 65.4% and specificity of 77.7%. CL indicates cloacal anomaly; PF, perineal fistula; RA, rare or regional variant; ROC, receiver operating characteristic; RU, rectourethral fistula; RV, rectovesical fistula; VF, vestibular fistula.

regional variants, 0.70 ± 0.16 in rectovesical fistula, 0.69 ± 0.13 in patients with perineal fistula, 0.68 ± 0.14 in cloacal anomaly, 0.64 ± 0.16 in vestibular fistula, and 0.62 ± 0.17 in rectourethral fistula. However, mean SR in patients who underwent detethering surgery (0.54 ± 0.19) was significantly lower than in patients who did not undergo detethering surgery (0.69 ± 0.13 ; $P < .001$; Fig. 3B). The optimal cutoff for the SR value from the receiver operating characteristic curve predicting spinal dysraphism requiring detethering surgery was 0.605, with sensitivity of 65.4% and specificity of 77.7% (Fig. 3C). Area under the receiver operating characteristic curve was 0.73 (95% confidence interval, 0.61-0.85). In 95 patients including 33 patients who underwent spinal US, spinal dysraphism could not be detected by the results of sacral plain films and spinal US, and results of MRI revealed occult spinal dysraphism in 21 (22.1%) of 95

patients. Fig. 4 depicts spinal US and MRI findings in a patient with occult spinal dysraphism.

3. Discussion

Evaluation of the sacrum in patients with ARM is important because of the well-established association between sacral hypodevelopment or dysmorphism and poor functional outcome after anorectal reconstruction [5]. In addition to the sacral bony abnormalities, evaluation of spinal dysraphism should include abnormalities of the spinal cord itself because so-called spinal cord tethering is associated with various orthopedic [8-10], urologic [8,11-13], and gastrointestinal problems [14,15]. In the present study, the

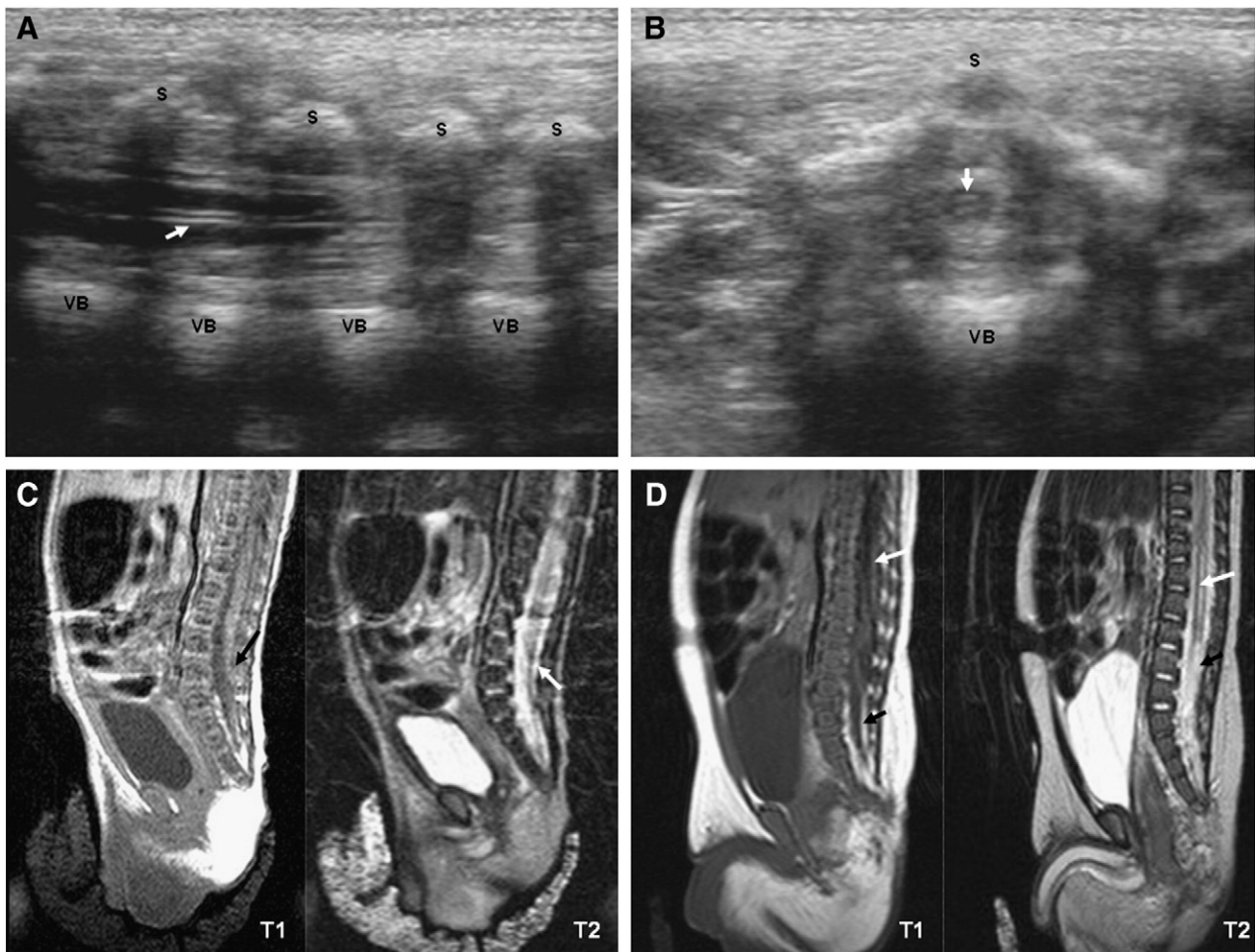


Fig. 4 Representative US and MRI findings of the lumbosacrum in occult spinal dysraphism in a patient with an ARM (rectobulbourethral fistula). (A and B) Longitudinal section (A) and transverse section (B) from spinal US on postnatal day 4 showed no remarkable finding in the lower vertebral bodies (VB) and spinal cord. Transient dilation of the central canal, a normal variant in a newborn, was noted (white arrows). Dorsal acoustic shadows caused by the echogenic spinous processes (S) were noted. (C) Lumbosacral MRI on postnatal day 5 showed low-lying conus medullaris (L4-L5) (white arrow) with thickened filum terminale combined with fibrolipoma (black arrow). (D) Follow-up MRI on postnatal day 95 showed a large syrinx (white arrows), producing low signal intensity in the dilated spinal cord on the sagittal T1-weighted image. The thickened filum terminale was still noted at a low lumbar level intertwined with the fibrolipoma (black arrows). There was no evidence of sacrococcygeal dysplasia. The patient underwent total laminectomy (L4, L5) and removal of intradural lipoma for detethering of the spinal cord. T1 indicates T1-weighted image; T2, T2-weighted image.

prevalence of spinal dysraphism in patients with ARMs was 34.2%, and clinically significant spinal cord tethering requiring detethering surgery was 21.7%, consistent with previous studies [16-25]. More complex types of anorectal defects were associated with a higher prevalence of spinal dysraphism. Our data have more statistical power than previous series [18,19,26], with the largest number of patients with ARM studied, all of whom underwent MRI. It is likely, therefore, that the results of our study estimate the true prevalence of spinal dysraphism in patients with ARM and confirm that prevalence of tethered spinal cord increases as the severity of the anorectal defect increases. The results of several studies showed even higher prevalence of tethered spinal cord among patients with low type of ARM when MRI was routinely used to evaluate the spinal cord [2,25,27], compared with the results of the present study (8.7% of

patients with perineal fistula). One possible explanation for this difference may be different practice patterns for the diagnosis of spinal cord tethering requiring detethering surgery. Tethering of the spinal cord should be assessed with care to determine whether it is true cord tethering or an incidental finding of low conus medullaris. No relationship was observed between the type of ARM and the coexistence of anomalies in bony sacrum expressed either qualitatively (sacral morphology) or quantitatively (SR). Sacral abnormalities frequently did not predict the presence of abnormal intraspinal lesions such as fatty filum, spinal cord tethering, and clinically important syrinx (Fig. 2). Measurements of sacral morphology in the newborn period may be inaccurate because of incomplete ossification. The results of lumbosacral MRI usually shows the cause of the tethering and provides sufficient anatomical details of the lesion. Occult

spinal dysraphism was observed in 22.1% of patients who did not show spinal dysraphism on sacral plain film and spinal US, which is consistent with the results of the study of Long et al [28] who found potentially important spinal dysraphic anomalies in 21% of patients with an apparently normal spine. These results emphasize the need to rule out dysraphic anomalies even in patients with no detectable vertebral anomalies. Taken together, MRI is the ideal method for evaluating the spinal cord in patients with ARMs. An additional benefit of MRI is the ability to diagnose remnant utricular structures and genitourinary malformations such as megacystis, ureteral anomalies, and horseshoe kidney. It also has the ability to illustrate anatomical details of the levator muscles, all of which are very important in the perioperative management of patients with ARM. Measurement of the SR was suggested by Peña [5] for establishing functional prognosis with reasonable accuracy in patients with ARM. Its value in normal children was 0.74. Warne et al [29] found high variability of SR values among similar patients, suggesting that a single result has limited value in discriminating a normal from an abnormal sacrum. Furthermore, in another study, SR was not predictive of incontinence after anorectal reconstruction [30]. Nevertheless, the results of the present study suggest that SR is useful for predicting the presence of tethered spinal cord in patients with ARM, which accords with the results of the study by Peña [4]. The sacral ratio in patients who underwent detethering surgery was significantly lower than in patients who did not undergo detethering surgery, and we were able to determine an optimal cutoff for the SR from the receiver operating characteristic curve with moderately high levels of sensitivity and specificity. Thus, we believe that SR is valuable in detecting clinically important spinal cord tethering that requires detethering surgery. Considering cost-effectiveness, we recommend MRI for patients with both sacral hypodevelopment and SR below 0.6. The results of spinal US may be inaccurate. As a major referral center for the treatment of ARM, many children are referred to us at several months of age after the sonographic window of the spine has closed. This may be especially true for toddlers with previously undiagnosed perineal fistula (so-called anterior anus). As a matter of fact, for considerable number of patients with ARM including the patients who had been referred to us after the age when the sacral window for spinal US was closed, the accuracy of the spinal US was disappointing, and often, the examination itself was impossible. Therefore, we changed our policy not to perform spinal US for all patient with ARM from the latter half of the period. A total of 33 of 120 patients underwent spinal US at the period of first half of study (median age, 51 postnatal days; ranged from 0 to 230 postnatal days). The data in Table 1 were based on our own observations about the correlation between spinal US and MRI in 33 patients. In our experience, screening US was acceptable because of high specificity and positive predictive value. However, sensitivity and negative predictive value were rather low. The

Table 1 An analysis of US findings according to age of the patients, below and above 3 months

	MRI		Total
	Normal	Spinal dysraphism	
<i>Age ≤ 90 d</i>			
US			
Normal	13	10	23
Spinal dysraphism	0	2	2
Total	13	12	25
<i>Age > 90 d</i>			
US			
Normal	5	1	6
Spinal dysraphism	0	2	2
Total	5	3	8

problem in our study was that US had a relative higher false-negative rate when compared to the previous reports. Ultrasonography is safe, noninvasive, inexpensive, does not require sedation, and can be performed portably [31]. Furthermore, the correlation between spinal US and MRI has been excellent, and spinal US is currently accepted as an initial screening tool for detecting spinal dysraphism in patients with ARM [1,32-34]. Therefore, it is not to be denied that US is an ideal screening tool for evaluating the spine in patients with ARM. However, our data showed more discordance rate between US and MRI than previous results. We suppose that false-negative rate of US was high because (i) US could not accurately detect small lipoma or fatty filum in the spinal canal. In this study, MRI was used as a standard study to detect spinal dysraphism, and it is possible that this tool detects minimal types of spinal dysraphism that might not be evident on US. The significance of minimal types of spinal dysraphism detected by MRI remains to be proved in the future because it is obviously abnormal finding and has potentials to grow over time. (ii) Transitional vertebrae were the potential for confusion over the labeling or assignment of vertebral levels during evaluation of the tethered spinal cord in US. (iii) The experience of sonographer and the time interval between US and MRI might affect the outcomes. Borg et al [35] performed screening spinal US in 24 patients with "high" type ARM found that spinal US finding was equivocal in about 21% (5/24) of the patients. Furthermore, false-negative result of the spinal US was found in 1 of the 14 patients who underwent MR imaging of the spine. Davidoff et al [19] performed screening MRI in 44 patients (including 21 former patients who were asymptomatic) and remarked that at least 9% (4/44) of the patients had significant occult spinal dysraphism that underwent neurosurgery. All of this amounts to saying that the difference of data seems to be a matter of method or technique for examination. The view is widely held that MRI is the gold standard for evaluation of spine and spinal cord [1,2,36,37]. However, US is still accepted as an excellent screening tool in the initial

evaluation because US has many advantages as described above. The results of US in our study are somewhat different from those of previous studies, though it remains to be proved in the future. The benefit of detethering surgery is also controversial. The results of many studies suggest that neurosurgical release of tethered spinal cord has a beneficial effect on urinary [9,12,38,39], orthopedic [9], and bowel function [39]. Evidence of such a beneficial effect was not clearly observed in bowel function in the present study. For example, we observed that the patients with rectovesical fistula having spinal dysraphisms detected by MRI universally showed poor outcomes whether detethering surgery was done. In those patients, a bowel management program including antegrade continence enema procedure was necessary. One possible explanation is because an animal experiment showing that neurologic pathways controlling urinary and fecal continence may be established during early embryogenesis [40]. Another important aspect of spinal cord tethering is that it is not a static condition, with several reports of progressive neurologic deficit in children with tethered cord syndrome [38,41]. The present study includes one patient who showed newly developed tethered cord syndrome based on the results of serial MRI, which is similar to the previous report [9]. These patients have an anatomically stable but growing lipomatous mass because of increased lipogenesis within the spinal canal during the early years of life. Our study has several limitations. The present study may be said to have skewed data because of the racial or ethnic diversity of ARM or spinal dysraphism that show different levels of occurrence. The study population was from a referral center, which tends to overestimate the prevalence of conditions compared to a true population-based study sample. As far as the functional benefit of the detethering surgery is concerned, we do not have satisfactory data yet and the follow-up after detethering surgery is still short. Although the decision for neurosurgical intervention for tethered spinal cord was based on symptoms and findings in the lumbosacral MRI, for most patients, urologic and orthopedic symptoms were not aggravated, and bowel function seemed unchanged after detethering surgery. Considering that symptoms of tethered spinal cord can be reliably evaluated after children reach school age or often become more significant after a growth spurt in previously unaffected patients, more long-term follow-up is necessary. Furthermore, as the criteria for neurosurgical intervention can be varied according to the practice patterns, the operative findings in this study cannot be used a gold standard for deciding whether patients have clinically important spinal dysraphism. In conclusion, spinal dysraphism has a high prevalence among patients with ARM, especially with complex ARM. Spinal anomalies can occur even with benign types of ARM, and therefore, all patients should be screened. Results of MRI of the lumbosacrum in our study are very useful in detecting spinal dysraphism in these patients, especially occult spinal dysraphism that may be missed by conventional radiologic evaluation, physical

examination, and spinal US. With these points in mind, we think it is reasonable to recommend patients with ARM having sacral hypodevelopment with SR value below 0.6 to undergo a MRI of the lumbosacral area to evaluate for tethered spinal cord. Although it is well known that MRI is more accurate than US in the evaluation of spinal dysraphism and US is more useful than MRI in the initial screening in patients with ARM, high false-negative rate of the spinal US in our study casts doubt on the role of spinal US to screening tool with MRI being reserved for cases where spinal US is equivocal or has revealed a definite abnormality. However, as the accuracy of our US data is currently limited because of a variety of reasons as mentioned above, it remains to be proved in the future.

References

- [1] Beek FJ, Boemers TM, Witkamp TD, et al. Spine evaluation in children with anorectal malformations. *Pediatr Radiol* 1995;25(Suppl 1): S28-32.
- [2] Mosiello G, Capitanucci ML, Gatti C, et al. How to investigate neurovesical dysfunction in children with anorectal malformations. *J Urol* 2003;170:1610-3.
- [3] Diel J, Ortiz O, Losada RA, et al. The sacrum: pathologic spectrum, multimodality imaging, and subspecialty approach. *Radiographics* 2001;21:83-104.
- [4] Levitt MA, Patel M, Rodriguez G, et al. The tethered spinal cord in patients with anorectal malformations. *J Pediatr Surg* 1997;32: 462-8.
- [5] Pena A. Anorectal malformations. *Semin Pediatr Surg* 1995;4:35-47.
- [6] Robinson AJ, Russell S, Rimmer S. The value of ultrasonic examination of the lumbar spine in infants with specific reference to cutaneous markers of occult spinal dysraphism. *Clin Radiol* 2005;60: 72-7.
- [7] Holschneider A, Hutson J, Pena A, et al. Preliminary report on the International Conference for the Development of Standards for the Treatment of Anorectal Malformations. *J Pediatr Surg* 2005;40: 1521-6.
- [8] Bowman RM, Mohan A, Ito J, et al. Tethered cord release: a long-term study in 114 patients. *J Neurosurg Pediatr* 2009;3:181-7.
- [9] Uchida K, Inoue M, Matsubara T, et al. Evaluation and treatment for spinal cord tethering in patients with anorectal malformations. *Eur J Pediatr Surg* 2007;17:408-11.
- [10] Xenos C, Sgouros S, Walsh R, et al. Spinal lipomas in children. *Pediatr Neurosurg* 2000;32:295-307.
- [11] Namima T, Uchi K, Nakagawa H, et al. Urological assessment for tethered cord syndrome of delayed onset following repair of meningomyelocele. *Nippon Hinyokika Gakkai Zasshi* 1996;87: 1158-66.
- [12] Hsieh MH, Perry V, Gupta N, et al. The effects of detethering on the urodynamics profile in children with a tethered cord. *J Neurosurg* 2006;105:391-5.
- [13] Selcuki M, Unlu A, Ugur HC, et al. Patients with urinary incontinence often benefit from surgical detethering of tight filum terminale. *Childs Nerv Syst* 2000;16:150-4 [discussion 5].
- [14] Nivelstein RA, Vos A, Valk J. MR imaging of anorectal malformations and associated anomalies. *Eur Radiol* 1998;8:573-81.
- [15] Gupta DK, Mahapatra AK. Terminal myelocystoceles: a series of 17 cases. *J Neurosurg* 2005;103:344-52.
- [16] Tuuha SE, Aziz D, Drake J, et al. Is surgery necessary for asymptomatic tethered cord in anorectal malformation patients. *J Pediatr Surg* 2004;39:773-7.

- [17] Carson JA, Barnes PD, Tunell WP, et al. Imperforate anus: the neurologic implication of sacral abnormalities. *J Pediatr Surg* 1984;19: 838-42.
- [18] Karrer FM, Flannery AM, Nelson Jr MD, et al. Anorectal malformations: evaluation of associated spinal dysraphic syndromes. *J Pediatr Surg* 1988;23:45-8.
- [19] Davidoff AM, Thompson CV, Grimm JM, et al. Occult spinal dysraphism in patients with anal agenesis. *J Pediatr Surg* 1991;26: 1001-5.
- [20] Appignani BA, Jaramillo D, Barnes PD, et al. Dysraphic myelodysplasias associated with urogenital and anorectal anomalies: prevalence and types seen with MR imaging. *AJR Am J Roentgenol* 1994;163: 1199-203.
- [21] Rivosecchi M, Lucchetti MC, Zaccara A, et al. Spinal dysraphism detected by magnetic resonance imaging in patients with anorectal anomalies: incidence and clinical significance. *J Pediatr Surg* 1995;30: 488-90.
- [22] Nieselstein RA, Vos A, Valk J, et al. Magnetic resonance imaging in children with anorectal malformations: embryologic implications. *J Pediatr Surg* 2002;37:1138-45.
- [23] Tunell WP, Austin JC, Barnes PD, et al. Neuroradiologic evaluation of sacral abnormalities in imperforate anus complex. *J Pediatr Surg* 1987; 22:58-61.
- [24] Morimoto K, Takemoto O, Wakayama A. Tethered cord associated with anorectal malformation. *Pediatr Neurosurg* 2003;38:79-82.
- [25] Golonka NR, Haga LJ, Keating RP, et al. Routine MRI evaluation of low imperforate anus reveals unexpected high incidence of tethered spinal cord. *J Pediatr Surg* 2002;37:966-9 [discussion -9].
- [26] Warf BC, Scott RM, Barnes PD, et al. Tethered spinal cord in patients with anorectal and urogenital malformations. *Pediatr Neurosurg* 1993; 19:25-30.
- [27] Heij HA, Nieselstein RA, de Zwart I, et al. Abnormal anatomy of the lumbosacral region imaged by magnetic resonance in children with anorectal malformations. *Arch Dis Child* 1996;74:441-4.
- [28] Long FR, Hunter JV, Mahboubi S, et al. Tethered cord and associated vertebral anomalies in children and infants with imperforate anus: evaluation with MR imaging and plain radiography. *Radiology* 1996; 200:377-82.
- [29] Warne SA, Godley ML, Owens CM, et al. The validity of sacral ratios to identify sacral abnormalities. *BJU Int* 2003;91:540-4.
- [30] Macedo M, Martins JL, Freitas Filho LG. Sacral ratio and fecal continence in children with anorectal malformations. *BJU Int* 2004;94: 893-4.
- [31] Babcock CJ. Ultrasound evaluation of prenatal and neonatal spina bifida. *Neurosurg Clin N Am* 1995;6:203-18.
- [32] Rohrschneider WK, Forsting M, Darge K, et al. Diagnostic value of spinal US: comparative study with MR imaging in pediatric patients. *Radiology* 1996;200:383-8.
- [33] Schenk JP, Herweh C, Gunther P, et al. Imaging of congenital anomalies and variations of the caudal spine and back in neonates and small infants. *Eur J Radiol* 2006;58:3-14.
- [34] Unsinn KM, Geley T, Freund MC, et al. US of the spinal cord in newborns: spectrum of normal findings, variants, congenital anomalies, and acquired diseases. *Radiographics* 2000;20:923-38.
- [35] Borg H, Holmdahl G, Olsson I, et al. Impact of spinal cord malformation on bladder function in children with anorectal malformations. *J Pediatr Surg* 2009;44:1778-85.
- [36] Rossi A, Cama A, Piatelli G, et al. Spinal dysraphism: MR imaging rationale. *J Neuroradiol* 2004;31:3-24.
- [37] Altman NR, Altman DH. MR imaging of spinal dysraphism. *AJNR Am J Neuroradiol* 1987;8:533-8.
- [38] Cornette L, Verpoorten C, Lagae L, et al. Tethered cord syndrome in occult spinal dysraphism: timing and outcome of surgical release. *Neurology* 1998;50:1761-5.
- [39] Metcalfe PD, Luerssen TG, King SJ, et al. Treatment of the occult tethered spinal cord for neuropathic bladder: results of sectioning the filum terminale. *J Urol* 2006;176:1826-9 [discussion 30].
- [40] Tsuda T, Shimotake T, Aoi S, et al. Developmental study of tethered spinal cord in murine embryos with anorectal malformations. *J Pediatr Surg* 2005;40:1927-30.
- [41] Rowe DE, Jadhav AL. Care of the adolescent with spina bifida. *Pediatr Clin North Am* 2008;55:1359-74, ix.