



A human case study demonstrating the safety and effectiveness of laparoscopic surgical glue injection hernioplasty for pediatric indirect inguinal hernia[☆]



Si Min Park^{a,b}, Young Ju Hong^{a,b}, Eun Young Chang^{a,b}, Seok Joo Han^{a,b,*}

^a Department of Pediatric Surgery, Severance Children's Hospital, Republic of Korea

^b Department of Surgery, Yonsei University College of Medicine, Seoul, Republic of Korea

ARTICLE INFO

Article history:

Received 17 July 2013

Received in revised form

22 August 2014

Accepted 25 August 2014

Key words:

Laparoscopic surgical glue injection

hernioplasty

Pediatric indirect inguinal hernia

Hernioplasty

ABSTRACT

The purpose of this pediatric case report was to provide clinical evidence supporting the safety and effectiveness of laparoscopic surgical glue injection hernioplasty (LSGIH) in humans for indirect inguinal hernia repair. We performed LSGIH on a female newborn for a right indirect inguinal hernia that was incidentally discovered during a laparoscopic right salphingo-oophorectomy for prenatal right ovarian cyst torsion. Under laparoscopic control, the internal ring was closed by injection of Histoacryl[®] into the internal opening of the patent processus vaginalis. One month later, the patient underwent another laparoscopic operation due to torsion of a newly developed contralateral ovarian cyst. During the second operation, we were able to clearly observe the previous LSGIH site. Despite partial absorption of the injected Histoacryl[®], the opening of the internal ring remained closed without any evidence of adhesions. This case supports LSGIH as a simple, safe, and useful technique for pediatric inguinal hernioplasty. However, more clinical trials should be performed to confirm the long-term reliability and safety of LSGIH in humans.

© 2014 The Authors. Published by Elsevier Inc. All rights reserved.

Prior to the advent of effective anesthesia and surgery, injection of sclerosing agents into hernia sacs was used to correct inguinal hernias. However, since the effectiveness of such injections was both uncertain and unsafe, injection hernioplasty was abandoned as an accepted medical practice [1]. With the increased use of laparoscopy in pediatric surgery, laparoscopic inguinal hernioplasty has been gaining in popularity. However, there are some limitations of laparoscopic hernioplasty that detract from its popularity, namely, correct laparoscopic placement of the suture is not so easy, requiring a considerable level of skill and a significant learning curve. To overcome these limitations, laparoscopic surgical glue injection hernioplasty (LSGIH) was evaluated in two animal models, the results of which showed that the procedure is simple, effective, and safe [2,3]. However, the effectiveness and safety of LSGIH in humans has yet been demonstrated. This case report provides clinical evidence

supporting LSGIH as a safe and effective procedure for pediatric indirect inguinal hernia repair.

This study was approved by the Institutional Review Board of the Yonsei University College of Medicine (Approval number: 4-2013-0823).

1. Case report

1.1. First laparoscopic operation for right ovary torsion

A female newborn was transferred to our tertiary children's hospital for evaluation of a prenatal intraperitoneal mass detected after normal vaginal delivery with a gestational age of 40 weeks and birth weight of 3140 g. Postnatal abdominal ultrasonography revealed the possibility of torsion of a right ovarian cyst. Emergency laparoscopic exploration with a 5 mm subumbilical camera port insertion was performed at 10 days of age. The laparoscopic view indicated a normal left ovary but torsion of a right ovarian cyst with necrosis. A right salphingo-oophorectomy was successfully performed using a conventional laparoscopic technique. Incidentally, a 7 mm PPV at the right inguinal ring was noted during the procedure (Fig. 1). After explaining to the parents the possibility of right

[☆] This is an open access article under the CC BY-NC-ND license (<http://creativecommons.org/licenses/by-nc-nd/3.0/>).

* Corresponding author. Department of Pediatric Surgery, Severance Children's Hospital, Seoul, Republic of Korea. Tel.: +82 2 2228 2130; fax: +82 2 313 8289.

E-mail address: sjhan@yuhs.ac (S.J. Han).

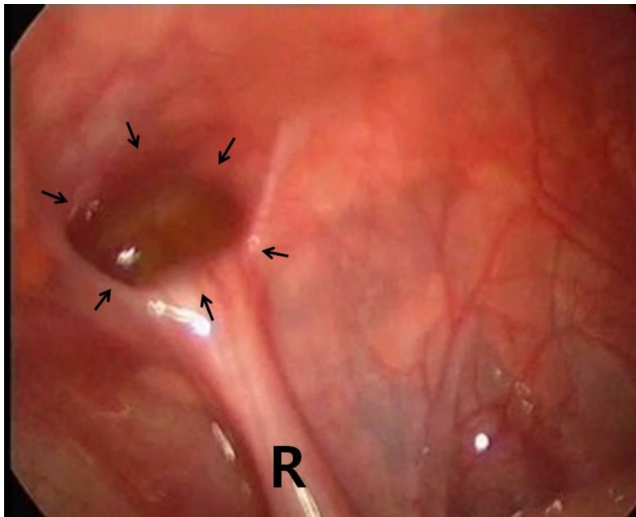


Fig. 1. Opening of the right patent processus vaginalis (arrows) was incidentally noted during laparoscopic right salpingo-oophorectomy for right ovarian cyst torsion. R: round ligament.

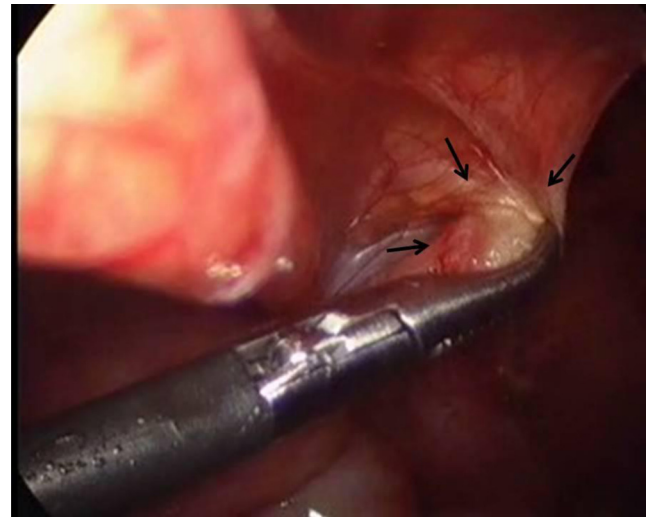


Fig. 2. The internal opening of the PPV was electrically cauterized with a 3 mm laparoscopic dissector to make a raw area of the mesothelial layer (arrows). R: round ligament.

inguinal hernia symptoms later in life, we obtained consent and performed a right LSGIH (Figs. 2, 3). The patient was discharged without any complications on postoperative day 5.

1.2. Laparoscopic surgical glue injection hernioplasty (LSGIH)

The internal opening of the PPV was electrically cauterized with a 3 mm laparoscopic dissector to generate a raw area on the mesothelial layer (Fig. 2). The opening of the PPV was then closed by covering the parietal peritoneum using a laparoscopic instrument. While maintaining the PPV in a closed position, a polyethylene tube was inserted into the peritoneal cavity, and its tip was placed into the inlet of the PPV using another 3 mm laparoscopic instrument. About 0.5–1 cc of N-butyl-2-cyanoacrylate (b-CAN, Histoacryl®; B. Braun, German) was then carefully injected through a polyethylene tube to bond the cauterized peritoneum together in order to maintain closure of the PPV after removal of the laparoscopic instrument. Sometime later (3–4 s), when the surgical glue appeared to have hardened, the laparoscopic instrument used to keep the PPV closed was carefully removed. After verifying that the PPV remained closed by the surgical glue, the operation was completed (Fig. 3).

1.3. Second laparoscopic operation for left ovary torsion

Although the patient did not exhibit any clinical evidence of right inguinal hernia when she visited an outpatient clinic, ultrasonography of the inguinal area was performed one month after the surgery to determine the effectiveness of the LSGIH procedure. There was no ultrasonographic evidence of recurrent right inguinal hernia at the LSGIH site; however, it was suspected that the left ovary had a newly developed cyst with torsion. After confirmation by CT scan, emergency laparoscopic exploration was planned.

During the second laparoscopic operation, the left fallopian tube was untwisted and the left ovary cyst was partially excised. After completing the procedures related to the left ovary, we observed the previous LSGIH site by laparoscopy. Despite partial absorption of the surgical glue, the internal opening of the PPV remained completely closed. In addition, there was no adhesion of intraperitoneal organs to the LSGIH site (Fig. 4). The patient was discharged 7 days after the second operation and was followed-up without any

evidence of recurrence of inguinal hernia 18 months after the LSGIH procedure.

2. Discussion

The laparoscopic approach for inguinal hernias in children has become an alternative option to conventional open inguinal hernioplasty [4]. Advantages of laparoscopic inguinal hernioplasty include the ability to evaluate the contralateral side; avoidance of access trauma to the spermatic cord structures, iatrogenic cryptorchidism, or testicular atrophy; shorter operative time; and less postoperative pain. However, the surgical principles behind laparoscopic hernia repair are the same as those of open repair, requiring closure of the PPV at its neck. Various techniques for laparoscopic hernia repair for children via PPV closure have been reported, and can be categorized into one of two approaches: intracorporeal [5–7] or extracorporeal ligation [5,8–14]. Both of these techniques require suturing and ligation of the internal ring

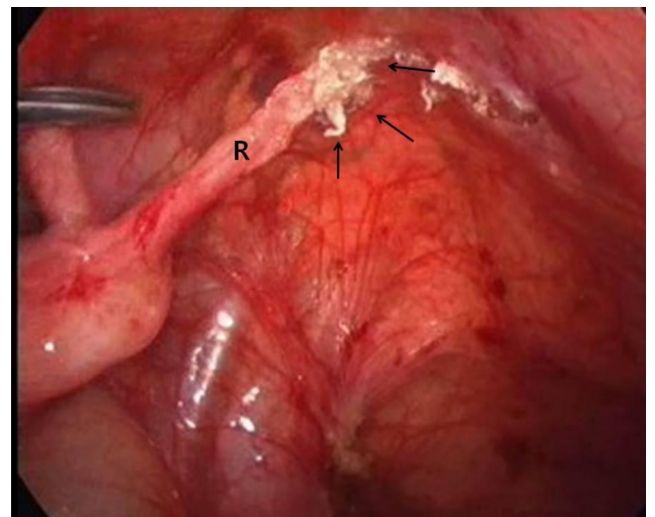


Fig. 3. Laparoscopic view during the first operation showing that the opening of the PPV remained well closed (arrows) after laparoscopic surgical glue injection hernioplasty (LSGIH). R: round ligament.

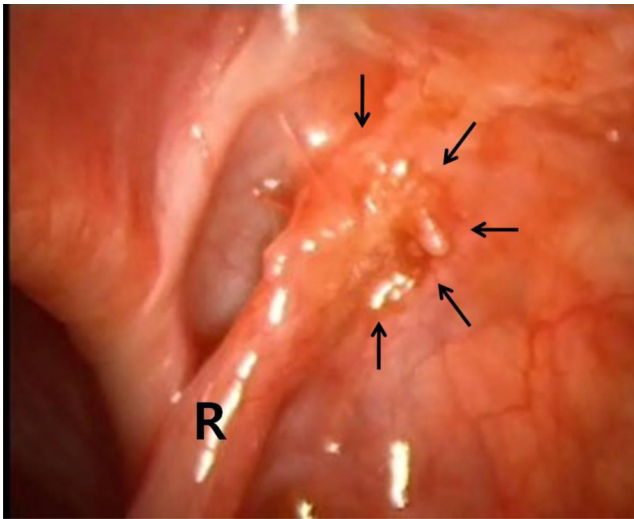


Fig. 4. Laparoscopic view during the second operation (1 month after the first operation). Despite partial absorption of the surgical glue, the previous LSGIH site remained completely closed (arrows) without any intraperitoneal organ adhesions. R: round ligament.

to close the neck of the PPV, which carries with it some risk of complication and is technically demanding compared with open methods. For these reasons, laparoscopic hernioplasty for children has failed to become popular among pediatric surgeons. In particular, intracorporeal suturing and knot tying is not easily performed and requires a significant learning curve for junior surgeons. Thus, many extracorporeal techniques for suture ligation of PPV have attempted to simplify the difficulties associated with intracorporeal methods. However, the reported extracorporeal techniques are also not ideal in that they require a small stab wound to be made over the inguinal ring for extracorporeal knot tying, as well as unnecessary incorporation of the abdominal wall structures into the loop of the tie, [8–14] which sometimes requires specially designed surgical instruments [8–11,13].

An ideal laparoscopic inguinal hernioplasty should be simple and avoid both PPV ligation and dissection of the spermatic cord. In order to satisfy these requirements, animal models have been used to determine whether surgical glue injection can be used to maintain closure of the PPV [2,3,15].

In 2004, Miyano et al. reported LSGIH with 2-octyl-cyanoacrylate (o-CNA) in an experimental animal model, and showed that LSGIH with o-CNA can close the hernia sac with only minor local tissue reaction [2]. All of the male animals in their LSGIH experiments maintained reproductive capacity without any histopathological changes to the vas deferens and spermatic vessels. Similarly, Kato et al. compared the efficacy of different kinds of surgical glues (fibrin glue, microfibrillar collagen hemostat, fibrinogen-based sealant, and o-CNA) for ligation of the PPV as an alternative method for treating inguinal hernias [15]. In their study, only o-CNA was sufficiently effective for closing inguinal hernias. A Russian group used an experimental model to show that LSGIH with a polyacrylamide hydrogel exhibits good results in terms of safety and efficacy of PPV closure [3]. The most important advantages of these experimental LSGIH studies are the absence of suture ligation and diminished need for advanced laparoscopic skills. However, despite reports that LSGIH is simple, easy to apply in animal models, and avoids the difficulty of intracorporeal suture ligation, we could not find any human case reports of LSGIH in the English-language literature.

Taking into account the positive results of previously reported animal experiments, we opted to perform LSGIH in our patient. LSGIH was used in this case instead of conventional laparoscopic

or open methods because we needed to perform a rapid and simple hernioplasty in an emergency situation, and the patient's peritoneal cavity was too small for laparoscopic suturing. Likewise, because damage to the vas deferens by surgical glue injection was not a concern, LSGIH was considered a relatively easy and safe approach.

Based on Japanese animal experiments supporting medical CNA as a reliable surgical glue for LSGIH, we chose a commercially available medical cyanoacrylate (CNA) as the surgical glue for performing the first human LSGIH procedure [2,15]. We also took into serious consideration the long-term reliability and toxicity of the surgical glue used for LSGIH.

CNAs were developed in the 1960s and 1970s. Short-chain CNAs were found to be toxic to human tissue and caused tissue necrosis. Conversely, long chain CNAs such as b-CNA and o-CNA degrade at a sufficiently slow rate to minimize histotoxic effects and have been often used in humans without adverse effects [16]. In addition, the carcinogenicity of internally placed CNA has been addressed in previous studies. While CNA was shown to have mutagenic capacity according to a standard Ames test, which is a reliable method for detecting carcinogens, the current clinical impression after significant and long-term use of CNAs is that they are generally non-carcinogenic [16]. Further, there is to date no clinical evidence that CNA is carcinogenic.

Although o-CNA (Dermabond[®], Ethicon, NJ) has been shown to be effective for LSGIH in two Japanese animal models, we chose not to use o-CNA as the surgical glue because it is currently only approved by the FDA as a skin adhesive, and not for internal use [17]. However, the FDA has approved b-CNA not only for external use as a skin adhesive (Histoacryl[®], B. Braun, German) but also for internal use as an embolic agent for cerebral arteriovenous malformations (Trufill[®], Cordis Neurovascular, FL) [17]. In addition to FDA approval, internal b-CNA has been used successfully for the treatment of bleeding varices, bronchopleural fistulas, and pancreatic fistulas without long-term adverse systemic effects [18–22]. Likewise, b-CNA was also reported to be safe and effective for patch fixation in Lichtenstein inguinal hernioplasty in a randomized controlled study [23]. We were also concerned about hernia recurrence, because b-CNA may lose its adhesiveness over time and loosen. Normally, CNA is slowly degraded over a period of 3–9 months, which provides sufficient time to maintain closure of the PPV, while providing enough tensile strength to support the wound healing process [16,23]. In our case, in order to promote wound healing, the mesothelial layer of the PPV opening was electrically cauterized, the cauterized raw surface was apposed together with the laparoscopic instrument, and liquid b-CNA was applied with caution to avoid placement of the agent in a non-intended location. Such improper placement may have caused unnecessary local inflammation and adhesions in the peritoneal cavity.

3. Conclusion

To the best of our knowledge, the case study presented here is the first to report LSGIH performed in a human patient. Our results support LSGIH as an extremely simple, rapid, and relatively safe procedure in humans. Further, LSGIH can be performed for intracorporeal suturing and knot tying in patients of any age or size by surgeons without advanced laparoscopic skills. Although the results of our case study were promising, larger long-term prospective clinical studies are needed to evaluate the long-term reliability and safety of LSGIH.

Conflict of interest statement

The authors have declared no conflicts of interest for this article.

References

- [1] Patterson DC. The injection treatment of hernia. *Yale J Biol Med* 1936;9: 159–66.
- [2] Miyano G, Yamataka A, Kato Y, Tei E, Lane GJ, Kobayashi H, et al. Laparoscopic injection of dermabond tissue adhesive for the repair of inguinal hernia: short and long-term follow-up. *J Pediatr Surg* 2004;39:1867–70.
- [3] Kozlov Y, Novogilov V, Rasputin A, Podkamenev A, Kransnov P, Weber I, et al. Laparoscopic inguinal preperitoneal injection-novel technique for inguinal hernia repair: preliminary results of experimental study. *J Laparoendosc Adv Surg Tech A* 2012;22:276–9.
- [4] Brandit ML. Pediatric hernias. *Surg Clin North Am* 2008;88:27–43.
- [5] Yip KF, Tam PKH, Li MK. Laparoscopic flip-flap hernioplasty: an innovative technique for pediatric hernia surgery. *Surg Endosc* 2004;18:1126–9.
- [6] Tsai YC, Wu CC, Yang SSD. Minilaparoscopic herniorrhaphy with hernia sac transection in children and young adults: a preliminary report. *Surg Endosc* 2007;1:1623–5.
- [7] Wheeler AA, Matz ST, Schmidt S, Pimpalwar A. Laparoscopic inguinal hernia repair in children with transperitoneal division of the hernia sac and proximal purse string closure of peritoneum: our modified new approach. *Eur J Pediatr Surg* 2011;21:381–5.
- [8] Endo M, Ukiyama E. Laparoscopic closure of patent processus vaginalis in girls with inguinal hernia using a specially devised suture needle. *Pediatr Endosc Innov Tech* 2001;5:187–91.
- [9] Spurbeck WW, Prasad R, Lobe TE. Two-year experience with minimally invasive hernioplasty in children. *Surg Endosc* 2005;19:551–3.
- [10] Harrison MR, Lee H, Albanese CT, Farmer DL. Subcutaneous endoscopically assisted ligation (SEAL) the internal ring for repair of inguinal hernia in children: a novel technique. *J Pediatr Surg* 2005;40:1177–80.
- [11] Shalabya RY, Fawy M, Solimana SM, Dorghama A. A new simplified technique for needlescopic inguinal herniorrhaphy in children. *J Pediatr Surg* 2006;41:863–7.
- [12] Ozgediz D, Roayaie K, Lee H, Nobuhara KK, Farmer DD, Bratton B, et al. Subcutaneous endoscopically assisted ligation of the internal ring for repair of inguinal hernia in children: report of a new technique and early results. *Surg Endosc* 2007;21:1327–31.
- [13] Tatekawa Y. Laparoscopic extracorporeal ligation of hernia defects using an epidural needle and preperitoneal hydrodissection. *J Endourol* 2012;26:474–7.
- [14] Lee Y, Liang J. Experience with 450 cases of micro-laparoscopic herniotomy in infants and children. *Pediatr Endosc Innov Tech* 2002;6:25–8.
- [15] Kato Y, Yamataka A, Miyano G, Tei E, Koga H, Lane GJ, et al. Tissue adhesives for repairing inguinal hernia: a preliminary study. *J Laparoendosc Adv Surg Tech A* 2005;15:424–8.
- [16] Vinters V, Galil KA, Lundie MJ, Kaufmann JCE. The histotoxicity of cyanoacrylates. *Neuroradiology* 1985;27:279–91.
- [17] <http://www.fda.gov>.
- [18] Adler M, Bourgeois N, Delhaye M, Deviere J, Gay F, Gelin M, et al. Endoscopic treatment of esophagogastric varices. *Acta Gastroenterol Belg* 1992;55:251–9.
- [19] Binmoeller KF, Soehendra N. New haemostatic techniques: histoacryl injection, banding/endoloop ligation and haemoclipping. *Baillieres Best Pract Res Clin Gastroenterol* 1999;13:85–96.
- [20] Kang EJ, Jeong SW, Jang JY, Cho JY, Lee SH, Kim HG, et al. Long-term result of endoscopic Histoacryl (N-butyl-2-cyanoacrylate) injection for treatment of gastric varices. *World J Gastroenterol* 2011;21(17):1494–500.
- [21] Sabanathan S, Richardson J. Management of postpneumonectomy bronchopleural fistulae. A review. *J Cardiovasc Surg* 1994;35:449–57.
- [22] Labori KJ, Trondsen E, Buanes T, Hauge T. Endoscopic sealing of pancreatic fistulas: four case reports and review of the literature. *Scand J Gastroenterol* 2009;44:1491–6.
- [23] Shen Y, Sun W, Chen J, Liu S, Wang M. NBCA medical adhesive (n-butyl-2-cyanoacrylate) versus suture for patch fixation in Lichtenstein inguinal herniorrhaphy: a randomized controlled trial. *Surgery* 2012;51:550–5.