



Vulvar lipomas in children: an analysis of 7 cases

Jung-Tak Oh^{a,*}, Seung Hoon Choi^a, Sung Gui Ahn^a, Myung Joon Kim^b,
Woo Ick Yang^c, Seok Joo Han^a

^aDepartment of Pediatric Surgery, Severance Children's Hospital, Yonsei University College of Medicine, Seoul 120-752, Korea

^bDepartment of Radiology, Severance Children's Hospital, Yonsei University College of Medicine, Seoul 120-752, Korea

^cDepartment of Pathology, Yonsei University College of Medicine, Seoul 120-752, Korea

Received 21 December 2008; revised 11 February 2009; accepted 20 February 2009

Key words:

Vulva;
Lipoma;
Children

Abstract

Purpose: Vulvar lipomas are a type of rare benign soft tissue tumor. This study describes 7 cases of vulvar lipomas in children, and it evaluates the clinical characteristics of this disease.

Method: We performed a retrospective review of pediatric patients at our institution who were diagnosed with vulvar lipomas between January 1998 and December 2007.

Results: Seven girls who were between the ages of 7 and 11 years were included in the study. In 6 cases, the lipomas were located on the right side of the vulva. In 4 of those 6 cases, the lipomas were found on the right anterolateral side. Five cases had gross swelling of the vulva with a poorly demarcated mass, but 2 cases had a well-demarcated or pedunculated mass. The initial tentative diagnoses made before imaging studies were right inguinal hernia in 4 cases and Bartholin's cyst in 2 cases. Preoperative imaging studies of ultrasound, computed tomography, and magnetic resonance imaging showed lipomatous characteristics of these tumors. All cases underwent surgical excision. Subsequent histopathologic examination demonstrated lipomas in each case.

Conclusions: Vulvar lipomas in children tend to occur on the right side, especially the right anterolateral side. It is necessary to differentiate this tumor from an inguinal hernia. Radiologic studies such as ultrasonography, computed tomography, and magnetic resonance imaging are useful for making the proper diagnosis. Surgical excision is the treatment of choice.

© 2009 Elsevier Inc. All rights reserved.

Lipomas are the most common soft tissue tumors and consist of mature fat cells and are mainly located in subcutaneous tissue. Lipomas are usually found in the head and neck, shoulder, back, abdomen, and proximal portions of the extremities [1]. Occurrence in the vulva region is so rare that very few cases of vulvar lipoma have been reported in children [2-6].

We present 7 cases of pediatric vulvar lipomas diagnosed at the Severance Children's Hospital, Seoul, Korea, and provide clinical characteristics of this disease with a review of the relevant literature.

1. Materials and methods

We performed a retrospective review of pediatric patients who were diagnosed with vulvar lipomas at our institution between January 1998 and December 2007. To identify

* Corresponding author. Tel.: +82 2 2228 2124; fax: +82 2 313 8289.
E-mail addresses: jtoh@yumc.yonsei.ac.kr, jtoh@yuhs.ac (J.-T. Oh).

Table 1 Summary of the cases

Case	Age (y)	Location in vulva	Appearance	Provisional diagnosis before imaging studies	Imaging studies
1	7	Right anterolateral	Swelling	Right inguinal hernia	US & MRI
2	10	Right anterolateral	Swelling	Right inguinal hernia	CT
3	8	Right anterolateral	Swelling	Right inguinal hernia	MRI
4	7	Right anterolateral	Swelling	Right inguinal hernia	CT
5	11	Right lateral	Swelling	Right vulvar mass	US
6	9	Right lateral	Cystic, well-demarcated	Right Bartholin's gland cyst	None
7	10	Left lateral	Cystic, pedunculated	Left Bartholin's gland cyst	None

US indicates ultrasound; MRI, magnetic resonance imaging; CT, computed tomography.

patients, we used the patient database from the department of pediatric surgery and the data that were obtained from the medical records department by searching the *International Statistical Classification of Diseases*, 10th Revision, codes. Seven girls were thus confirmed as having vulvar lipomas.

2. Results

Cases are summarized in [Table 1](#).

Ages at diagnosis ranged from 7 to 11 years with the median age of 9 years. All patients complained of masses in

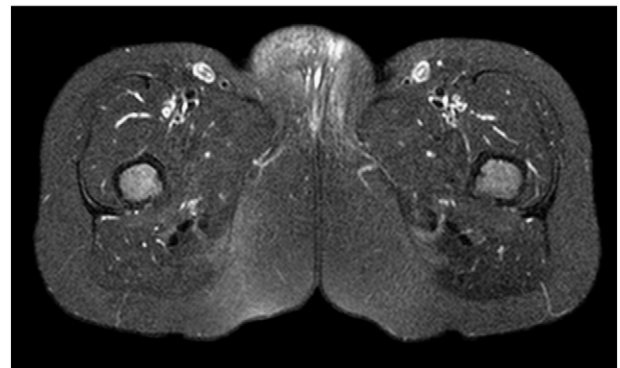


Fig. 2 Fat-suppressed T2-weighted magnetic resonance image showing a swollen labium major with irregular high-signal intensities (case 1).

the vulvar area. There was a wide range of durations of symptoms, from just after birth to a few weeks or months before diagnosis.

The lipomas were located on the right side of vulva in 6 cases (85.7%), and only 1 case had a lipoma on the left lateral side. Among the 6 right-side cases, 4 cases had lipomas on the right anterolateral side of the vulva ([Fig. 1](#)) and 2 cases had lipomas on the right lateral side.

The gross appearances of lipoma can be categorized into 2 types as follows: soft tissue swelling with ill-defined mass and well-demarcated or pedunculated mass. Five cases (71.4%), including all 4 right anterolateral side cases and the 1 right lateral side case, had appearance of soft tissue swelling with ill-defined mass. The right lateral side case showed a 4 × 3-cm well-demarcated cystic lesion, and the left lateral side case showed a 7-cm pedunculated cystic lesion.

The initial tentative diagnoses made before imaging studies were right inguinal hernia in 4 cases, Bartholin's cyst in 2 cases, and right vulvar mass in 1 case. All 4 cases of lipoma, which were located on the right anterolateral side of vulva, were diagnosed as right inguinal hernia by primary care physicians. Before being referred to our hospital, 2 patients underwent inguinal hernia operations at outside hospitals, but their symptoms did not disappear.

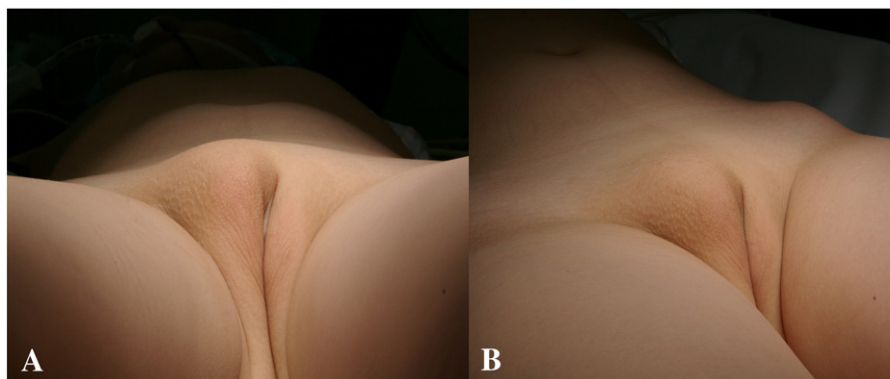


Fig. 1 Photograph of a vulvar lipoma (case 1) showing soft tissue swelling on the right lower inguinal area and anterolateral side of the vulva. Front (A) and lateral (B) views.

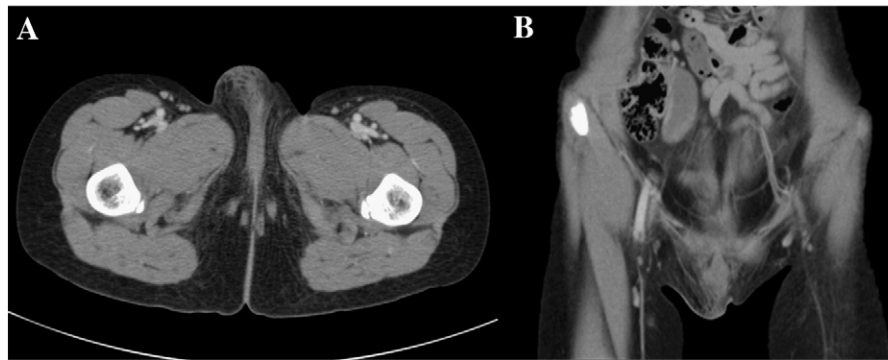

Fig. 3 Computed tomography (case 2) showing swelling of the right labium major with infiltrative changes in the subcutaneous layer of the mons pubis and lower anterior abdominal wall. Axial (A) and coronal (B) views.

Five patients with poorly defined masses underwent preoperative imaging studies: 1 ultrasound, 2 computed tomography, 1 magnetic resonance imaging, and 1 ultrasound and magnetic resonance imaging. All studies showed lipomatous characteristics of these tumors. In case 1 and case 3, magnetic resonance imaging showed a swollen labium major with irregular high-signal intensities in fat-suppressed T2-weighted images (Fig. 2). Case 2 and case 4 showed swelling of the right labium major with infiltrative changes in the subcutaneous layer of the mons pubis and lower anterior abdominal wall on computed tomographic images (Fig. 3). Ultrasonography also showed a diffusely increased echogenicity of subcutaneous fat in the right labium major in case 1 and case 5 (Fig. 4).

All cases underwent surgical excision under general anesthesia. Subsequent histopathologic examination revealed mature fat tissue, consistent with lipoma in each case.

3. Discussion

Although lipomas are the most common soft tissue tumor, involvement of the vulva is rarely reported. In a review of the relevant literature, approximately 70 cases of vulvar lipomas

have been reported, and all of the reported literature was limited to case reports [2-11]. The incidence of vulvar lipomas in children is so low that fewer than 10 cases have been reported [2-6]. To our knowledge, this is the first study, in either children or adults, where a series of cases has been reviewed.

The clinical manifestations of vulvar lipomas vary depending on their location in the vulva, size of the mass, and their appearance. In previous reports, a well-demarcated pedunculated mass was a common finding [4,5,8,9], and presentation as ambiguous genitalia were found [3,6]. However, nonpedunculated vulvar swelling because of subcutaneous fat deposition has also been reported [10,11]. In our study, the latter appearance was more common. Five cases presented as swelling of the vulva, and only 2 cases presented as well-demarcated masses.

Vulvar lipomas are predominantly found on the right side. This was observed in our study and also in previous reports [2,7-11]. In our study, 6 of 7 patients had lipomas on the right side. Four of 7 cases presented as a nonpedunculated vulvar swelling on the right anterolateral side. This presentation mimics right inguinal hernias and must be included in the differential diagnosis. In our study, all 4 cases were diagnosed as a right inguinal hernia by primary care physicians. As a consequence, 2 of them underwent an

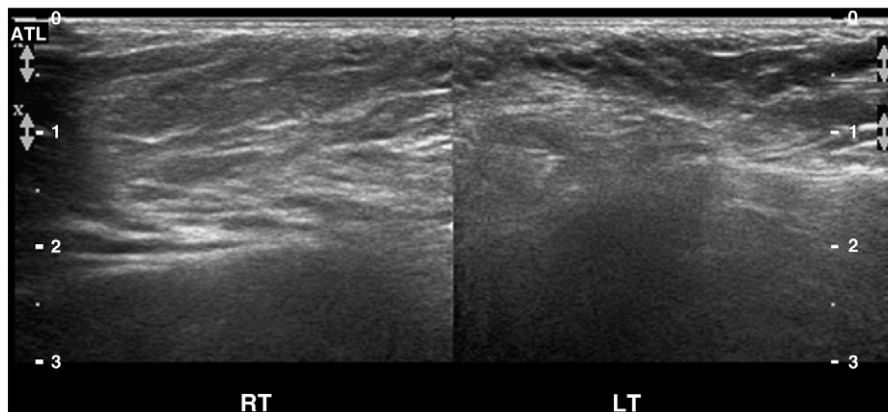


Fig. 4 Ultrasonography (case 5) showing a diffusely increased echogenicity of subcutaneous fat in the right labium major (RT) in comparison to the contralateral region of the left labium major (LT).

inguinal hernia operation. When a girl presents with irreducible right lower inguinal area swelling, careful physical examination is required, and vulvar lipoma should be included in the differential diagnosis.

The differential diagnosis of vulvar lipomas includes various types of benign and malignant tumors, Bartholin's cyst, and an inguinal hernia [8,12]. Although careful physical examination is mandatory to avoid misdiagnosis, presentation of soft consistency swelling is sometimes difficult to differentiate clinically and need radiologic evaluation.

Ultrasound, computed tomography, and magnetic resonance imaging are useful in diagnosing lipomas and differentiating them from vulvar cysts or inguinal hernias. Compared to the hypoechoic cystic appearance of Bartholin's cysts or other vulvar cysts [13] and the presence of the peritoneal lining and hernial contents of inguinal hernias [14], vulvar lipomas appear on ultrasound as nonspecific homogenous masses with lobular structures consistent with fat deposition [10]. Computed tomography and magnetic resonance imaging also show lipomatous characteristics of these tumors and are useful for evaluating tumor extensions and anatomical relationship with the surrounding structures [4,8,11]. Microscopically, vulvar lipomas need to be differentiated from liposarcoma or lipoma-like variants, although the incidence of this is very rare in children [15-17].

Like other lipomas, vulvar lipomas have a benign clinical course. They grow slowly and cause few problems other than those of a localized mass [1]. If these tumors are left untreated, they may grow large as in the case reported by Kehagias et al [8]. With this in mind, although other nonexcisional techniques could be applied, the treatment of choice is complete surgical resection [8,9,18].

In summary, vulvar lipomas in children tend to occur on the right side, especially the right anterolateral side. This tumor should be included in the differential diagnosis for an inguinal hernia. Radiologic imaging studies such as ultrasound, computed tomography, and magnetic resonance

imaging are useful for making the diagnosis. Surgical excision is the treatment of choice.

References

- [1] Weiss SW, Goldblum JR. Benign lipomatous tumors. In: Weiss SW, Goldblum JR, editors. *Enzinger and Weiss's soft tissue tumors*. 4th ed. St Louis (Mo): Mosby; 2001. p. 429-37.
- [2] Fukamizu H, Matsumoto K, Inoue K, et al. Large vulvar lipoma. *Arch Dermatol* 1982;118:447.
- [3] Van Glabeke E, Audry G, Hervet F, et al. Lipoma of the preputium clitoridis in neonate: an exceptional abnormality different from ambiguous genitalia. *Pediatr Surg Int* 1999;15:147-8.
- [4] Ogasawara Y, Ichimiya M, Nomura S, et al. Perineal lipoma in a neonate. *J Dermatol* 2001;28:165-7.
- [5] Redman JF, Ick KA, North PE. Perineal lipoma and an accessory labial fold in a female neonate. *J Urol* 2001;166:1450.
- [6] Guerra-Junior G, Aun AM, Miranda ML, et al. Congenital perineal lipoma presenting as ambiguous genitalia. *Eur J Pediatr Surg* 2008;18: 269-71.
- [7] De Lima Filho OA, Cogliati AO, Reitzfeld G. Lipoma of the vulva. *Rev Paul Med* 1969;75:165-76.
- [8] Kehagias DT, Smyrniotis VE, Karvounis EE, et al. Large lipoma of the vulva. *Eur J Obstet Gynecol Reprod Biol* 1999;84:5-6.
- [9] Agarwal U, Dahiya P, Sangwan K. Vulval lipoma: a rare occurrence. *Arch Gynecol Obstet* 2004;270:59-60.
- [10] Sherer DM, Gorelick C, Wagleich A, et al. Sonographic findings of a large vulvar lipoma. *Ultrasound Obstet Gynecol* 2007;30:786-7.
- [11] Lee JH, Chung SM. Large vulvar lipoma in an adolescent: a case report. *J Korean Med Sci* 2008;23:744-6.
- [12] Marzano DA, Haefner HK. The Bartholin gland cyst: past, present, and future. *J Low Genit Tract Dis* 2004;8:195-204.
- [13] Eppel W, Frigo P, Worda C, et al. Ultrasound imaging of Bartholin's cysts. *Gynecol Obstet Invest* 2000;49:179-82.
- [14] van den Berg JC. Inguinal hernias: MRI and ultrasound. *Semin Ultrasound CT MR* 2002;23:156-73.
- [15] Brooks JJ, LiVolsi VA. Liposarcoma presenting on the vulva. *Am J Obstet Gynecol* 1987;156:73-5.
- [16] Zámečník M, Michal M, Sulc M. Atypical lipomatous tumors with smooth muscle differentiation: report of two cases. *Pathology* 1999;31: 425-7.
- [17] Atallah D, Rouzier R, Chamoun ML, et al. Benign lipoblastomalike tumor of the vulva: report of a case affecting a young patient. *J Reprod Med* 2007;52:223-4.
- [18] Salam GA. Lipoma excision. *Am Fam Physician* 2002;65:901-4.