



# The surgical approach to esophageal atresia repair and the management of long-gap atresia: results of a survey

Ori Ron, Paolo De Coppi, Agostino Pierro

*From the Department of Paediatric Surgery, Institute of Child Health & Great Ormond Street Hospital, London, United Kingdom.*

## KEYWORDS

Esophageal atresia;  
 Thoracoscopic;  
 Long gap;  
 Survey

The optimal approach for esophageal atresia (OA) repair and technique used for long-gap OA repair are controversial. There are few data comparing the outcomes of the different approaches and techniques. We performed a survey of current practice of 88 pediatric surgeons and asked experts to provide us with definitions and rationales behind their management strategies. There were no differences between UK and non-UK surgeons. Although the majority of pediatric surgeons perform minimally invasive surgery (68%), only 16% have performed thoracoscopic OA repair; however, 46% are planning to carry out thoracoscopic OA repair. Gastric interposition is the most preferred technique for long-gap OA when primary anastomosis is not possible, with 94% of those surgeons who use the technique satisfied with it. Growth of the esophageal ends by traction is the other major technique used, but only 76% of surgeons who use it are satisfied with it. Most surgeons repair  $\leq 2$  patients with long-gap OAs per year. Long-gap OA should be managed by a limited number of surgeons at each center. Even among experts, there is little consensus on the definition of or the optimum technique for repair of long-gap OA.  
 © 2009 Published by Elsevier Inc.

Any discussion on esophageal atresia (OA) is replete with controversy. The variety of treatment strategies that have been employed to treat this anomaly testify to the challenge it presents.

A recent development in the management of OA has been the ability to perform esophago-esophagostomy by minimal access techniques.<sup>1-5</sup> Proponents of thoracoscopic OA repair cite avoidance of the complications of thoracotomy,<sup>6-10</sup> uniform compression of the ipsilateral lung from the induced pneumothorax,<sup>11</sup> and superior anatomical visualization as the principle advantages.<sup>3</sup> One criticism of the technique is that it utilizes a transpleural approach, although there are now case reports of successful extrapleural thoracoscopic OA repairs<sup>12,13</sup>; in addition, surgeons believe that

the anastomosis could be performed with more precision via a thoracotomy.

Long-gap esophageal atresia (LGOA) further complicates the debate on OA. The very definition of LGOA is hugely variable. It has been reported as pure OA, OA with a proximal pouch fistula, the width of the gap between esophageal pouches has been defined in either centimeters or vertebral bodies, and that gap has been measured by a variety of different means, including: preoperatively, with distension of the pouches and without; intraoperatively, with mobilization of the pouches and without; and also by the definition we favor, that is the inability to perform a primary anastomosis.<sup>14-18</sup>

The challenge of LGOA is to restore intestinal continuity, and the old adage “the best esophagus is the patient’s own esophagus” has long been held true by pediatric surgeons. However, this is not always possible and sometimes the native esophagus is preserved but at the cost of unacceptable morbidity (eg, anastomotic leak, severe gastro-

---

**Address reprint requests and correspondence:** Professor Agostino Pierro, Surgery Unit, Institute of Child Health, 30 Guilford Street, WC1N 1EH, London, UK.

E-mail: [A.Pierro@ich.ucl.ac.uk](mailto:A.Pierro@ich.ucl.ac.uk) or [Pierro.sec@ich.ucl.ac.uk](mailto:Pierro.sec@ich.ucl.ac.uk).

esophageal reflux, recurrent dilatations of esophageal strictures, repeated hospitalizations). When this occurs, an optimally functioning replacement conduit must be fashioned. Treatment strategies include elongation of the esophageal pouches before attempted anastomosis,<sup>19</sup> intraoperative techniques to facilitate anastomosis,<sup>16,20,21</sup> and esophageal replacement.<sup>22</sup> There is little consensus on these issues, no randomized controlled trials, and few data comparing the different strategies. Objective comparison is further complicated by the wide variations in definitions used and outcomes reported.

The aim of this article is to present the views of pediatric surgeons on the optimal approach to OA repair (ie, thoracotomy or thoracoscopy) and to the management of LGOA (ie, growth induction by traction, gastric interposition, jejunal graft, and colonic interposition).

**Methods**

During the international scientific meeting of the British Association of Pediatric Surgeons (Edinburgh, Scotland,

July 2007), a symposium was held on “Controversies in Esophageal Atresia.” This was aimed at addressing the following issues related to esophageal atresia repair:

- The surgical approach: Thoracotomy (R.G. Azizkhan, Cincinnati USA); Thoracoscopy (G. MacKinlay, Edinburgh UK);
- The management of long gap atresia: Growth induction by traction (J.E. Foker, USA); Gastric interposition (L. Spitz, London, UK); Jejunal graft (N.M.A. Bax, Rotterdam, The Netherlands); Colonic interposition (A.F. Hamza, Cairo, Egypt).
- At the time of the above symposium, a survey of the delegates’ opinion was performed. This was based on a written questionnaire (Figure 1) that was circulated before the symposium and returned to the BAPS secretariat at the end of the symposium.
- Comparisons between groups were made using Fisher’s Exact Test.
- In addition, before the symposium, the moderator (A. Pierro) asked the expert panel to provide the following: for the surgical approach, one concise reason to use tho-

<b>Consultant Surgeon</b>	<input type="checkbox"/>	<b>UK</b>	<input type="checkbox"/>
<b>Trainee</b>	<input type="checkbox"/>	<b>Non-UK</b>	<input type="checkbox"/>

**The surgical approach**

**Yes No**

<b>Do you perform minimally invasive surgery?</b>	<input type="checkbox"/>	<input type="checkbox"/>
<b>Have you repaired OA thoracoscopically?</b>	<input type="checkbox"/>	<input type="checkbox"/>
<b>Are you planning to repair OA thoracoscopically?</b>	<input type="checkbox"/>	<input type="checkbox"/>

**Management of long gap OA**

**Which is your preferred technique for long gap OA repair (primary anastomosis not feasible)?**

<b>Growth by traction</b>	<input type="checkbox"/>
<b>Gastric interposition</b>	<input type="checkbox"/>
<b>Jejunal interposition</b>	<input type="checkbox"/>
<b>Colonic interposition</b>	<input type="checkbox"/>

**How many of your preferred operation do you perform every year?**

$\leq 2$	<input type="checkbox"/>	3-5	<input type="checkbox"/>	$> 5$	<input type="checkbox"/>
----------	--------------------------	-----	--------------------------	-------	--------------------------

**Yes No**

<b>Are you satisfied by the technique you are currently using?</b>	<input type="checkbox"/>	<input type="checkbox"/>
<b>Are you planning to change your technique based on this symposium?</b>	<input type="checkbox"/>	<input type="checkbox"/>

**Figure 1** Questionnaire completed by pediatric surgeons at the symposium on “Controversies in Esophageal Atresia Repair” (British Association of Pediatric Surgeons, Annual International Meeting, Edinburgh, Scotland, July 2007).

**Table 1** Responses of pediatric surgeons on approach of OA repair

	Consultants			Trainees		
	UK <i>n</i> = 23	Non-UK <i>n</i> = 46	Total	UK <i>n</i> = 14	Non-UK <i>n</i> = 5	Total
Perform minimally invasive surgery	16 (70)	35 (78)	51 (75)	5 (36)	4 (80)	9 (47)
Have repaired OA thoracoscopically	3 (14)	9 (20)	12 (18)	1 (7)	1 (20)	2 (11)
Planning to repair OA thoracoscopically	7 (33)	23 (56)	30 (48)	4 (29)	3 (75)	7 (39)

Note: percentages are given in parentheses.

racotomy or thoracoscopy; for the management of long-gap atresia, the definition of long gap and one concise reason to use the technique presented.

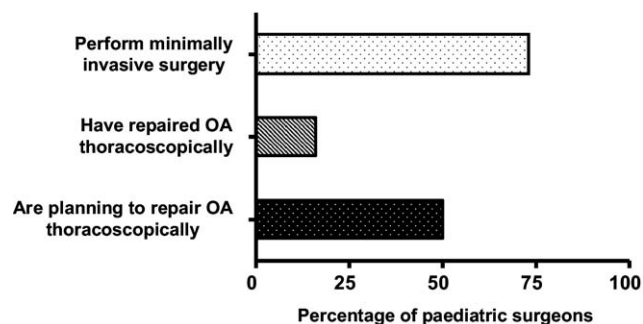
## Results

### Survey of pediatric surgeons

The questionnaire was completed by 100 pediatric surgeons. Twelve questionnaires were incomplete regarding the grade of surgeon (consultant or trainee) and origin (UK or non-UK) and therefore were excluded from the analysis. Of the 88 valid questionnaires, 69 were completed by consultants and 19 by trainees. There were 37 pediatric surgeons from the United Kingdom and 51 from other countries.

The questionnaire indicated that minimally invasive surgery is performed by 75% of consultant surgeons and 47% of trainees (Table 1 and Figure 2). Thoracoscopic repair of esophageal atresia is currently performed by 16% of pediatric surgeons (18% consultants and 11% trainees). However, 46% (48% consultants and 39% trainees) are planning to perform the repair thoracoscopically. Both for consultants and trainees there were no statistically significant differences between UK and non-UK pediatric surgeons.

The responses regarding the preferred management of OA when primary anastomosis is not possible are summarized in Tables 2 and 3 and in Figure 3. The most common technique for managing LGOA (84 responders) is gastric



**Figure 2** Responses of pediatric surgeons on the approach for OA repair.

interposition (48% of surgeons), but 39% of surgeons prefer to use growth by traction as described by Foker<sup>16</sup> (Table 2 and Figure 3a). There were no differences between UK and non-UK surgeons in the choice of operation (Table 2 and Figure 3b). Table 3 shows the number of patients with LGOAs treated each year by UK and non-UK surgeons. Most surgeons repair  $\leq 2$  LGOAs per year (60 of 82 responders; 73%), and the distribution of type of operation performed remains similar to the entire population (gastric interposition 51%, growth by traction 39%, jejunal interposition 7%, and colonic interposition 3%).

Surgeon satisfaction with their preferred technique was 84% when  $\leq 2$  operations were done per year; 88% when 3 to 5 operations were performed per year; and 100% when  $> 5$  operations were done. We analyzed surgeon satisfaction according to the technique used: colonic interposition was used by 6 surgeons, all satisfied; gastric transposition was used by 36 surgeons, and 2 of these were not satisfied (6%); growth by traction was used by 22 surgeons, and 7 (24%) were not satisfied; finally, jejunal graft was used by 3 surgeons, of which 1 was dissatisfied.

When asked about the effect of the symposium on their opinion, 21% of consultants and 29% of trainees if surgeons were keen to change technique on the basis of what they had heard at the symposium.

### Expert panel comments

#### The surgical approach

The reasons to use thoracotomy during OA repair were summarized by R.G. Azizkhan as: “standard technique worldwide, versatile for most variants of esophageal atresia, useful in complex problems, high survival, good quality of

**Table 2** The preferred technique for managing LGOA repair of UK and non-UK pediatric surgeons

Preferred technique	UK <i>n</i> = 35	Non-UK <i>n</i> = 49	Total
Colonic interposition	1 (3)	6 (12)	7 (8)
Gastric interposition	16 (46)	24 (49)	40 (48)
Growth by traction	15 (43)	18 (37)	33 (39)
Jejunal interposition	3 (8)	1 (2)	4 (5)

Note: percentages are given in parentheses.

**Table 3** Number of LGOA repairs performed by UK and non-UK pediatric surgeons

Number of LGOAs repaired per year	UK n = 34	Non-UK n = 48	Total
≤2	33 (97)	27 (56)	60 (73)
3 to 5	0	16 (33)	16 (20)
>5	1 (3)	5 (11)	6 (7)

Note: percentages are given in parentheses.

life.” The reasons to use thoracoscopy were related by G. MacKinlay to “much improved visualization of the anatomy and improved cosmesis after repair.”

### The management of long-gap atresia

The following definitions were given for long-gap esophageal atresia:

1. “Too long for a true primary repair.” (J.E. Foker)
2. “No distal fistula - measured gap of at least 6 vertebrae.” (L. Spitz)
3. “Atresia without distal fistula.” (N.M.A. Bax)
4. “Gap more than 3 vertebrae.” (A.F. Hamza)

The following reasons were provided for the technique used to repair LGOA:

1. Growth by traction: “One’s own esophagus is best.” (J.E. Foker<sup>23</sup>)
2. Gastric interposition: “Reliability and ease of procedure.” (L. Spitz<sup>24</sup>)
3. Jejunal graft: “Good long-term functional results.” (N.M.A. Bax<sup>25</sup>)
4. Colonic interposition: “Long-term results are very good, very close to normal life.” (A.F. Hamza<sup>26</sup>)

### Discussion

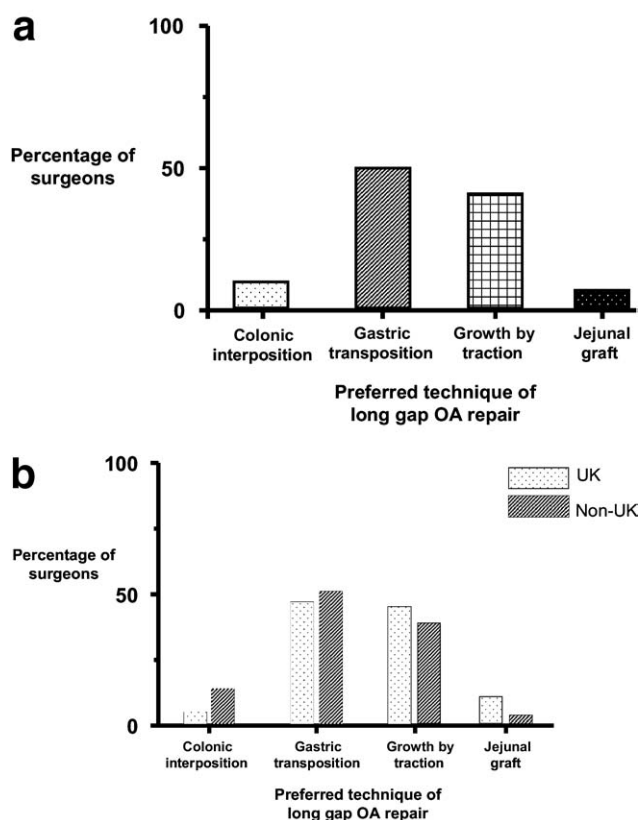
There have been no randomized controlled trials comparing different approaches used for OA repair or comparing the various techniques used to manage LGOA. This study gives insight into the contemporary views of pediatric surgeons on these challenging issues.

Minimal access surgery is performed by 73% of the pediatric surgeons we surveyed, and although the techniques are being applied to an ever-increasing range of operations, there are little data comparing the outcomes with those of the open versions for most procedures.

Complications from thoracotomy, such as acute and chronic postoperative pain, rib fusion, scoliosis, and chest wall deformities, have all been reported following OA repair.<sup>6-10</sup> Although a minimal access approach would pre-

sumably avoid these complications, refinements in open surgical technique have probably led to a decrease in their incidence following thoracotomy as well. Scarring, however, remains a concern for these little patients and their families and has led to the development of techniques that preserve muscle integrity (sparing muscle) and improve cosmesis (high axillary skin crease approach).<sup>27</sup> Better visualization of the anatomy from the magnification provided by the endoscope has been reported and has also been the experience of the authors. Currently, however, most pediatric surgeons prefer thoracotomy for OA repair. We speculate that this may be because thoracoscopic OA repair is technically difficult to perform; several authors have recommended that it only be performed at centers, and by surgeons, with established expertise in minimally access surgery.<sup>3</sup> The benefit on functional outcome of thoracoscopic OA repair is unknown. To date there has been just one small retrospective study comparing thoracoscopic versus open OA repair by Lugo and coworkers,<sup>11</sup> and this suggests that the two approaches have comparable outcomes.

In our survey, the most commonly performed operation when primary anastomosis was not feasible was the gastric interposition. Professor L. Spitz, a leading proponent of



**Figure 3** (a) Preferred techniques for repairing LGOA when primary anastomosis is not feasible. (b) Preferred techniques for repairing LGOA when primary anastomosis is not feasible of UK and non-UK pediatric surgeons.



gastric interposition, cites reliability and ease of procedure among its advantages. In his personal series of gastric interpositions, which included 127 children with OA, long-term functional outcome was good or excellent in 90%.<sup>24</sup> In our survey, 94% of the surgeons who use this as their preferred technique are satisfied with it. Only 8% of the surgeons we surveyed perform colonic interposition, but all seem to be satisfied with the results achieved. This small number may be due to the fact that many pediatric surgeons have abandoned this technique with time. A recent long-term outcome study shows that there is a high rate of complications following colonic interposition. In a recent study by Coopman and coworkers,<sup>28</sup> complications occurred less than 1 year postoperatively in 53% and long-term complications (occurring >1 year after surgery) in 84% of the 32 patients.

Although Foker's description of inducing growth of the esophageal pouches by traction before primary repair is a relevantly recent innovation,<sup>29</sup> it was the second most preferred technique of the surgeons we surveyed (39%). However, a relatively high proportion of surgeons who use this technique, 24%, were not satisfied with it. A comprehensive update by Dr. J.E. Foker can be found in this issue of the journal.

LGOA is a rare anomaly with 73% of surgeons we surveyed repairing 2 or less per year. These data suggest that most surgeons are therefore not accumulating a large experience with any of the techniques available. Given the widely reported difficulties in managing LGOA, to prevent excess dilution of experience, we would suggest that cases should perhaps be concentrated to a limited number of surgeons (eg, 1 or 2) in each center.

The experience of the individual members of the symposium panel in the management of OA and LGOA is well known. They have all successfully utilized different techniques and published results with good outcomes. Currently, most surgeons use thoracotomy for OA repair and either gastric interposition or growth by traction for LGOA repair. With expert opinion divided and without comparative evidence, choice of technique currently remains a matter for individual surgeons and their individual training and experience, but there is a clear need for high-quality, randomized, comparative studies.

## Acknowledgments

We thank and gratefully acknowledge the following for their help with the symposium: R.G. Azizkhan, N.M.A. Bax, J.E. Foker, A.F. Hamza, G.A. MacKinlay, L. Spitz, the BAPS secretariat, and all the delegates of the international scientific meeting of the British Association of Pediatric Surgeons (Edinburgh, Scotland, July 2007) who took part in the survey.

## References

1. Lobe TE, Rothenberg SS, Waldschmidt J, et al. Thoracoscopic repair of esophageal atresia in an infant: a surgical first. *Pediatr Endosurg Innovative Tech* 1999;3:141-8.
2. Rothenberg SS. Thoracoscopic repair of a tracheoesophageal fistula in a newborn infant. *Pediatr Endosurg Innovative Tech* 2000;4:289-94.
3. Holcomb GW III, Rothenberg SS, Bax KMA, et al. Thoracoscopic repair of esophageal atresia and tracheoesophageal fistula. A multi-institutional analysis. *Ann Surg* 2005;242:422-30.
4. Allal H, Kalfa N, Lopez M, et al. Benefits of the thoracoscopic approach for short- or long-gap esophageal atresia. *J Laparoendosc Adv Surg Tech A* 2005;15:673-7.
5. Nguyen T, Zainabadi K, Bui T, et al. Thoracoscopic repair of esophageal atresia and tracheoesophageal fistula: lessons learned. *J Laparoendosc Adv Surg Tech A* 2006;16:174-8.
6. Freeman NV, Walkden J. Previously unreported shoulder deformity following right lateral thoracotomy for esophageal atresia. *J Pediatr Surg* 1969;4:627-36.
7. Durning RP, Scoles PV, Fox OD. Scoliosis after thoracotomy in tracheoesophageal fistula patients. *J Bone Joint Surg Am* 1980;62:1156-8.
8. Jaureguizar E, Vazquez J, Murcia J, et al. Morbid musculoskeletal sequelae of thoracotomy for tracheoesophageal fistula. *J Pediatr Surg* 1985;20:511-4.
9. Cherup LL, Siewers RD, Futrell JW. Breast and pectoral muscle maldevelopment after anterolateral and posterolateral thoracotomies in children. *Ann Thorac Surg* 1986;41:492-7.
10. Chetcuti P, Myers NA, Phelan PD, et al. Chest wall deformity in patients with repaired esophageal atresia. *J Pediatr Surg* 1989;24:244-7.
11. Lugo B, Malhotra A, Guner Y, et al. Thoracoscopic versus open repair of tracheoesophageal fistula and esophageal atresia. *J Laparoendosc Adv Surg Tech A* 2008;18:753-6.
12. Tantoco J, Rossman J, Dixey L, et al. Minimal access extrapleural esophagoesophagostomy. *J Pediatr Surg* 2004;39:855-8.
13. Tsao K, Lee H. Extrapleural thoracoscopic repair of esophageal atresia with tracheoesophageal fistula. *Pediatr Surg Int* 2005;21:308-10.
14. Ein SH, Shandling B. Pure esophageal atresia: a 50-year review. *J Pediatr Surg* 1994;29:1208-11.
15. Lindahl H, Rintala R. Long-term complications in cases of isolated esophageal atresia treated with esophageal anastomosis. *J Pediatr Surg* 1995;8:1222-3.
16. Foker JE, Linden BC, Boyle EM. Development of a true primary repair for the full spectrum of esophageal atresia. *Ann Surg* 1997;226:533-43.
17. Bagolan P, Lacobelli BD, De Angelis P, et al. Long gap esophageal atresia and esophageal replacement: moving toward a separation? *J Pediatr Surg* 2004;39:1084-90.
18. Al-Shanafey S, Harvey J. Long gap esophageal atresia: an Australian experience. *J Pediatr Surg* 2008;43:597-601.
19. Howard R, Myers NA. Esophageal atresia: a technique for elongating the upper pouch. *Surgery* 1965;58:725.
20. Livaditis A. Esophageal atresia: a method of overbridging large segmental gaps. *Z Kinderchir* 1973;13:298-306.
21. Gough MH. Esophageal atresia: use of an anterior flap in difficult anastomosis. *J Pediatr Surg* 1980;15:310-11.
22. Spitz L. Esophageal replacement. In: Grosfeld JL, O'Neil JA Jr, Fonkalsrud EW, et al., eds. *Pediatric Surgery*. St. Louis, MO: Mosby, 2006:1093-106.
23. Foker JE, Kendall TC, Catton K, et al. A flexible approach to achieve a true primary repair for all infants with esophageal atresia. *Semin Pediatr Surg* 2005;14:8-15.
24. Spitz L, Kiely E, Pierro A. Gastric transposition in children: a 21-year experience. *J Pediatr Surg* 2004;39:276-81.

25. Bax NMA, van der Zee DC. Jejunal pedicle grafts for reconstruction of the esophagus in children. *J Pediatr Surg* 2007;42:363-9.
26. Hamza AF, Abdelhay S, Sherif H, et al. Caustic esophageal strictures in children: 30 years' experience. *J Pediatr Surg* 2003;38:828-33.
27. Bianchi A, Sowande O, Alizai NK, et al. Aesthetics and lateral thoracotomy in the neonate. *J Pediatr Surg* 1998;33:1798-800.
28. Coopman S, Michaud L, Halna-Tamine M, et al. Long-term outcome of colon interposition after esophagectomy in children. *J Pediatr Gastroenterol Nutr* 2008;47:458-62.
29. Boyle EM Jr, Irwin ED, Foker JE. Primary repair of ultra-long-gap esophageal atresia: results without a lengthening procedure. *Ann Thorac Surg* 1994;57:576-9.