Histopathology 2000, **36**, 564–572

Correspondence

Late malignant transformation of biopsy proven benign synovial chondromatosis: an unexpected pitfall

Sir: Synovial chondrosarcoma is a very rare disease with only 34 reported cases, mostly involving the knee. Most cases show evidence of concurrent, and presumably pre-existing, synovial chondromatosis.[1,2] Misdiagnosing synovial chondromatosis as chondrosarcoma is a well-known pitfall in orthopaedic pathology. Underdiagnosis of malignancy in the setting of synovial chondromatosis is a lesser-documented serious danger.

We report a 64-year-old man who first presented because of pain in the right hip region. The X-ray showed signs of synovial chondromatosis. Two years later a partial synovectomy, with removal of multiple chondromatous nodules, was performed. Histological examination confirmed the clinical diagnosis of synovial chondromatosis.

Seven and eight years later subtotal synovectomies were performed because of recurring invalidating complaints. Additional clinical and radiological examination performed before both procedures suggested recurring chondromatosis which was confirmed histologically.

Ten years after first presentation the patient revisited his surgeon with a large nodular subcutaneous mass in the soft tissues surrounding the right hip. X-ray and MRI (Figure 1) revealed a multilobular soft tissue mass, completely surrounding the hip joint, with extension in all directions and displacement of surrounding tissues, indicating a sarcoma-like tumour. An open biopsy was performed in our hospital. Microscopical examination showed, areas with loss of clustering pattern, marked hypercellularity and spindling of the cells at the periphery of cartilaginous nodules, as well as areas with chondrocytes arranged in clusters with abundant intercellular matrix. Binucleated chondrocytes and pronounced cytological atypia were present, although no mitotic figures were seen. Focal myxoid changes and necrosis were present. An initial diagnosis of chondrosarcoma grade 1 was made which was confirmed by the AFIP in Washington.

We reviewed the slides from the earlier procedures and we considered the microscopic findings, in all three specimens, to be consistent with the diagnosis of synovial chondromatosis only. The reviewing staff of the AFIP in Washington, however, only interpreted the first specimen as synovial chondromatosis although small foci of pronounced chondrocytic atypia were identified that were quite disturbing (in retrospect). All reviewers regarded the last two specimens as synovial chondromatosis with multiple foci that had already undergone malignant transformation to low-grade chondrosarcoma. The tumour displayed foci with marked chondrocytic atypia which was regarded as cytologically malignant. One slide from the first recurrence also displayed entrapment of bone trabeculae which was regarded as architecturally malignant (Figure 2).

The only curative option was an external hemipelvectomy. The patient refused this mutilating operation and died 10 years after first presentation because of sepsis complicating installation of an epidural catheter.

This case illustrates the difficulties in the differential diagnosis between synovial chondromatosis vs. chondrosarcoma. Clinical and radiographic features are often the same, however, a diagnostic gross feature of malignancy is widespread extension of lobulated cartilaginous masses far beyond the joint capsule and into the surrounding soft tissue or bone,[1] as present in our case in the final recurrence. Bertoni *et al.*[3] defined histological features that are most important to diagnose malignancy: loss of clustering growth pattern of cartilage cells; myxoid change in the matrix; areas of necrosis; hypercellularity with crowding and spindling of the cells at the periphery; and also permeation of trabecular bone with filling-up of marrow spaces. However, despite the formulation of these features,

Figure 1. MRI showing a large multilobular sarcoma-like tumour surrounding the right hip joint, 10 years after first presentation.

© 2000 Blackwell Science Limited.

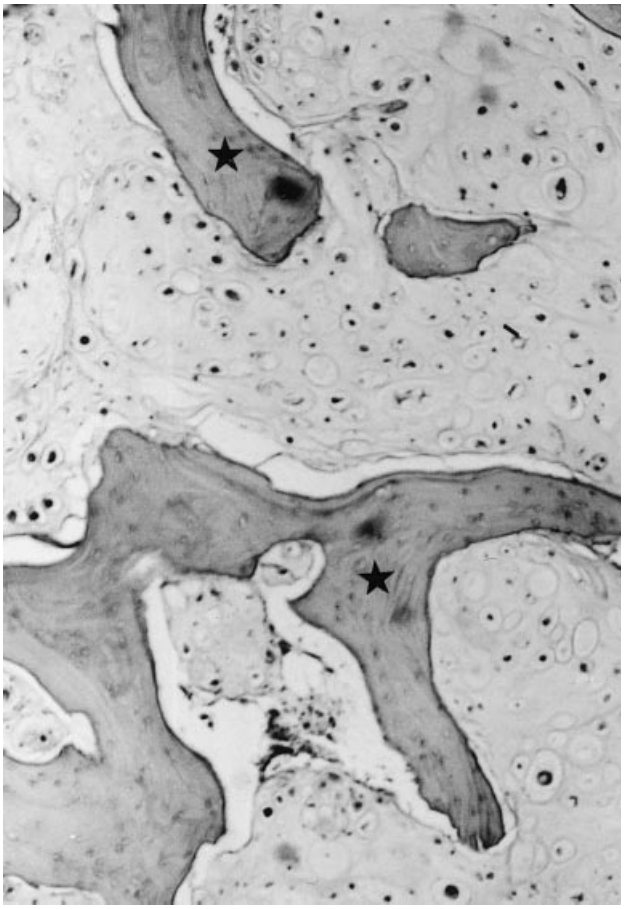

Figure 2. The first recurrence showing grade 1 synovial chondrosarcoma with permeation of trabecular bone (asterisk) with filling-up of marrow spaces. This entrapment of bone trabeculae is regarded as an architecturally malignant feature (× 100).

which are certainly helpful in diagnosis, some of the histological features remain liable to subjective interpretation by individual pathologists, like estimation what a grade of cytological atypia and degree of hypercellularity are still acceptable in the benign condition. It also remains unclear how many of these features are mandatory for diagnosis of malignancy.

Furthermore, the microscopic features described by Bertoni *et al.* are only valid if they coincide with radiographic and clinical findings, and several authors state that diagnosis of grade 1 synovial chondrosarcoma probably should only be made in conjunction with unequivocal invasion beyond the joint capsule, in order to distinguish it from synovial chondromatosis with prominent nuclear atypia.[1,2]

In our case the last specimen microscopically showed many features of malignancy as defined by Bertoni. Furthermore clinical and radiological features were consistent with sarcoma and a diagnosis of grade 1 synovial chondrosarcoma could be made. The specimens of the first two recurrences, in retrospect, also showed to some extent histological features indicative of malignancy, although more subtle, and differential diagnosis proved difficult. Also clinical and radiological findings didn't point towards malignancy. However, in one slide of the first recurrence, entrapment of bone trabeculae, which is regarded as an architecturally malignant feature, was found by consulting experts: this permeative growth pattern seems to be a less subjective histological criterion of malignancy and is indicative of malignancy.

In conclusion, this case of synovial chondromatosis and secondary chondrosarcoma demonstrates the rare possibility of malignant transformation of this primarily benign lesion and illustrates the difficulties in differential diagnosis, due to partially subjective microscopic criteria for malignancy. In this respect, permeative growth pattern seems to be the most objective criterion. Especially in the case of low-grade chondrosarcoma of the synovium, the diagnosis should be based on clinical, radiographic, and microscopic evidence. In case of doubt an expert second opinion should be asked, to avoid serious therapeutic and prognostic consequences. The value of second opinion in cases of bone and soft tissue sarcomas is often underestimated.[4]

ACKNOWLEDGEMENTS

The authors would like to acknowledge Dr T.N. Vinh and Dr L.N. Howard from the department of Orthopaedic Pathology of AFIP in Washington D.C. for consulting opinion in this case.

W A M Blokx
L A J Rasing[1]
R P H Veth[1]
M Pruszczynski

Departments of Pathology and
[1]Orthopaedic Surgery,
Nijmegen University Hospital,
Nijmegen,
The Netherlands

1. Fechner RE, Mills SE. Lesions of the synovium. In: Rosai J, Sobin LH, eds. *Tumors of the Bones and Joints, Atlas of Tumour Pathology,* 3rd series, fascicle 8. Washington D.C.: AFIP, 1993: 279–282.
2. Dorfman HD, Czerniak B. Synovial lesions. In: *Bone Tumors.* St. Louis: Mosby, 1998: 1041–1061.
3. Bertoni F, Unni KK, Beabout JW *et al.* Chondrosarcomas of the synovium. *Cancer* 1991; **67**; 155–162.
4. Presant CA, Russell WO, Alexander RW *et al.* Soft-tissue and bone sarcoma peer review: the frequency of disagreement in diagnosis

and the need for second pathology opinions. The Southeastern cancer study group experience. *J. Clin. Oncol.* 1986; **4**; 1658–1661.

Primary cutaneous carcinoid tumour

Sir: Skin involvement by primary extracutaneous carcinoid tumours, particularly from the digestive and pulmonary tracts, is well documented.[1,2] On the contrary, only a few cases of primary cutaneous carcinoid tumours have been reported and their existence remains controversial.[3–6] We report a case of carcinoid tumour of the skin where negative extensive staging procedure and a long-term follow-up suggested a primary cutaneous origin.

A 60-year-old man presented an erythematous nodule on the anterior part of the chest. There were no clinical symptoms, diarrhoea, or facial flushing and physical examination was normal. Extensive investigation including chest X-ray, chest and abdominal CT scan, barium enema, bronchoscopy, colonoscopy and indium-111 pentreotide scintigraphy failed to detect extracutaneous location of the tumour. Urine levels of 5-hydroxyindole acetic acid (HIAA) were normal. Four years after tumour excision, the patient was free of symptoms without local recurrence, or extracutaneous dissemination of the tumour.

Histological examination showed a well circumscribed and multilobated tumour separated from the epidermis and extending downwards into the dermis (Figure 1). Lobules were well delimited and composed of regular round cells with an eosinophilic cytoplasm. Cells were arranged in cords or in different insular shapes within the lobules. Acinar charcteristics were observed in many lobules with lumen surrounded by cylindrical polarized cells with a basal nucleus (Figure 2). 'Pseudo-rosette' patterns were also observed in some nests. Mitotic figures were rare, and there was no cell atypia. Lobules were separated by a thin zone of

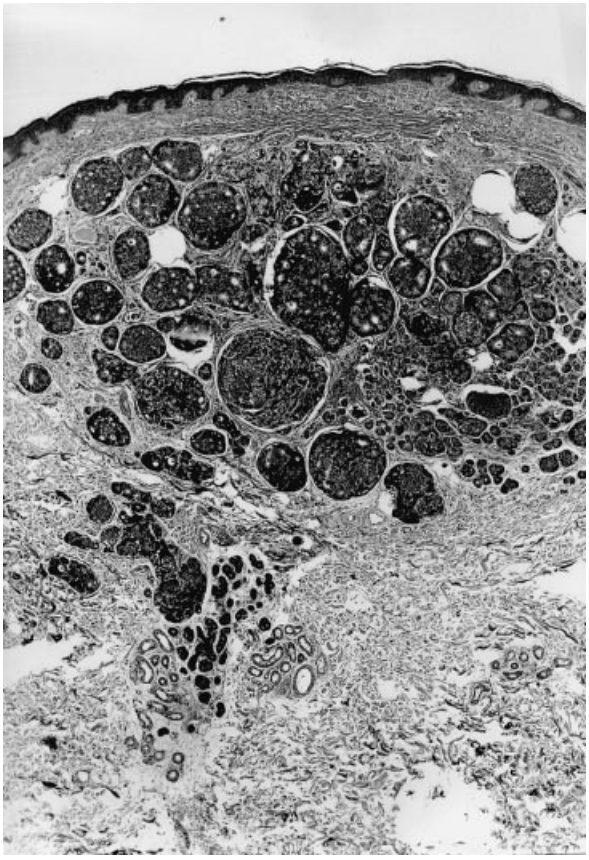

Figure 1. Histological appearance of the cutaneous carcinoid tumour. Multiple tumoral nodules within the dermis with no epidermal connection. Deepest nodules were close to eccrine glands.

Figure 2. Histological appearance of the cutaneous carcinoid tumour. Well delimited nodule composed of monomorphous cells with round nuclear and eosinophilic cytoplasm. A glandular differentiation was observed.

collagen stroma without inflammatory cells. Trabecular patterns or necrosis were not observed. Masson–Fontana and Grimelius staining revealed argentaffin and argyrophilic cytoplasmic granules, respectively, in almost all tumour cells.

Immunohistochemical assays were performed. A cytoplasmic staining of tumour cells was observed with neuron-specific enolase, chromogranin A, serotonin and cytokeratin KL1 markers.

Ulrastructural examination of the neoplastic cells showed microvilli bordering lumina and well differentiated desmosmal junctions were on the lateral sides of the cylindrical cells. Examination also revealed numerous dense cytoplasmic neurosecretory granules measuring 45–195 μm.

This case was diagnosed as a carcinoid skin tumour. Many findings suggest the primary cutaneous origin of the tumour: (a) skin metastases from primary extracutaneous carcinoid tumours are often multiple and usually occur some weeks to months after diagnosis of the primary tumour,[1] whereas the patient's tumour was solitary and did not recur after a 4-year follow-up period; (b) extensive investigations failed to detect a primary extracutaneous tumour.

Only four cases of primary cutaneous carcinoid tumour have been published.[3–6] The present case had many clinical and histological similarities with the previous reported cases. Indeed, the tumour was present for a long period before diagnosis (4–10 years) in four of five cases. Clinically, the five patients presented a solitary nodule 10–40 mm in diameter, located on the trunk or scalp. Histologically, four of five tumours were located in the dermis, separated from the epidermis and not ulcerated. These tumours showed multilobulated, insular and argentaffin patterns. Mitoses were infrequent or absent.

Immunohistochemical studies were performed in three of five cases and demonstrated positive staining with chromogranin A and keratin markers. Electron microscopic examination performed in three of five cases showed intracytoplasmic granules ≤ 300 μm and cylindrical cells with microvilli and desmosomal junctions.

The confirmation of a primary cutaneous carcinoid tumour raises the question of tumour cell origin. Regardless of their ultrastructural and immunohistochemical charcteristics, epidermal Merkel cells seem to be the most likely candidate. However, neuroendocrine differentiation of epithelial stem cells should also be considered.

Finally, the prognosis of patients with this rare cutaneous type of tumour appears rather favourable, an none of the five patients had recurrences after tumour removal with a mean follow-up period of 29 months.

P Courville
P Joly[1]
E Thomine
J Ziade[2]
J C Soubrane
J M Kuhn[3]
P Lauret[1]

Departments of Pathology,
[1]Dermatology and [3]Endocrinology,
Rouen University Hospital, Charles Nicholle, and
[2]Independent Pathology Laboratory,
Rouen, France

1. Rodriguez G, Villamizar R. Carcinoid tumour with skin metastasis. *Am. J. Dermatopathol.* 1992; **14**; 263–269.
2. Archer CB, Wells RSM, MacDonald DM. Metastatic cutaneous carcinoid. *J. Am. Acad. Dermatol.* 1985; **13**; 363–366.
3. Van Dijk C, Ten Seldam REJ. A possible primary cutaneous carcinoid. *Cancer* 1975; **36**; 1016–1020.
4. Smith PA, Chappell RH. Another possible primary carcinoid tumour of skin? *Virchows Arch. [a]* 1985; **408**; 99–103.
5. Collina G, Quarto F, Eusebi V. Trabecular carcinoid of the skin with cellular stroma. *Am. J. Dermatopathol.* 1988; **10**; 430–435.
6. Bart RS, Kamino H, Waisman J, Lindner A, Colen S. Carcinoid tumour of the skin: report of a possible primary case. *J. Am. Dermatol.* 1990; **22**; 366–370.

Mucinous cystadenocarcinoma of the breast showing sulfomucin production

Sir: Mucinous cystadenocarcinoma (MCA), a rare carcinoma of the breast, was designated by Koenig and Tavassoli in 1998.[1] To our knowledge, only five cases of MCA have been reported,[1,2] and the nature of the mucin produced by MCA has never been discussed.

A 74-year-old woman presented with a large breast lump first noticed 2 years previously. Ultrasonography demonstrated a multilocular and lobulated tumour with a focal solid growth, the entire tumour being about 100 mm in greatest diameter. Mastectomy with a dissection of the axillary lymph nodes was performed 2 months after presentation. To date, she remains free of recurrences and metastases without the need for any adjuvant therapies.

Gross inspection revealed a well-demarcated multilocular cystic tumour with fibrous septa, containing abundant bloody and mucinous material. Histologically, cysts of various sizes consisting of cystically

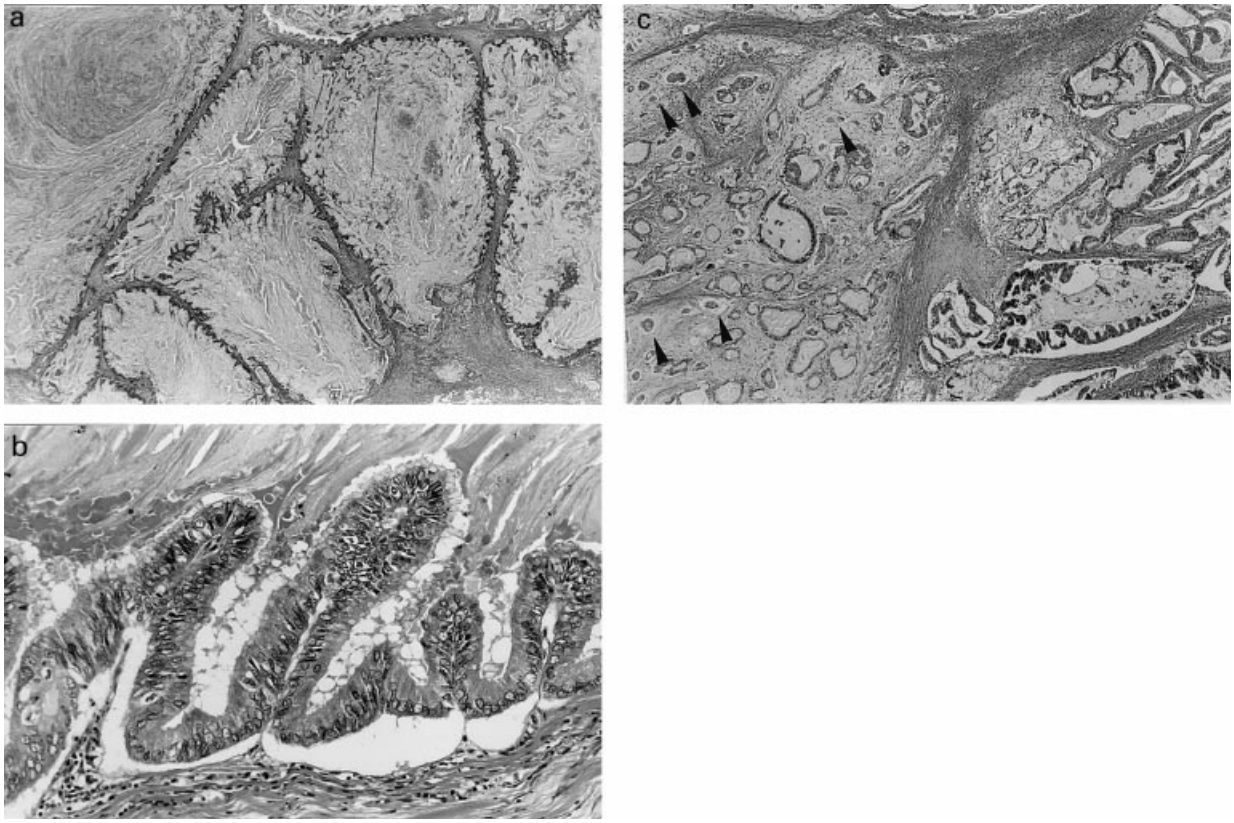

Figure 1. a, Cystically dilated ducts containing abundant mucinous substance (haematoxylin & eosin, original magnification × 20). **b,** Cyst wall lined by tall columnar cells showing papillary proliferation with delicate fibrovascular core (haematoxylin and eosin, original magnification × 150). **c,** Mucinous cystadenocarcinoma of the solid area showing a transition to the features of ordinary mucinous adenocarcinoma (arrowheads) (haematoxylin and eosin, original magnification × 50).

dilated ducts (Figure 1a) were lined by atypical tall columnar cells exhibiting a focal protruding papillary structure with a delicate fibrovascular core (Figure 1b). The whitish solid area consisted histologically of a compact proliferation of rather small glands with scanty intervening stroma. In addition, there was an interstitial infiltration of extracellular mucin in which tumour cell nests were floating, mimicking the histological features of ordinary mucinous carcinoma (Figure 1c, arrowheads) of the breast. Scattered foci of intraductal carcinoma were present around the tumour. There were no metastatic cancer cells in the axillary lymph nodes.

Histochemical positivities for periodic acid–Schiff with or without diastase digestion, alcian blue pH 2.5 and pH 1.0 (Figure 2a), and mucicarmine stain were identified in the cytoplasm of the tumour cells. In the solid area, the high iron diamine–alcian blue pH 2.5 stain (Figure 2b) clearly demonstrated the presence of both sulfomucin- and sialomucin-producing cells (stained black and blue, respectively) within the same tumour clusters. Immunohistochemical positivities for cytokeratin 7 (CK7; Dako, Glostrup, Denmark), carcinoembryonic antigen (Dako), and CA15–3 (Dako) were identified in both cystic and solid areas, while the positive reactions for CA125 (Dako) and CA19–9 (Dako) were focal and mainly within the solid area. Cytokeratin 20 (CK20; Dako), alpha smooth muscle actin (Dako), oestrogen receptor (Immunotech, Marseilles, France) and p53 (Dako) were totally negative. The Ki67 (Immunotech) labelling index was 21.8 in the highest labelling area.

Histologically, MCA is said to be composed of variably sized cystic spaces, resembling mucinous cystadenocarcinoma of the ovary and pancreas, and lined by predominantly bland-appearing columnar mucinous cells showing papillary formation with a delicate fibrovascullar core.[1] The current case showed the following clinicopathological features: (i) multilocular cystic growth containing abundant mucinous substance; (ii) interstitial infiltration partly mimicking the histological features of ordinary mucinous carcinoma;

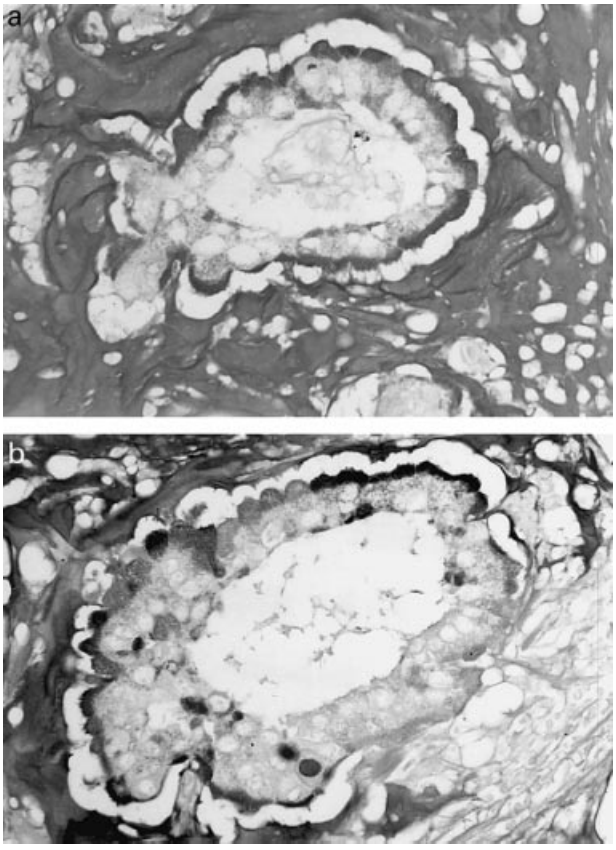

Figure 2. a, Mucin staining of tumour cells in the solid area. a, Alcian blue pH 1.0 showing clear cytoplasmic positivity mainly in the apical portion (original magnification × 250). **b,** High iron diamine–alcian blue pH 2.5 showing the presence of both sulfomucin-producing (black)and sialomucin-producing (blue) cells within the same tumour clusters (original magnification × 250).

(iii) intracytoplasmic mucin with basally located nuclei; (iv) an intracystic papillary structure with a thin fibrovascular core; (v) the rather advanced age of the patient; and (vi) absence of other malignancies. These histological findings would seem to differentiate it from mucocele-like tumours associated with mucinous carcinoma[3] and from cystic hypersecretory duct carcinoma.[2]

The nature and histochemical characteristics of mucin in breast cancers have been investigated previously by employing various mucin stains.[4,5] The presence of sulfomucin production in mucinous carcinoma, mucocele-like tumours, or normal breast tissue has never before been reported,[5] the mucins produced by mucinous carcinoma having been charcterized as neutral mucin and sialomucin.[5] The only breast carcinomas that may produce sulfomucin are lobular carcinomas.[4] Hence, the current case may be distinctive by virtue of its sulfomucin production as well as by its morphological features. However, immunoreactivity for CK20, which is often present in gastrointestinal tumours or mucinous ovarian tumours,[6] was not detected.

H Domoto[1,2]
S Terahata[3]
T Yamazaki[1]
K Sato[1]
H Takeo[1]
S Tamai[1]
[1]*Department of Laboratory Medicine, National Defense Medical College Hospital, Tokorozawa,*
[2]*Japan Maritime Self-Defense Force Undersea Medical Center, Yokosuka and*
[3]*Toami Municipal Hospital, Tonami, Japan*

1. Koenig C, Tavassoli FA. Mucinous cystadenocarcinoma of the breast. *Am. J. Surg. Pathol.* 1998; **22**; 698–703.
2. Rosen PP, Scott M. Cystic hypersecretory duct carcinoma of the breast. *Am. J. Surg. Pathol.* 1984; **8**; 31–41.
3. Fisher CJ, Millis RR. A mucocoele–like tumour of the breast associated with both atypical ductal hyperplasia and mucoid carcinoma. *Histopathology* 1992; **21**; 69–71.
4. Gad A, Azzopardi JG. Lobular carcinoma of the breast: a special variant of mucin secreting carcinoma. *J. Clin. Pathol.* 1975; **28**; 711–716.
5. Hanna WM, Corkill M. Mucins in breast carcinoma. *Hum. Pathol.* 1988; **19**; 11–14.
6. Moll R, Löwe A, Laufer J, Franke WW. Cytokeratin 20 in human carcinomas. A new histodiagnostic marker detected by monoclonal antibodies. *Am. J. Pathol.* 1992; **140**; 427–447.

Solitary Langerhans cell histiocytosis in association with primary biliary cirrhosis

Sir: In reference to the recent report of localized hepatic Langerhans cell histiocytosis (LCH) by Cavazza *et al.*[1] we also have seen two cases of localized LCH of the liver in the absence of disseminated disease.

The first case was that of a 34-year-old man investigated for vague but persistent complaints of abdominal pain. Extensive investigations, including upper and lower gastrointestinal imaging, endoscopy and biopsy were normal. At investigative laparotomy a solitary subcapsular liver nodule measuring 6 mm in

diameter was found and biopsied. Microscopy revealed a well-defined collection of histiocytic cells with convoluted nuclear outline and watery cytoplasm. They were interspersed with a dense infiltrate of eosinophils.

The second case was also found incidentally in a liver removed from a 39-year-old woman undergoing a liver transplant for primary biliary cirrhosis diagnosed on liver biopsy and elevated antimitochondrial antibody titre. The liver weighed 1690 g and on slicing was cirrhotic with several dominant nodules. Microscopic examination of the liver showed both micro- and macronodular cirrhosis with ductopenia. There was moderate to severe chronic inflammation of the fibrous septa with granulomas in portal tracts and within regenerative nodules and the appearances were those of stage 4 primary biliary cirrhosis. One of the dominant nodules sampled was subcapsular, measuring 7 mm in diameter, and on histology was composed of a collection of histiocytic cells, similar to those seen in the first case, again interspersed with numerous eosinophils (Figure 1).

On immunohistochemistry the histiocytic cells of both nodules were positive for S100 (Figure 2.). Sufficient material for electron microscopy was available from case 2, and Birbeck granules were identified in the cytoplasm of the histiocytic cells. The findings in each case were compatible with a diagnosis of a solitary eosinophilic granuloma/isolated Langerhans cell histiocytosis (LCH) in the liver. In the both cases there was no evidence of LCH elsewhere in the liver or of systemic disease at operation or on follow up (four years in the case 1 and 6 months in case 2).

Langerhans cells are potent antigen-presenting cells derived from stem cells in the bone marrow. Secretory products include interleukin-1 and prostaglandin E2 and in addition Langerhans cells stimulate T-cells to produce interleukin 2 and gamma interferon. It may be that some of the pathological effects of LCH may be secondary to an abnormal cytokine milieu. The nature of the cellular proliferation is controversial though recent data has suggested it may be a clonal disorder.[2]

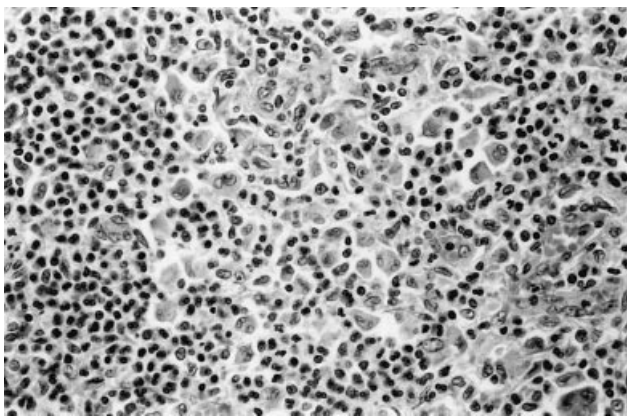

Figure 1. Subcapsular nodule formed of epithelioid cells with folded cleaved nuclei and numerous eosinophils (haematoxylin and eosin).

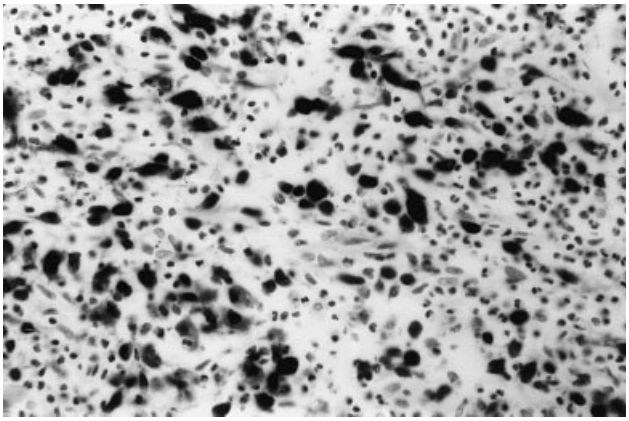

Figure 2. Epithelioid cells with diffuse staining for S100 (haematoxylin counterstain).

The disease may take the form of a solitary granuloma or of systemic disease. It is most commonly seen in children where it is more often a systemic disease, and the liver is commonly involved.[3] The pattern of liver involvement by systemic LCH can take several forms including cirrhosis, granulomas in the parenchyma and portal tract and proliferation of Langerhans cell in the sinusoids.[4–6]

It is rarely seen in adults where it usually involves only one to three organs. Solitary disease has been described in several sites including the bone, lymph nodes, lung, thymus, skin and gastrointestinal tract. Isolated liver involvement by LCH is considered rare[7,8] with only two cases of a single lesion of the liver previously reported.[1,9]

Our cases are similar to that described by Cavazza *et al.* in that the lesions were solitary and subcapsular. This is in contrast to the pattern of involvement described in other cases in the literature, which were either multinodular or associated with bile ducts. Thus, our cases together with that of Cavazza *et al.* highlight two important issues.

First, the presence of solitary nodules of LCH in the liver may not be as uncommon as previously thought. Second, their subcapsular location means that they may be identified at laparotomy and mistaken for metastatic disease. Thus it is important that pathologists are aware of this entity, especially

when assessing intraoperative frozen sections of solitary liver nodules.

A J Rice
J I Wyatt
Department of Histopathology,
St. James's University, Hospital,
Leeds, UK,

1. Cavazza A, Pasquinelli G, Carlinfante G *et al.* Nodular Langerhans cell histiocytosis of the liver in an adult with colonic adenocarcinoma. *Histopathology* 1999; **34**; 273–275.
2. Willman CL, Busque L, Griffith BB *et al.* Langerhans' cell Histiocytosis (Histiocytosis X) — A clonal proliferative disease. *N Engl. J. Med.* 1994; **331**; 154–160.
3. Avery ME, McAfee JG, Guld HG. The course and prognosis of reticuloendotheliosis (eosinophilic granuloma. Schuller-Christian disease and Letterer-Siwe disease): a study of forty cases. *Am. J. Med.* 1957; **22**; 636–652.
4. Heyn RM, Hamoudi A, Newton WA Jr. Pretreatment liver biopsy in 20 children with histiocytosis X: a clinicopathological correlation. *Med. Pediatr Oncol.* 1990; **18**; 110–118.
5. Favara BE. The pathology of 'histiocytosis'. *Am. J. Pediatr Hematol. Oncol.* 1981; **3**; 45–56.
6. Favera BE, McCarthy RC, Meirau GW. Histiocytosis X. *Hum Pathol* 1983; **14**; 663–676.
7. Levy S, Capron D, Joly JP *et al.* Hepatic nodules as single organ involvement in an adult with Langerhans cell granulomatosis. A case report. *J. Clin. Gastroenterol.* 1998; **26**; 69–73.
8. Foschini MP, Milandri GL, Dina RE *et al.* Benign regressing histiocytosis of the liver. *Histopathology* 1995; **26**; 363–366.
9. Finn LS, Jaffe R. Langerhans cell granuloma confined to bile duct. *Paed. Pathol. Lab. Med.* 1997; **17**; 461–468.

Periurethral glomangiomyoma in women: case report and review of the literature

Sir: A periurethral glomangiomyoma is exceedingly rare; only a few cases have been reported. We describe a case of a glomangiomyoma in the periurethral region and review published reports of glomus tumour in the external genitalia. The glomus tumour is a benign soft-tissue neoplasm in which the cells resemble modified smooth muscle cells of the normal glomus body. Glomus tumours occur usually in the distribution of the normal glomus body; only rarely can they develop in sites where normally glomus bodies are sparse or absent. Exceptionally, the glomus tumour has also been found in the uterine cervix, vagina, penis, rectum and mesentery. Only few of such tumours have been reported in the female external genitalia: two arising in the vulva, two in the clitoris, and one in the labia. To our knowledge there is a single report of a periurethral vulval glomus tumour.

A 26-years-old woman from Nigeria with a history of a right benign ovarian cyst and a uterine leiomyoma presented with a painful 5-mm nodule located in the submucosal tissue of the vulva near the urethra. A 5-mm firm tan-grey mass diameter, with a smooth outer surface was excised from the left of the urethra.

Histological examination revealed that the tumour had a well-defined margin with a thin fibrous pseudocapsule. The tumour cells were round, regular in shape with a gradual transition from ordinary glomus cells to elongated smooth muscle cells, with a sharply rounded or ovoid nucleus and amphophilic or eosinophilic cytoplasm (Figure 1). The outlines of the cells were not fully appreciated in haematoxylin and eosin routine stained sections but were accentuated with a periodic acid–Schiff stain. The cytoplasm was devoid of glycogen with a minimal fuchsinophilia with Masson trichrome stain. The cells formed nests and sheets that were permeated by a network of thin-walled vessels. The periphery of the tumour had a thin collagenous rim containing small nerves, vessels and smooth muscle. The immunohistochemical studies showed a strong positivity for vimentin and smooth muscle actin but negative staining for desmin, cytokeratin, factor VIII related-antigen. Immunohistochemical stain for S100 protein showed delicate nerve fibres intimately associated with the glomus cells and vascular structures of the tumour (Figure 2)

The distribution and proportion of the three main components of the glomus tumour (vessel, glomus cells and smooth muscle) may vary considerably. According to the relative proportions, they have been divided into three groups: glomus tumour proper, glomangioma and glomangiomyoma. The most common type consists

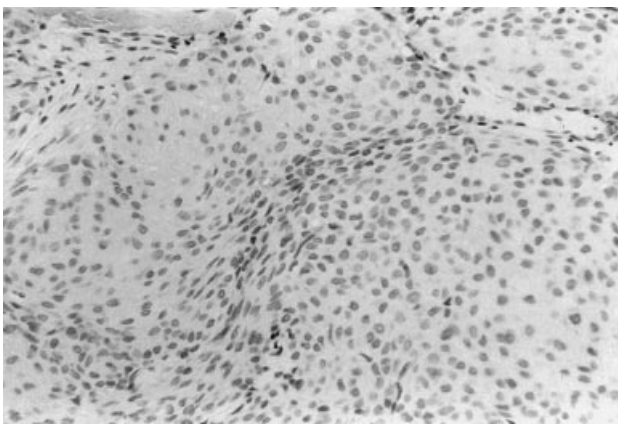

Figure 1. The tumour cells are round with a gradual transition from ordinary glomus to elongated smooth muscle cells (haematoxylin and eosin, × 80).

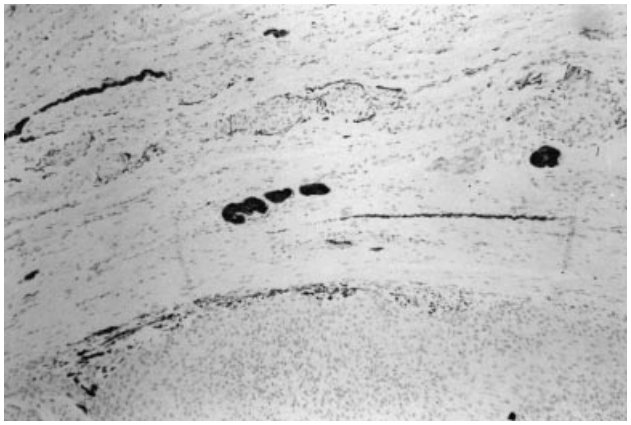

Figure 2. The immunoreactivity for S100 shows delicate nerve fibres associated with the glomus cells and vascular structures of the tumour (S100, × 31).

of capillary-size vessels enclosed by nests of small, uniform glomus cells, often arranged in concentric rows. Some glomus tumours, referred to as glomangiomas, display dilated vessels similar to a cavernous haemangioma. More rarely, glomangioma includes a prominent component of mature smooth muscle cells referred to as glomangiomyoma.[1] Glomus tumours arising in the female external genitalia region are extremely rare. Katz *et al.*[2] and Kohorn *et al.*[3] each describe a vulvar glomus tumour, Enzinger and Weiss describe a labial tumour, and Jagadha *et al.*[4] reported a tumour involving the clitoris. Sonobe *et al.*[5] describe two additional glomus tumours occurring in the female external genitalia: one involved the clitoris and the other arose in the periurethral area of the vulva. The finding of a glomus tumour in sites so unusual, as in the case we describe, may requires distinction from other tumours including haemangiopericytoma because of the arrangement of tumour cells around the many branching vessels. However glomus cells are generally closely packed and more consistently round or polygonal. Immunocytochemical analysis resolves the differential diagnosis because the glomus cells contain considerable amounts of smooth muscle myofilaments that give positive immunostaining for smooth-muscle actin. Haemangiopericytoma cells rarely contain myofilaments and actin immunoreactivity is seen in only rare cases and, when present, is usually focal and weak. Another lesion that might be considered in the histological differential diagnosis is glomangiopericytoma characterized by histological features that are intermediate between glomus tumour and haemangiopericytoma such as prominent branching, medium and small vessels lined by a single row of endothelial cells, surrounded by epithelioid cells with a glomoid appearance.[6]

S Blandamura
G Florea
M Brotto
R Salmaso
L Castellan[1]

Dipartimento di Scienze Oncologiche e Chirurgiche Universita' Degli Studi di Padova,
[1]*Dipartimento di Ostetricia e Ginecologia, Universita' Degli Studi di Padova, Italy*

1. Ninfo V, Chung EB, Cavazzana AO. *Tumors and Tumorlike Lesions of Soft Tissue*, 2nd edn. New York, Edinburgh, London, Melbourne, Tokyo: Churchill Livingstone, 1991: 137–140.
2. Katz VL, Askin Fb Bosch BD. Glomus tumor of the vulva: a case report. *Obstet. Gynecol.* 1986; **67** (3 Suppl.); 43S–45S.
3. Kohorn EI, Merino MJ, Goldenhesh M. Vulvar pain and dispareunia due to glomus tumor. *Obstet. Gynecol.* 1986; **67** (3 (Suppl.); 41S–42S.
4. Jagadha V, Srinivasan K, Panchachara P. Glomus tumor of the clitoris. *NY State J. Med.* 1985; **85**; 611.
5. Sonobe H, Ro JY, Ramos M *et al.* Glomus tumor of the female external genitalia: a report of two case. *Int. J. Gynecol. Pathol.* 1994; **13**; 359–364.
6. Granter SR, Badizadegan K, Fletcher CD. Myofibromatosis in adults, glomangiopericytoma, and myopericytoma: a spectrum of tumors showing perivascular myoid differentiation. *Am. J. Surg. Pathol.* 1998; **22**; 513–525.