

# The ACE (Antegrade Continence Enema) Procedure

Padraig S. J. Malone

## INTRODUCTION

Since its development in 1989, the ACE procedure has become widely accepted as a valuable addition to the therapeutic regimens available for treating intractable faecal incontinence associated with conditions such as myelomeningocele and anorectal malformations. Thousands of patients around the world have undergone ACE procedures with success rates in excess of 80% reported.

The original procedure described disconnecting the appendix from the caecum, amputating its tip, reversing it, re-implanting it into a submucosal tunnel on the anterior wall of the caecum to produce a continence mechanism, and the stoma was usually sited in the right iliac fossa. Since the original description numerous modifications have been proposed and introduced, so it is now incorrect to talk about the ACE procedure and it would be more accurate to use the term *ACE principle*.

In this chapter the author's current approach is described.

Because a failure rate of 20% exists, it is useful to perform an initial therapeutic trial of antegrade washouts, by minimally invasive means, before proceeding to the definitive procedure. A colonic catheter can be inserted percutaneously, under either radiological or colonoscopic control (as one would perform a percutaneous endoscopic gastrostomy, PEG), into any part of the large bowel and use it to administer the enemata. If constipation is the major problem the catheter is best placed in the distal descending colon but in the absence of constipation the caecum remains the best site. If the washouts are successful the patient has a choice: to keep the catheter, exchange it for a colonic button (identical to a gastrostomy button), or have a conduit constructed at open surgery. In the author's experience most patients will ultimately opt for a conduit, as there is a

tendency for leakage of flatus, and stool or washout fluid to occur around the side of the buttons. Using this approach it is also possible to test in which part of the colon the conduit will work best. Increasing numbers of conduits are now placed in the distal descending colon because the time taken to perform the washout is reduced.

In practical terms there are now two types of ACE, the original *caecal ACE* and the new *left colonic ACE*. For the caecal ACE, many surgeons now advocate simply amputating the tip of the appendix and bringing the open end on to the abdominal wall without constructing any continence mechanism. This is being increasingly performed laparoscopically. However, in the author's experience, if no continence mechanism is constructed, leakage of stool or washout fluid occurs in a significant number of cases and this approach is not recommended. The recommended technique for creating the continence mechanism has changed, however. It is no longer necessary to disconnect the appendix and the *in situ* technique will be described here. If the appendix is absent, required for a simultaneous Mitrofanoff procedure or if a left colonic ACE is being constructed, a tubularized small bowel tube using the Monti procedure is recommended and will be described. As the incision will depend on whether it is a caecal, left colonic or an ACE performed in combination with a bladder reconstruction no specific recommendations will be made. The surgeon can choose his or her own preferred approach.

It is recommended that patients receive broad-spectrum antibiotic prophylaxis and undergo a full-bowel preparation pre-operatively, as it is helpful to have the colon empty when the washouts are first commenced.

### Figure 59.1, 59.2

The patient is placed supine on the operating table. The caecum is mobilized, the tip of the appendix is amputated and a stay suture is inserted in the open end to apply traction. A 10–12 Ch catheter is passed via the appendix into the caecum, to confirm that it is catheterizable. The stretched mesentery is inspected and fenestrated between the vessels. This allows the caecum to be wrapped around the appendix through the mesenteric windows, to produce the continence mechanism, without compromising the blood sup-

ply. Stay sutures are inserted into the caecum alongside the anterior taenia to keep it under tension whilst a submucosal tunnel is made. The serosa and muscle are initially incised using a diathermy and the trough is widened to expose the submucosa by spreading a mosquito artery forceps as one would perform a pyloromyotomy. It is important that this incision includes the base of the appendix as it allows this area to be buried in the caecum, reducing angulation and making catheterization easier.

### Figure 59.3, 59.4

The appendix is folded along the length of the submucosal tunnel and the caecum is wrapped around it, as one would perform a Nissen fundoplication, to produce the continence mechanism. This is done using an absorbable 4/0 suture. The first suture is placed at the base of the appendix picking up the caecum–appendix–caecum to ensure that the appendix is firmly secured in the tunnel. This prevents movement and kinking and facilitates easy catheterization. Further sutures are progressively placed along the length of the appendix in a similar fashion, bringing the caecal wrap through the mesenteric windows

that were created earlier. The entire appendix is wrapped within the caecum until only a sufficient length is left to bring it out through the abdominal wall when the stoma is constructed. The antimesenteric end of the appendix is spatulated to allow a V-flap of skin to be inlaid during construction of the stoma to reduce the incidence of stomal stenosis. It is important to anchor the caecum to the posterior aspect of the anterior abdominal wall using absorbable sutures so it is not hanging on the appendix and at risk of torsion.

Figure 59.1

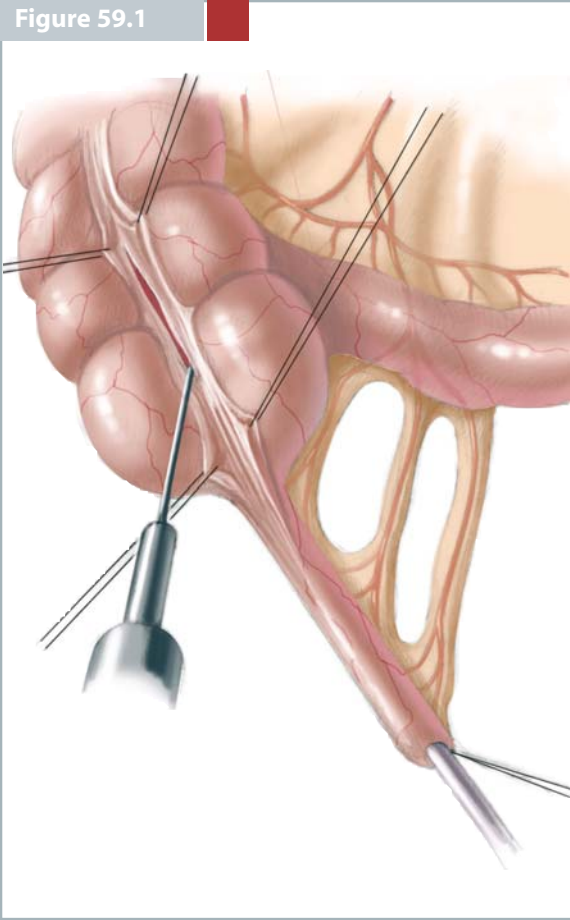


Figure 59.2

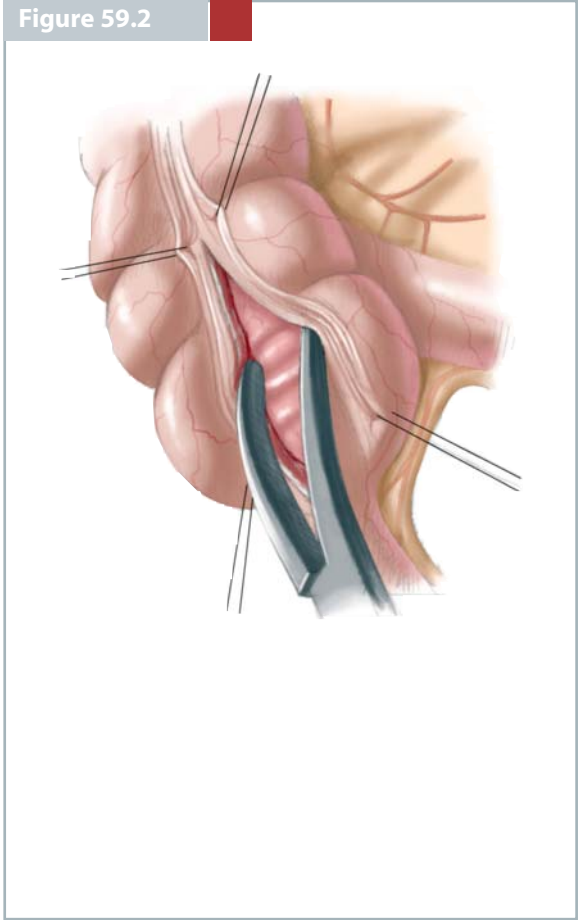


Figure 59.3

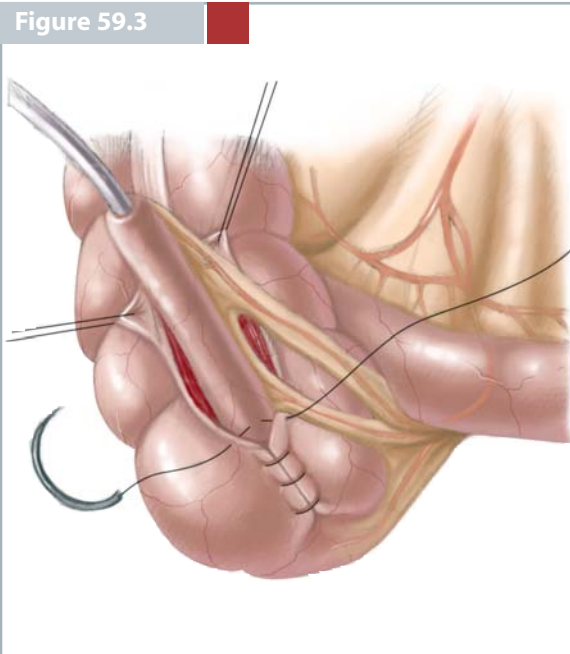
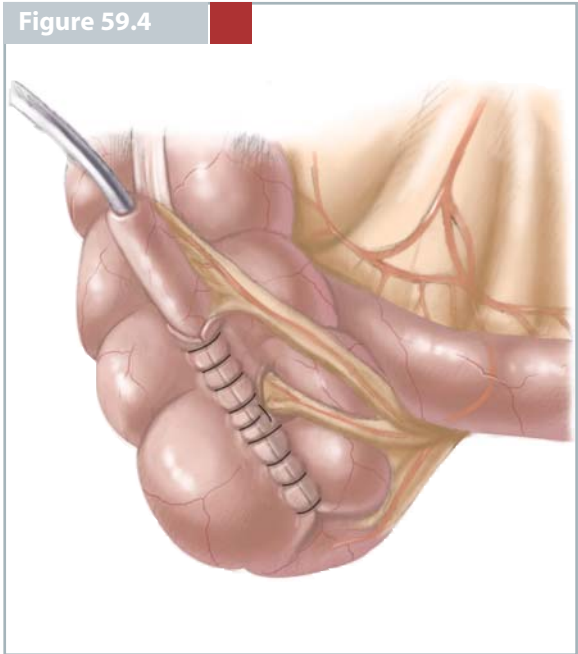


Figure 59.4



**Figure 59.5, 59.6**

The Monti ACE is required when the appendix is absent or required for a Mitrofanoff conduit or when a left colonic ACE is constructed. A 2-cm segment of ileum is isolated on its vascular pedicle. Straight non-crushing bowel clamps are applied to either end of the isolated segment and the bowel is then divided

using a knife. An end-to-end ileal anastomosis is performed using interrupted extramucosal 4/0 absorbable sutures and the mesenteric defect is closed. The bowel is detubularized by opening it along its anti-mesenteric border in the midline using scissors or diathermy.

**Figure 59.7, 59.8**

The Monti tube is constructed using a single layer of interrupted extra-mucosal 6/0 monofilament absorbable sutures over a 12 Ch catheter. Initially it is helpful to place stay sutures at either end and in the middle, in the region of the mesentery to keep the tube straight and under some tension. Care should be taken to ensure that the lumen of the conduit remains symmetrical throughout to avoid subsequent catheterisation difficulties. It is also helpful not to tu-

bularize the conduit all the way to the end where the stoma is to be constructed as this allows for a defect into which a V-flap of skin can be inserted in an attempt to reduce postoperative stomal stenosis.

Following completion of the conduit two segments are left at either side of the mesentery, one for insertion into the submucosal tunnel in the bowel and the other for bringing through the abdominal wall to the stoma.

Figure 59.5

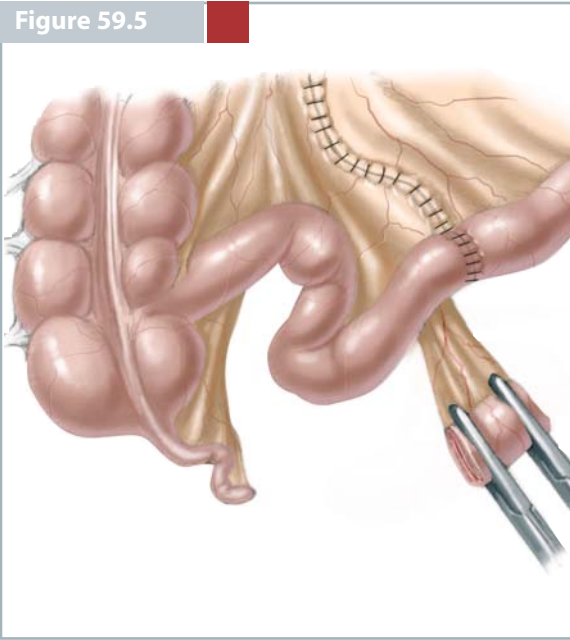


Figure 59.6

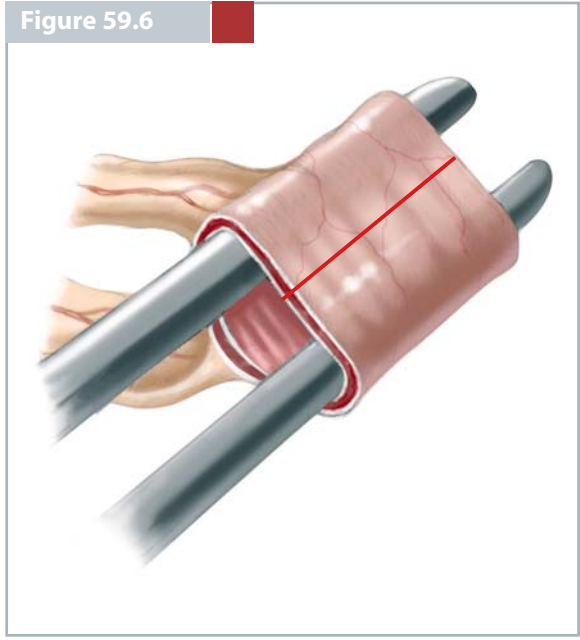


Figure 59.7

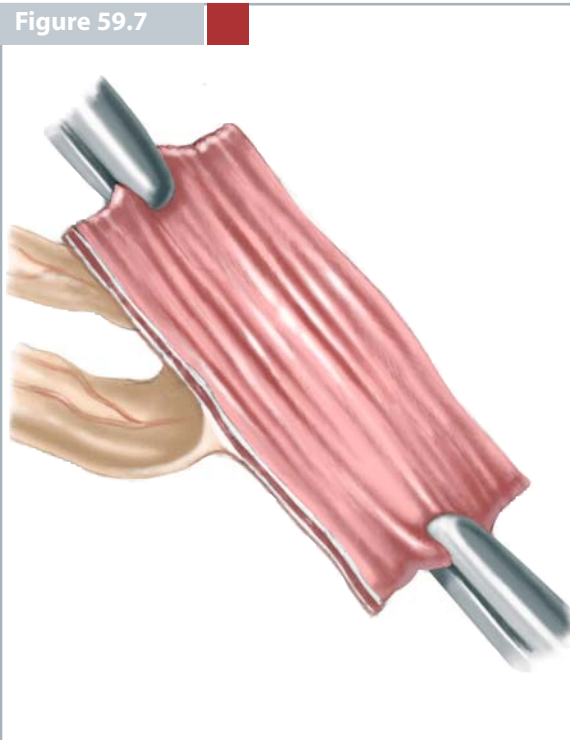
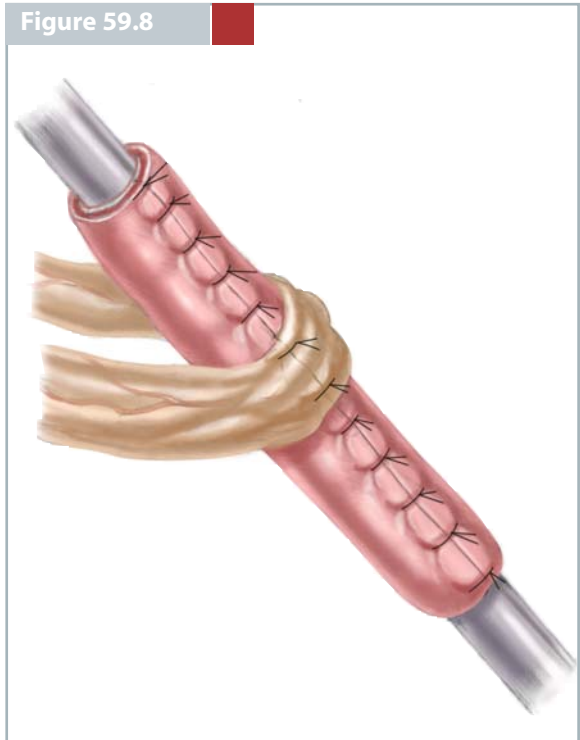


Figure 59.8



**Figure 59.9, 59.10**

The next step is to create the continence mechanism. At least four stay sutures are placed in the colon on either side of a suitably placed taenia. The seromuscular layer is divided using diathermy and the trough created is widened using mosquito artery forceps, until it is sufficiently wide to be able to close it over the Monti tube with no tension (*a*). The mucosa is opened at the end of this trough and the conduit is anastomosed to this, end-to-side fashion, using an absorbable suture (5/0). Following this anastomosis

it is important to check that the conduit remains easy to catheterize. The seromuscular layer is closed over the conduit using a 4/0 absorbable suture picking up each side of the colon and the conduit to ensure that it does not shift in the tunnel (*b*). It is vital to ensure that the vascular pedicle is not compromised during closure of the tunnel. The length of the conduit outside the tunnel should be just long enough to reach the skin of the abdominal wall.

**Figure 59.11, 59.12**

The stoma may be placed at any convenient place on the abdominal wall including the umbilicus. Irrespective of where the stoma is placed a V-flap of skin should be laid into the spatulated end of the conduit. In this chapter the more complex VQC stoma will be illustrated because studies have shown that it has a lower risk of developing stomal stenosis.

The skin flaps are initially marked. It is important to ensure that the centre of the V-flap directly over-

lies the fascial defect through which the conduit is brought. It is also important to ensure that the skin and abdominal wall are stretched at this stage using Kocker's forceps because if they are not the channel for the conduit may not be straight when the abdominal wound is closed. The Q- and V-flaps are then mobilized.

Figure 59.9

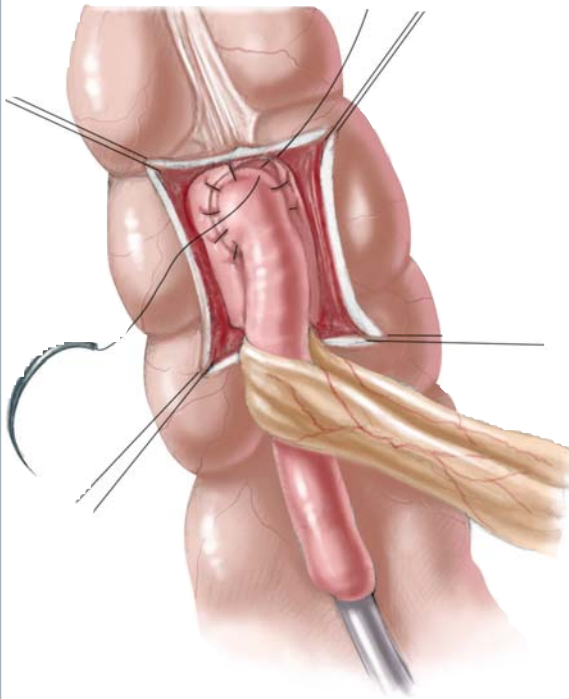


Figure 59.10

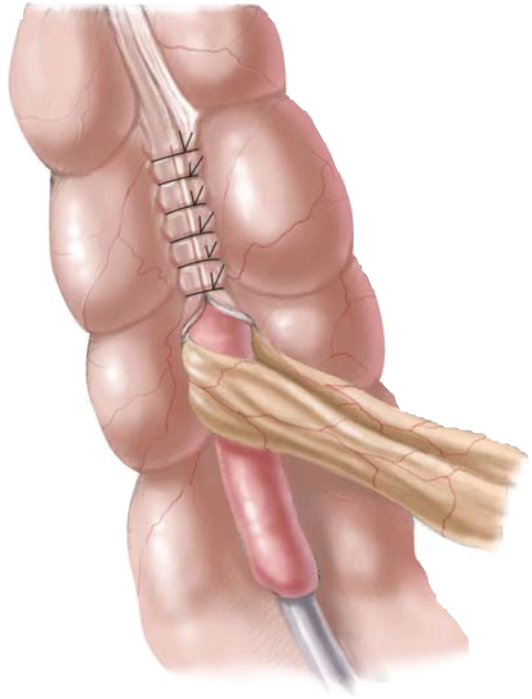


Figure 59.11

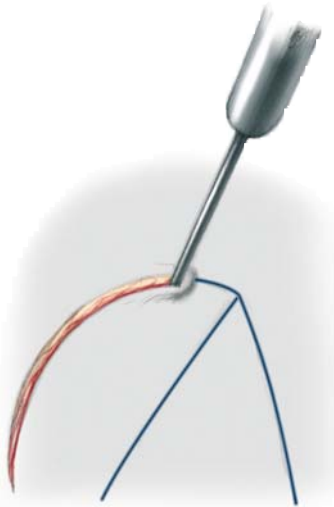
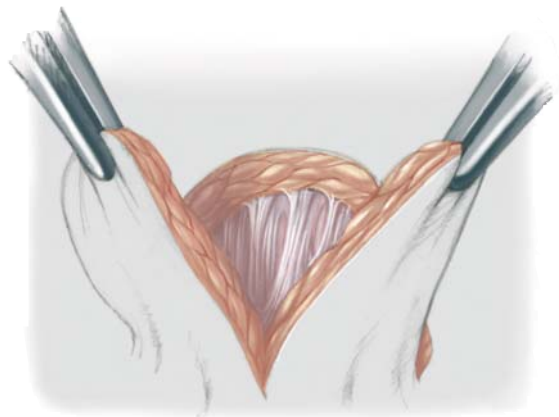


Figure 59.12



**Figure 59.13, 59.14**

The V-flap is sutured into the spatulated end of the conduit using an absorbable suture. The author favours interrupted 5/0 Maxon sutures as the needle is tapered, atraumatic and strong and goes through the skin easily; at the same time it does not damage and pull through the conduit. The knots are placed on the outside so they will not snag on the catheter as it is passed to test the conduit and stoma during its construction. It is vital to test the ease with which the conduit catheterizes after each separate step of its construction. The V-flap is sutured until there is

enough conduit left to anastomose the edge of the Q-flap to. The Q-flap is rolled over the anterior aspect of the conduit, anastomosing its inferior edge to the V-flap while its medial edge is anastomosed to the anterior margin of the conduit. This is best done with a 12–14 Ch catheter in place. The Q-flap is anastomosed to the whole of the anterior edge of the conduit and the superior defect between the Q and V-flaps is also closed with interrupted 5/0 absorbable sutures. This then leaves a C-shaped skin defect.

**Figure 59.15**

This defect is usually easy to close without tension by running a simple subcuticular 5/0 absorbable suture on a cutting needle. If there are abdominal scars following previous surgery it may be necessary to perform a relieving Z-plasty to facilitate tension-free closure.

The catheter is left in place for 4 weeks prior to the commencement of intermittent catheterisation but washouts can commence as soon as the patient has recovered from the post-operative ileus usually on day 5.



Figure 59.13

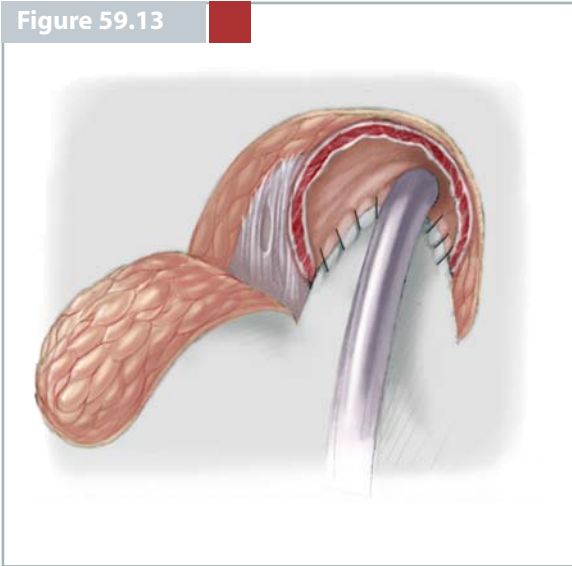


Figure 59.14

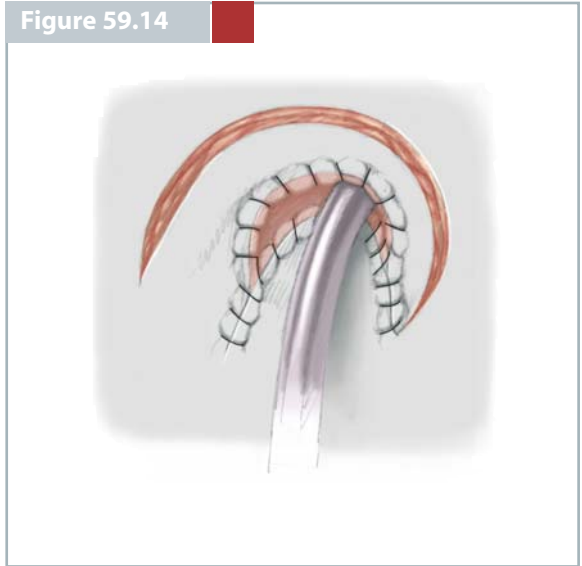
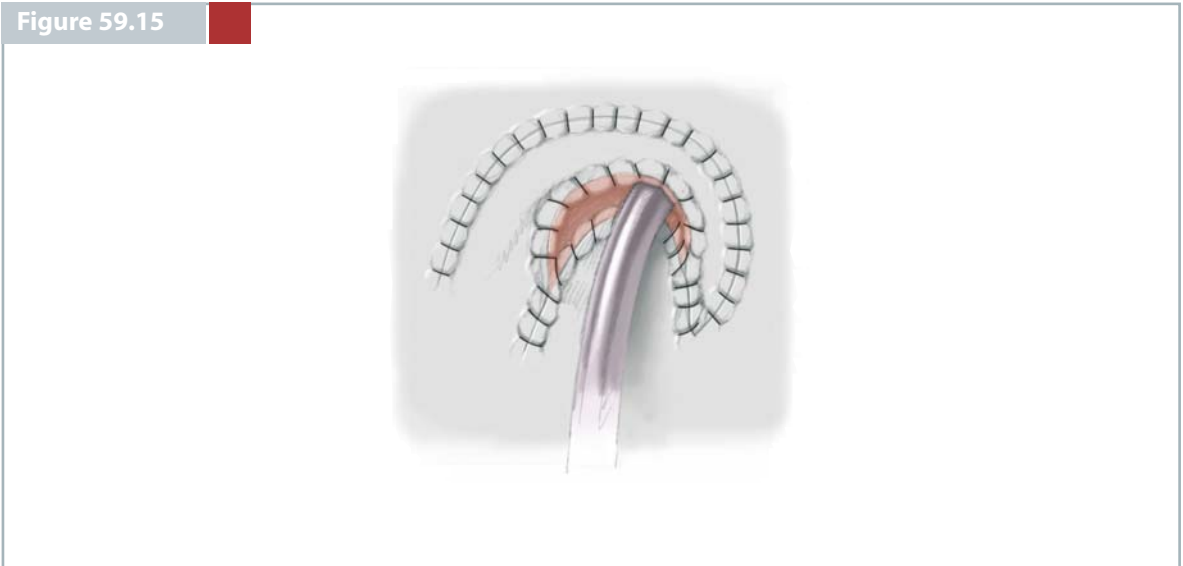


Figure 59.15



## CONCLUSION

All conservative measures should be tried first before resorting to the ACE procedure. The underlying diagnosis is important as it influences the success rate. In the Southampton experience, patients with a neuropathic bowel or an anorectal malformation had a success rate of 73%, compared with 38% for patients with chronic idiopathic constipation. The age at operation is also important. In Southampton there was a 70% failure rate for patients under 5 years of age compared with 24% for those aged over 5 years. This difference was independent of the underlying diagnosis and probably reflected the inability of a child under 5 years of age to sit on a toilet for up to 1 h before emptying is complete.

Patient and caregiver motivation is vital in determining success. A lack of compliance with the washout regimen was a major contributory factor to failure in a number of series. Detailed pre-operative counselling and continued post-operative support, ideally provided by a nurse specialist, are essential to ensure adequate and continued motivation, without which the ACE is doomed to failure. It is an advantage to introduce the potential patient to a child and family with a functioning ACE prior to the surgical procedure. The initial therapeutic trial that has recently been introduced by the use of the percutaneously placed tube is a significant step forward as it enables the surgeon to test the family's motivation and their ability to cope with the regimen before proceeding to the definitive procedure. It also provides the opportunity of testing a number of washout regimens to see which one suits best.

The washout regimen is usually established by trial and error and it can take up to 6 months before a stable situation is reached. There are numerous different washout regimens in use around the world. In Southampton a phosphate enema is generally used. Initially 50 ml enema solution is diluted up to 100 ml with water and rapidly instilled and followed with approximately 500 ml water (in the original description saline was used but this is not necessary and it is

safe just to use tap water). The regimen is adjusted depending on the response; increasing/reducing the volume of phosphate and or water till a stable situation is reached. Care must be taken when using the phosphate as toxicity can occur if the enema is retained. Some units do not use a stimulant of any kind, simply relying on the washout using large volumes of water.

Several problems have been encountered during the establishment of the ACE. The most common is pain during the washout, which is reported in up to 60% of patients. This usually settles spontaneously during the first 3 months but can be helped by reducing the concentration of the phosphate, reducing the rate of the infusion or using an antispasmodic prior to the enema (Colofac, Solvary, UK). Despite regular washouts patients may still become constipated and this also produces pain and it should always be excluded. One of the other problems encountered is the time taken for the enema to pass and achieve a result and this has been a significant contributory factor to failure. The placement of the conduit in the distal descending colon has improved this situation considerably, with patients in whom the standard caecal ACE did not work achieving excellent results with the left colonic ACE.

The commonest operative complication encountered is stomal stenosis, which occurs in up to 30% of cases with half of these patients requiring revisional surgery. The VQC stoma described in this chapter has considerably reduced the incidence of stenosis. The site of the stoma and the type of conduit used makes no difference to the stenosis rate.

Despite all the problems associated with the ACE there is little doubt that it can achieve social continence and avoid a colostomy in patients with intractable incontinence, a situation that did not exist prior to the development of the ACE. It has also been shown to significantly improve patient's quality of life.

## SELECTED BIBLIOGRAPHY

- Curry JL, Osborne A, Malone PSJ (1999) The MACE procedure: experience in the United Kingdom. *J Pediatr Surg* 34: 338–340
- Koyle MA, Malone PSJ (2001) The Malone antegrade continence enema (MACE). In: King LR, Belman AB, Kramer SA, (eds) *Clinical pediatric urology*, 4th edn. Martin Dunitz, London, Chap 18, pp 529–536
- McAndrew HF, Malone PSJ (2002) Continent catheterisable conduits. *BJU Int* 89: 86–89
- Shankar KR, Losty PD, Kenny SE, Booth JM, Turnock RR, Lamont GL, Rintala RJ, Lloyd DA (1998) Functional results following the antegrade continence enema procedure. *Br J Surg* 85: 980–982
- Wedderburn A, Lee RS, Denny A, Steinbrecher HA, Koyle MA, Malone PS (2001) Synchronous bladder reconstruction and ACE procedure. *J Urol* 163: 2392–2393