

# Single Cannula Technique and Robotic Telescopic Assistance in Infants and Children Who Require Laparoscopic Nissen Fundoplication

By Daniel J. Ostlie, Kelly A. Miller, Ronald K. Woods, and George W. Holcomb III  
Kansas City, Missouri

**Background/Purpose:** Laparoscopic Nissen fundoplication (LNF) is being utilized more extensively in the management of symptomatic gastroesophageal reflux disease in infants and children. The traditional approach utilizes 5 3- to 5-mm cannulas for telescope and instrument access to the peritoneal cavity. The purpose of this study is to report the technique and document the results using a single 5-mm umbilical cannula for LNF, stab incisions for placement of the instruments, and robotic telescope assistance.

**Methods:** From November 1999 through March 2002, 154 patients underwent LNF by the senior author for pathologic gastroesophageal reflux disease. All operations were performed with a single 5-mm umbilical cannula through which a 4- or 5-mm telescope was placed for operative visualization. Four stab incisions were made through the upper/lateral abdominal wall under direct visualization avoiding the epigastric vessels. Through these stab incisions, instruments were inserted into the peritoneal cavity. The maximum insufflation pressure was 15 mm Hg in all cases. The ability to perform the procedure in the absence of additional operative cannula placement, complications during instrument inser-

tion, the ability to maintain adequate pneumoperitoneum, the patient's age, weight, operating time, and the addition of a gastrostomy were recorded.

**Results:** All but one of the 154 LNFs were completed successfully using this technique. The mean age at operation and mean operating time was 23.9 months (range, 3 weeks to 180 months) and 91 minutes (31 to 160 minutes), respectively. Patients weight ranged from 2.4 to 57 kg (mean, 10.4 kg). Gastrostomies were placed in 52 cases. There were no complications associated with the stab incisions or insertion of the operative instruments through the abdominal wall. Pneumoperitoneum was maintained adequately in all cases.

**Conclusions:** LNF can be performed safely and effectively with a single umbilical cannula. We recommend its use for pediatric patients who require LNF.  
*J Pediatr Surg 38:111-115. Copyright 2003, Elsevier Science (USA). All rights reserved.*

INDEX WORDS: Fundoplication, robotic assistance, cannula placement.

MINIMALLY INVASIVE approaches for surgical intervention in infants and children continue to develop both in technical complexity and equipment. Laparoscopic Nissen fundoplication (LNF) is just one example. It is being performed more frequently worldwide by an increased number of pediatric surgeons and, in many institutions, is the preferred approach for the surgical management of gastroesophageal reflux disease (GERD). Usually, the procedure is performed with 5 3- or 5-mm cannulas for instrument and telescope access to the abdominal cavity. In addition to the surgeon, one or 2 individuals are used frequently for assistance and camera management. We report our experience using a single 5-mm cannula and robotic assistance in infants and children undergoing LNF.

## MATERIALS AND METHODS

After obtaining IRB approval, the charts of all patients undergoing LNF by the senior author from November 1999 to March 2002 were reviewed. From November 1999 through May 2000, an assistant at the operating table controlled the operating telescope. AESOP (Computer Motion, Santa Barbara, CA) robotic telescopic control was initiated in May 2000 and has been used in all cases since that time. AESOP is placed in a similar location in all patients regardless of size. The patient is placed at the foot of the bed in the frog leg position or, if too large

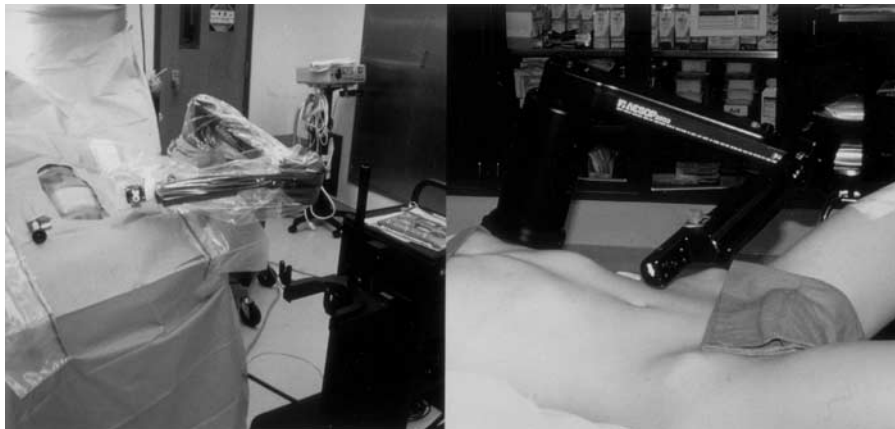
for this position, he or she is placed in the lithotomy position. By attaching AESOP to the left side rail of the table at the level of the patient's left axilla, it is well positioned to allow adequate maneuverability for the assistant's hands (Fig 1). The robot is placed in full tilt with the arm in the 1° down position, which keeps the robotic arm inferior to the operator's hands (Fig 2). The technique utilizing a single umbilical cannula was used in all patients. This 5-mm cannula was introduced into the abdominal cavity under direct vision through a vertical incision in the umbilicus. The abdominal cavity subsequently was insufflated with CO<sub>2</sub> to a maximum pressure of 15 mm Hg. The operating instruments were inserted into the peritoneal cavity via transabdominal wall stab incisions using a No. 11 blade (Beckton-Dickinson, Franklin Lakes, NJ) without utilizing additional cannulas (Fig 3). Four instruments were introduced, 2 in the epigastrium on either side of midline, and one each inferiorly (Fig 4). A standard Nissen fundoplication was performed by dividing the short gastric

*From the Department of Surgery, Children's Mercy Hospital, Kansas City, MO.*

*Presented at the 49th Annual Congress of the British Association of Paediatric Surgeons, Cambridge, England, July 23-26, 2002.*

*Address reprint requests to George W. Holcomb III, MD, Surgeon-in-Chief, Children's Mercy Hospital, 2401 Gillham Rd, Kansas City, MO 64108.*

*Copyright 2003, Elsevier Science (USA). All rights reserved.  
0022-3468/03/3801-0023\$35.00/0  
doi:10.1053/jpsu.2003.50022*



**Fig 1.** AESOP (Computer Motion, Santa Barbara, CA) is connected to the left side rail of the operating table at the level of the patient's axilla. On the left, it is being utilized in a 2-month-old infant, whereas the patient on the right is 13 years old.

vessels with electrocautery. The crura were identified and a retroesophageal window created. An adequate length of esophagus was mobilized into the abdominal cavity to allow for a tension-free fundoplication. The crura were reapproximated posteriorly using a single, or occasionally, 2 silk sutures. To attempt to prevent transmigration of the fundoplication into the mediastinum, we recently have begun to suture the esophagus to the crura at the 12 o'clock, 3 o'clock, and 9 o'clock positions using 2-0 or 3-0 silk sutures. The esophagus was calibrated using an intraesophageal bougie and a Nissen fundoplication created around the bougie using three interrupted silk sutures (Fig 5). All sutures were tied intracorporally. If indicated, a gastrostomy was placed using the U-stitch technique (Fig 5).<sup>1,2</sup> After withdrawal of the instruments and telescope, the umbilical fascia was closed using a 3-0 or 2-0

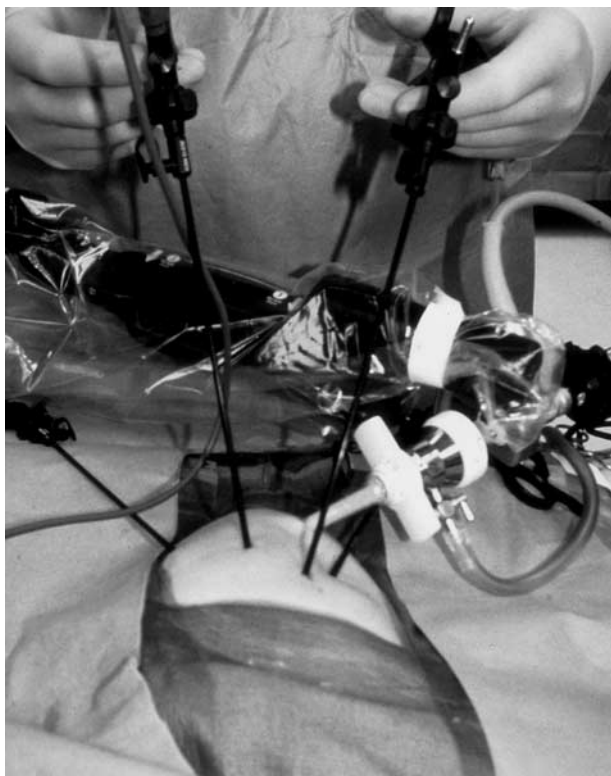
absorbable suture, and the umbilical skin was closed with a 5-0 absorbable suture. The stab incisions were closed with Steri-Strips (3M Company, St Paul, MN)

Data collected retrospectively included age at operation, weight, pneumoperitoneum pressure, bougie size, presence of gastrostomy, laparoscopic completion, operating time, and cannula and instrument complications.

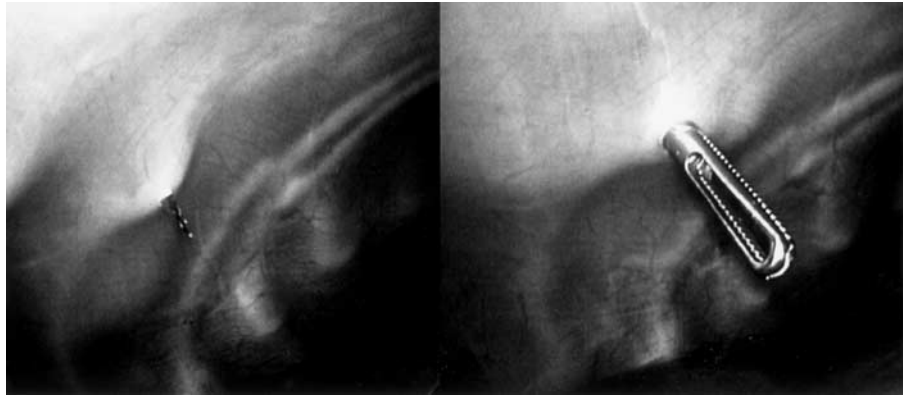
## RESULTS

One hundred fifty-four patients underwent LNF by the senior author during the study period and make up the study group. All operations were completed laparoscopically with the exception of a single case, which was converted to an open operation after insertion of the umbilical cannula because of inadequate oxygenation and ventilation secondary to the pneumoperitoneum. The patient's ages ranged from 3 weeks to 15 years with a mean age of 24.5 months at the time of operation. The mean weight was 10.6 kg for the group (range, 2.4 kg to 50 kg). The bougie size ranged from 20F to 56F and varied according to patient weight.

The average operating time for the entire group was 90.1 minutes. Analysis of the operating duration over the study period found a decrease in times, which became statistically significant in association with robotic assistance (Table 1). The study period was divided into 4 groups. Group A consisted of patients undergoing LNF before the use of AESOP (October 1999 through April 2000). Group B (May 2000 through December 2000), C (January 2001 through May 2001), and D (June 2001 through March 2002) were comprised of patients undergoing LNF with AESOP robotic assistance over the remainder of the study period. *T* test statistical analysis identified significantly shorter operating times when group A was compared with group C as well as group D ( $P < .05$ ). There was no statistical difference between groups A and B. All transabdominal wall stab incisions were performed under direct telescopic vision. There were no complications associated with either the stab incisions or the introduction of instruments in the ab-



**Fig 2.** This photograph, taken from the head of the operating table, shows how the surgeon works easily around AESOP, which is positioned inferior to the instruments in this 6-week-old infant.



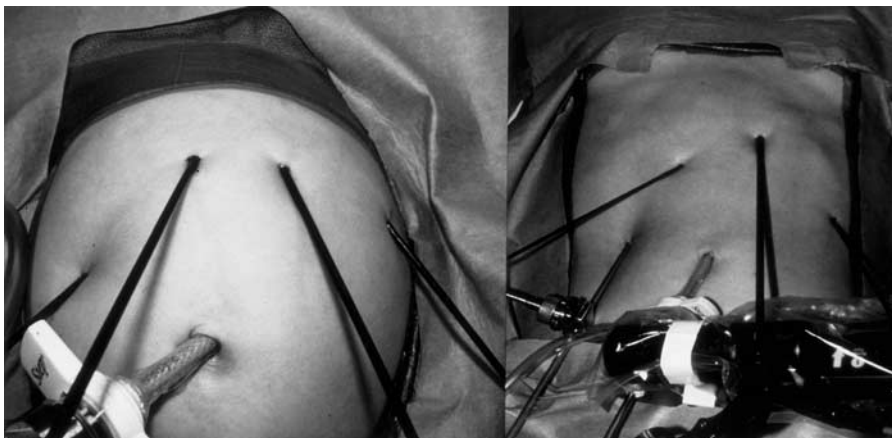**Fig 3.** This operative photograph depicts the No. 11 blade entering the peritoneal cavity on the left. On the right, the knife has been withdrawn and the liver retractor introduced directly through the abdominal wall.

sence of cannulas. Maximal pneumoperitoneum pressure was 15 mm Hg and, apart from the one patient mentioned above, there were no difficulties associated with maintaining pneumoperitoneum using the single cannula technique. All patients have been followed up clinically. Three patients have required a second LNF for transmigration of the fundoplication into the thorax.

#### DISCUSSION

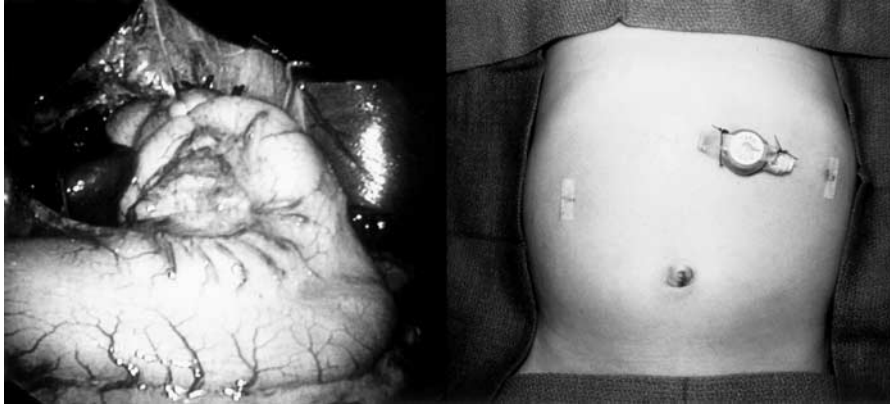
The traditional approach to LNF incorporates the use of an operating surgeon with one or 2 assistants for surgical retraction and operation of the telescope. The use of robotic assistance for telescopic control has developed in recent years,<sup>3,4</sup> and complete telerobotic surgery, although in its infancy, is being reported.<sup>5-7</sup> Additionally, the use of robotic telescopic control has been compared with traditional human control in various studies with conflicting results regarding its efficacy in relation to decreasing operating times. Jhonet<sup>8</sup> and Geis et al<sup>9</sup> separately reported the use of robotic telescopic control and found shorter operating times with its use. Vara-Torbeck et al<sup>10</sup> did not identify a difference in operating times utilizing a voice-activated robotic assistant when compared with a human assistant. In our study, we clearly show a decrease in the operating times for

LNF in infants and children. Several explanations can be postulated for this finding. Numerous investigators have agreed that the camera image from robotically controlled telescopes is steadier with significantly less motion artifact than a human controlled camera. This improved image results in more efficient surgical movements and timely technical completion. Another possible explanation is apparent when one considers the field of vision required for adult abdominal laparoscopic procedures in relation to the field in infants and children. Our patient population has significantly smaller abdominal viscera and, therefore, a smaller esophagus, stomach, and esophageal hiatus. This operative field can be displayed almost in its entirety throughout the majority of the LNF. Human telescopic assistance in this small field is not nearly as efficient in that small movements by the camera operator are translated into significant image changes for the surgeon resulting in a delay to correct the image. The stability of the robot minimizes this effect. Additionally, these telescope-repositioning events normally associated with adult procedures for visualization of various dissection fields are not required in this population resulting in shorter operating times. Finally, with turnover in the operating room staff, one has to continually train a new



**Fig 4.** This single cannula technique for laparoscopic Nissen fundoplication can be utilized in infants and adolescents. On the left, the technique is being utilized in an infant, whereas on the right, it is used in a 13 year old.





**Fig 5.** On the left, the completed Nissen fundoplication is seen. On the right, a gastrostomy button has been placed through the left epigastric stab incision and Steri-Strips have been used to close the remaining 3 stab incisions.

camera holder, which results in longer operating times. This problem is not present with AESOP.

As noted in Table 1, we did not identify a significant difference in operating times between groups A (human controlled) and B (initial robotic control). However, there was a significant change in favor of robotic control in the later groups. Unquestionably, this represents a learning curve for robot setup and function. During the period that the 34 patients in group B underwent LNF, we were identifying the most effective position for the robot as well as the optimal telescope position within the abdomen to eliminate as much camera movement for hiatal dissection as possible. As seen by the reduction in operating times in the later groups, we feel we were successful in this regard.

Our technique utilizing a single umbilical cannula

**Table 1. Comparison of Operating Times With and Without Robotic Telescopic Assistance**

Group	No. of Patients	Mean Operating Time
A	10	108 min
B	34	110 min
C	39	93 min
D	71	69 min

NOTE. *P* values are A versus B, .058; A versus C, < .05; A versus D, < .05.

with transabdominal wall stab incisions for instrumentation has not been reported previously. The technique of introducing instruments through the abdominal wall without a cannula is accomplished easily whether in an infant or teenager, and we did not identify a single complication associated with it. The concern about losing an adequate pneumoperitoneum was not encountered. Another benefit provided by this technique, especially apparent in neonates and infants with small intraabdominal volumes, is the elimination of intraabdominal cannulas. These cannulas can inhibit surgeon movement by contacting each other, which may lead to more inefficient technical movements. Also, their presence within the abdominal cavity takes up volume that otherwise is reserved for improved visualization and surgical use. Moreover, these small cannulas can be difficult to stabilize in the abdominal wall. They frequently become dislodged and need to be reinserted.

We have shown that LNF can be accomplished effectively and safely using a single umbilical cannula and robotic telescopic assistance with decreased operating times. We feel it should be the preferred approach for LNF and other laparoscopic procedures in infants and children.

## REFERENCES

1. Chung DH, Georgeson KE: Fundoplication and gastrostomy. *Semin Pediatr Surg* 7:213-219, 1998
2. Sampson LK, Georgeson KE, Winters DC: Laparoscopic gastrostomy as an adjunctive procedure to laparoscopic fundoplication in children. *Surg Endosc* 10:1106-1110, 1996
3. Cadiere GB, Himpens J, Vertruyen M, et al: Evaluation of telesurgical (robotic) Nissen fundoplication. *Surg Endosc* 15:918-923, 2001
4. Jacobs LK, Shayani V, Sackier JM: Determination of the learning curve of the AESOP robot. *Surg Endosc* 11:54-55, 1997
5. Melvin WS, Needleman BJ, Krause KR, et al: Computer-assisted robotic heller myotomy: Initial case report. *J Laparoendosc Adv Surg Tech* 11:251-253, 2001
6. Gould JC, Melvin WS: Computer-assisted robotic antireflux surgery. *Surg Laparosc Endosc Percutan Tech* 12:26-29, 2002
7. Meininger DD, Byhahn C, Heller K, et al: Totally endoscopic Nissen fundoplication with a robotic system in a child. *Surg Endosc* 15:1360, 2001
8. Johanet H: Robot á commande vocale: Une nouvelle aide opératoire? *Ann Chirurg* 52:918-921, 1998
9. Geis WP, Kim HC, McAfee PC, et al: Synergistic benefits of combined technologies in complex, minimally invasive surgery. *Surg Endosc* 10:1025-1028, 1996
10. Vara-Torbeck C, Munoz VF, Toscano R, et al: A new robotic endoscope manipulator. A preliminary trial to evaluate the performance of a voice-operated industrial robot and a human assistant in several simulated and real endoscopic operations. *Surg Endosc* 15:924-927, 2001

## Discussion

*Omar (Qatar):* This is a very good thing to use, especially if there is a skeleton-muscular coordination problem and especially in small babies. How much does this instrument cost?

*D.J. Ostlie (response):* A. In the United States, around \$120,000.

*J. Langer (Toronto, Ontario):* This is a really nice technique. How do you get the needle in there when you are going to do a fundoplication?

*D.J. Ostlie (response):* We use a 2-0 or 3-0 silk, and it is skewed before you introduce it into the abdomen. It is placed through the left upper quadrant incision where you are using your dominant hand for sewing. Interestingly, there is no significant loss of pneumoperitoneum. As the operation progresses, this incision dilates up. With this dilation you will lose some pneumoperitoneum; however, by increasing your CO<sub>2</sub> flows, it is easy to prevent loss of visualization. Most of us who do laparoscopy in small children need to understand that if you leave your insufflation flows high at the beginning of the procedure, you will get high abdominal pressures as a result of flow increases during the respiratory variation with ventilation. This high abdominal pressure can decrease venous return, which can lead to anaesthesia difficulties. At the beginning of the operation you need to leave your flows very low, one to 2 L/min, but as needles are moved in and out, a small leak will develop and by increasing the flow rates the pneumoperitoneum will be maintained without increased abdominal pressures.

*S. Rothenberg (Denver, CO):* I enjoyed your presentation very much. I wonder how much time was saved. Did you measure the time it actually took to set up AESOP for each case? How much of your time saving went on a learning curve, learning how to do a fundoplication. It has been shown in a couple of studies that the first 50 cases were significant in the learning curve. After about 100 cases, the fundoplication time became quite constant. In our series, for the last 100 fundoplications, the operating time is about 40 minutes. So I wonder if some of the time savings that you are attributing to AESOP are in fact learning curve and exactly

how much time is attributed to setting up AESOP and how did those times change? When not using AESOP, part of the problem is not relegating the camera holding to the most junior person or the attending surgeon. Probably the 2 worst people to do it. The most junior person because they have no experience, and the attending surgeon because they think they know what they want to look at and they can actually hinder the operation. I think if you had the ability to find a dedicated cameraman who may be cheaper than using AESOP that that variability is diminished and so that you are comparing a third year student to a robot who will do exactly what you want; but you may have a third alternative. Did you find that you had to change your port placement, or did you have conflicts with the arm in trying to perform the procedure? AESOP's arm in relation to 3 or 4 kilo baby takes up quite a bit of space, and in my experience I have found that I have to modify what I felt to be an optimal port placement to try and work around the arm.

*D.S. Ostlie (response):* Dr Holcomb is the senior author who performed all these operations with either myself or the other 2 colleagues on this report. He had performed over 200 laparoscopic fundoplications before using AESOP; therefore, his learning curve should not need to be taken into account. I cannot speak for learning curves of other colleagues and residents, which could vary tremendously depending on training in paediatric laparoscopic surgery. We never changed the positioning of AESOP. He always tries to do 2 fundoplications in the same day and, when possible, we don't take AESOP off the table, but rather take the patient off the right side of the table. In terms of setting AESOP up, I don't think that plays a big role, although it could perhaps be considered. It is not one of the parameters we looked at and could be viewed as a fault of the study. We did not have to change port placements in the smaller (less than 10 kg) children. Interestingly, in the older children, you cannot use the 1° down angle and the full tilt position because they are in lithotomy position instead of the frog-leg position. The leg occasionally is placed right up next to the negative tilt of AESOP. Usually you can modify the tilt to 0°.