





Disponible en ligne sur
 SciVerse ScienceDirect
www.sciencedirect.com

Elsevier Masson France
 EM|consulte
www.em-consulte.com



Progressive familial intrahepatic cholestasis

Emmanuel Jacquemin

Pediatric Hepatology and Liver Transplantation Unit, and Reference Centre for Rare Liver Diseases, Bicêtre Hospital, AP-HP, 78 rue du général Leclerc, 94275 Le Kremlin-Bicêtre cedex, France; INSERM, UMR-S757, University of Paris-Sud 11, Orsay, France

Summary

Progressive familial intrahepatic cholestasis (PFIC) refers to a heterogeneous group of autosomal-recessive disorders of childhood that disrupt bile formation and present with cholestasis of hepatocellular origin. The exact prevalence remains unknown, but the estimated incidence varies between 1/50,000 and 1/100,000 births. Three types of PFIC have been identified and associated with mutations in hepatocellular transport-system genes involved in bile formation. PFIC1 and PFIC2 usually appear in the first months of life, whereas onset of PFIC3 may arise later in infancy, in childhood or even during young adulthood. The main clinical manifestations include cholestasis, pruritus and jaundice. PFIC patients usually develop fibrosis and end-stage liver disease before adulthood. Serum gamma-glutamyltransferase (GGT) activity is normal in PFIC1 and PFIC2 patients, but is elevated in PFIC3 patients. Both PFIC1 and PFIC2 are caused by impaired bile salt secretion due to defects in *ATP8B1* encoding the FIC1 protein and in *ABCB11* encoding bile salt export pump (BSEP) protein, respectively. Defects in *ABCB4*, encoding multidrug resistance 3 protein (MDR3), impair biliary phospholipid secretion, resulting in PFIC3. Diagnosis is based on clinical manifestations, liver ultrasonography, cholangiography and liver histology, as well as on specific tests to exclude other causes of childhood cholestasis. MDR3 and BSEP liver immunostaining, and analysis of biliary lipid composition should help to select PFIC candidates for whom genotyping could be proposed to confirm the diagnosis. Antenatal diagnosis may be proposed for affected families in which a mutation has been identified. Ursodeoxycholic acid (UDCA) therapy should be initiated in all patients to prevent liver damage. In some PFIC1 and PFIC2 patients, biliary diversion may also relieve pruritus and slow disease progression. However, most PFIC patients are ultimately candidates for liver transplantation. Monitoring of liver tumors, especially in PFIC2 patients, should be offered from the first year of life. Hepatocyte transplantation, gene therapy and specific targeted pharmacotherapy may represent alternative treatments in the future.

© 2012 Elsevier Masson SAS. All rights reserved.

Correspondence.

E-mail address: emmanuel.jacquemin@bct.aphp.fr (E. Jacquemin).

Abbreviations:

PFIC: Progressive familial intrahepatic cholestasis
GGT: gamma-glutamyltransferase
BSEP: bile salt export pump protein
UDCA: ursodeoxycholic acid
ICP: intrahepatic cholestasis of pregnancy
BRIC: benign recurrent intrahepatic cholestasis
CFTR: cystic fibrosis transmembrane conductance regulator
NBF: nucleotide-binding fold
MDR3: class III multidrug resistance
P-gp: P-glycoprotein
FXR: farnesoid X receptor

Definition

Progressive familial intrahepatic cholestasis (PFIC) refers to a heterogeneous group of autosomal-recessive liver disorders of childhood in which cholestasis of hepatocellular origin often presents in the neonatal period or first year of life and leads to death from liver failure at ages usually ranging from infancy to adolescence [1,2]. Recent molecular and genetic studies have allowed the identification of genes responsible for three types of PFIC: progressive familial intrahepatic cholestasis type 1 (PFIC1); progressive familial intrahepatic cholestasis type 2 (PFIC2); and progressive familial intrahepatic cholestasis type 3 (PFIC3). It has been shown that all three types are related to mutations in hepatocellular transport-system genes involved in bile formation (Fig. 1).

Epidemiology

In our experience, PFIC represents the cause of cholestasis in 10-15% of children, and 10-15% of liver transplantation indications in children. PFIC1 and PFIC2 represent two-thirds of cases of PFIC, and PFIC3 the remaining third of cases [1]. The true incidence of PFIC is not precisely known, but it is considered a rare disease, with an estimated incidence of 1/50,000 to 1/100,000 births. All types of PFIC are seen worldwide. Both genders appear to be equally affected.

Clinical description

The main characteristics of PFIC types 1-3 are summarized in Table 1. Cholestasis is a major clinical sign in all forms of PFIC. It usually appears in the first months of life in patients with PFIC1 and is characterized by recurrent episodes of jaundice, which become permanent later on in the course of the disease. In cases of PFIC2, the initial presentation and its evolution appear to be more severe, with permanent jaundice from the first months of life and the rapid appearance of liver failure within the first years

of life. Early hepatocellular carcinoma (before 1 year of age) and cholangiocarcinoma may complicate the course of PFIC2. Severe pruritus is usually observed in PFIC1 and PFIC2 patients. Phenotypic findings in PFIC1 and PFIC2 are also similar, although slight phenotypic differences have been identified [1-3]. Extrahepatic features, for example, reported in PFIC1 patients (persistent short stature, sensorineural deafness, watery diarrhea, pancreatitis, elevated sweat electrolyte concentration, liver steatosis) have not been described in PFIC2 cases. In contrast to PFIC types 1-2, clinical signs of cholestasis are noted within the first year of life in about one-third of patients and rarely in the neonatal period in PFIC3 patients. PFIC3 may also manifest later in infancy, in childhood and even in young adulthood [4]. Gastrointestinal bleeding due to portal hypertension and cirrhosis are the presenting symptoms in adolescent or young adult patients, and pruritus is usually mild. Progression is characterized by chronic icteric or anicteric cholestasis, portal hypertension and liver failure. In half of all PFIC3 patients, liver transplantation is required at a mean age of 7.5 years. Hepatocarcinoma may also develop during adolescence.

Laboratory findings

Patients with PFIC types 1-2 have normal serum gamma-glutamyltransferase (GGT) activity, normal serum cholesterol levels and very high serum bile acid concentrations. Although PFIC1 and PFIC2 share similar laboratory findings, PFIC2 patients have higher transaminase and alpha-fetoprotein serum levels at diagnosis than those with PFIC1 [1-3]. On the other hand, patients with PFIC3 have a persistent high serum GGT activity, normal serum cholesterol levels and moderately raised concentrations of serum primary bile salts [4].

Histological findings

In PFIC1 patients, liver histology is characterized by canalicular cholestasis and the absence of true ductular proliferation, with only periportal biliary metaplasia of hepatocytes. In PFIC2 patients, the same signs are seen, but the liver architecture is more perturbed, with more pronounced lobular and portal fibrosis and inflammation. Hepatocellular necrosis and giant-cell transformation are also much more pronounced in PFIC2 than in PFIC1, and may persist over time. These differences between PFIC1 and PFIC2 most likely reflect the severe lobular injury present in PFIC2 [3].

In PFIC3, liver histology, obtained at the time of diagnosis, shows portal fibrosis and true ductular proliferation with a mixed inflammatory infiltrate. In a few instances, cholestasis is present in the lobule and in some ductules containing bile plugs. Slight giant-cell transformation of hepatocytes may be observed. Cytokeratin immunostaining confirms the major ductular proliferation within the portal tract. At a later stage, there is extensive portal fibrosis and a typical picture of biliary cirrhosis. Interlobular bile ducts are seen in most portal tracts, and there is neither periductal fibrosis nor biliary epithelium injury [4].

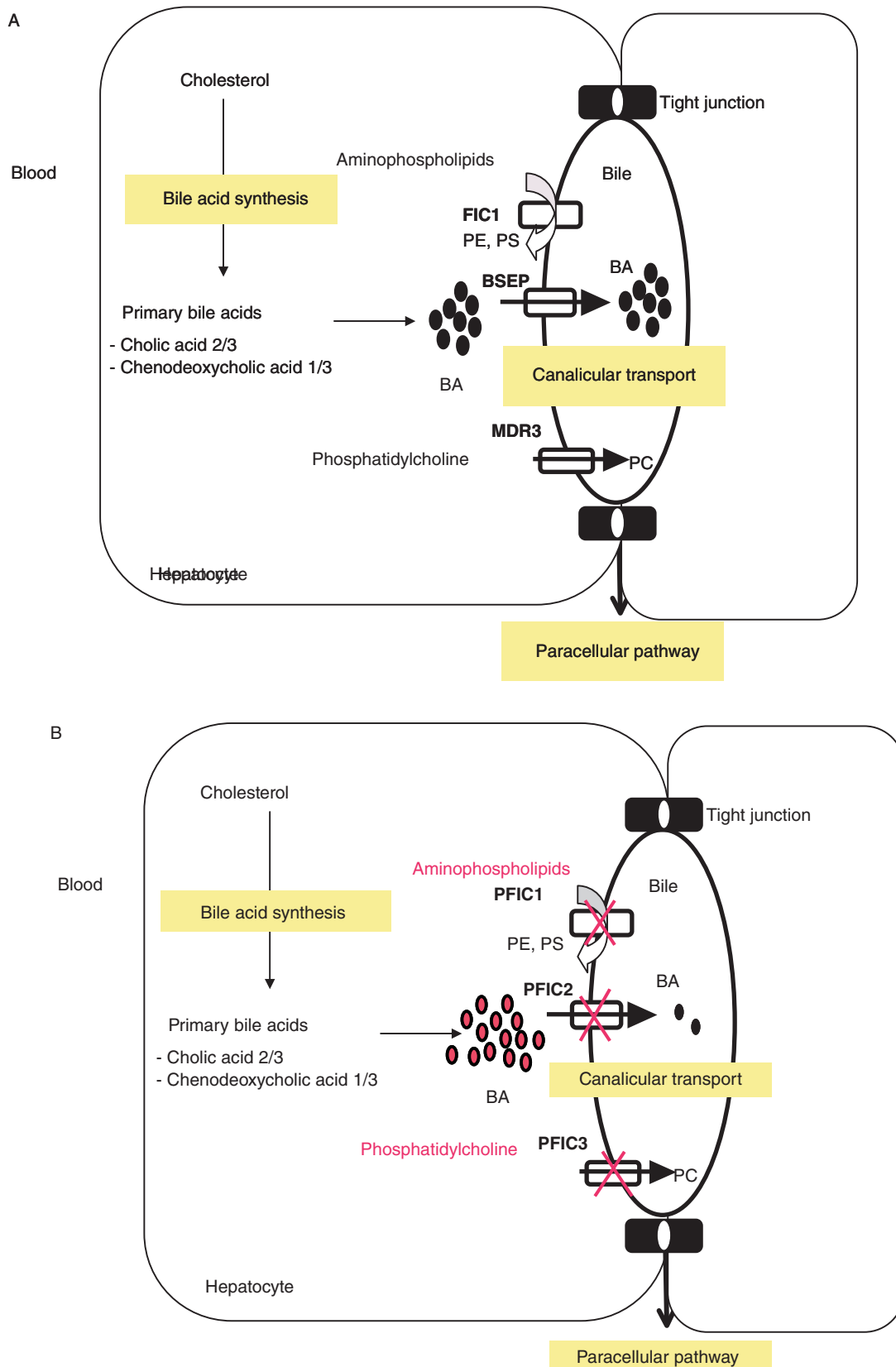


Table 1 Main characteristics of progressive familial intrahepatic cholestasis (PFIC) types 1-3.			
	PFIC1	PFIC2	PFIC3
Transmission	Autosomal-recessive	Autosomal-recessive	Autosomal-recessive
Pruritus	Severe	Very severe	Moderate
Serum GGT activity	Normal	Normal	High
Serum ALT	Mildly elevated	>5x normal	Mildly elevated
Serum AFP	Normal	Elevated	Normal
Liver histology	Canalicular cholestasis, mild lobular fibrosis	Canalicular cholestasis, lobular fibrosis, giant-cell hepatitis	Ductular proliferation, biliary fibrosis
Serum primary bile acid concentration	Very high	Very high	High
Bile composition	Low primary bile acid concentrations	Very low primary bile acid concentrations	Low phospholipid concentrations
Chromosomal locus	18q21-22	2q24	7q21
Gene/protein	<i>ATP8B1</i> /FIC1	<i>ABCB11</i> /BSEP	<i>ABCB4</i> /MDR3
Hepatocyte location	Canalicular membrane	Canalicular membrane	Canalicular membrane
Other main sites of expression	Cholangiocytes, intestine, pancreas	None	None
Extrahepatic symptoms	Diarrhea, pancreatitis, hearing loss, small stature	None	None
Functional defect	ATP-dependent aminophospholipid flippase	ATP-dependent bile acid transport in bile	ATP-dependent phosphatidylcholine floppase

GGT: Gamma-glutamyltransferase; ALT: Alanine aminotransferase; AFP: Alpha-fetoprotein; BSEP: Bile salt export pump; FIC1: Familial intrahepatic cholestasis 1; MDR3: Class III multidrug resistance

Etiology

PFIC type 1

PFIC1 (previously reported as "Byler disease") is caused by mutations in the *ATP8B1* gene (also designated *FIC1*) [1,2,5]. This gene, which encodes a P-type ATPase, is located on human chromosome 18, and is also mutated in the milder phenotype of benign recurrent intrahepatic cholestasis type 1 (BRIC1) and in Greenland familial cholestasis. FIC1 protein is located on the canalicular membrane of hepatocytes whereas, within the liver, it is mainly expressed in cholangiocytes. This P-type ATPase is most likely an aminophospholipid transporter responsible for maintaining the enrichment of phosphatidylserine and phosphatidylethanolamine on the inner leaflet of the plasma membrane. The asymmetrical distribution of lipids in the membrane bilayer plays a protective role against high bile salt concentrations in the canalicular lumen [6]. This flippase may also play a role in maintaining canalicular membrane integrity, including microvilli formation [7,8]. How mutations in this protein cause cholestasis is unclear. It is postulated that abnormal protein function could indirectly disrupt the biliary secretion of bile acids, thereby explaining the low

biliary bile acid concentrations found in PFIC1 patients [3]. Different studies have shown that impaired *ATP8B1* function in patients with PFIC1 results in substantial downregulation of the farnesoid X receptor (FXR), a nuclear receptor involved in the regulation of bile acid metabolism, with subsequent downregulation of bile salt export pump (BSEP) protein in the liver, upregulation of bile acid synthesis and apical sodium bile salt transporter (ASBT) in the intestine [9,10]. All in all, these events lead to hepatocyte bile acid overload. Furthermore, evidence of cystic fibrosis transmembrane conductance regulator (CFTR) downregulation in cholangiocytes has also been reported in patients with PFIC1, and could contribute to impairment of bile secretion and explain some of the extrahepatic features [1].

The *ATP8B1* gene is expressed in various organs, including the liver, pancreas, kidney and small intestine, but is more highly expressed in the small intestine than in the liver. Therefore, it is thought to be involved in the enterohepatic cycling of bile salts. This may also explain the chronic diarrhea present in a few children with PFIC1. Other extrahepatic features associated with PFIC1, such as persistent short stature, deafness and pancreatitis, suggest a general biological cell function for FIC1 [1,11].

It is also likely that FIC1 disease represents a continuum comprising intermediate phenotypes between the benign phenotype BRIC1 and the severe phenotype PFIC1 [1,5]. So far, there is no clear explanation for the phenotypic differences between patients with BRIC1 and those with PFIC1. Analyses suggest that mutations identified in patients with PFIC1 would severely disrupt protein function, whereas protein function would be only partially impaired in patients with BRIC1 [5]. Genotype - phenotype associations would probably be complicated as a dramatic variability in phenotypic presentation has already been identified in patients with BRIC1 with a common mutation. In addition, many patients with FIC1 disease are compound heterozygous, which would also complicate the identification of genotype - phenotype correlations [5]. Heterozygous *ATP8B1* mutations have been identified in some cases of transient neonatal cholestasis and in intrahepatic cholestasis of pregnancy (ICP), which may be referred to as "ICP type 1" (ICP1) [1,12].

PFIC type 2

PFIC2 (previously referred to as "Byler syndrome") is caused by mutations in the *ABCB11* gene (also designated *BSEP*) [1-,13]. The *ABCB11* gene encodes the ATP-dependent canalicular BSEP in human liver and is located on human chromosome 2. BSEP protein, expressed at the hepatocyte canalicular membrane, is the major exporter of primary bile acids against extreme concentration gradients. Mutations in this protein are responsible for the decreased biliary bile salt secretion described in affected patients, leading to decreased bile flow and accumulation of bile salts within the hepatocyte with ongoing severe hepatocellular damage. In addition, BSEP deficiency represents a phenotypic continuum between BRIC2 and PFIC2 [14]. So far, no clear genotype - phenotype correlation has been identified among PFIC2 patients, but most children with BSEP mutations, regardless of mutation type, have no canalicular BSEP protein expression [13]. Severe phenotypes are often associated with mutations leading to premature protein truncation or failure of protein production. Insertion, deletion, nonsense and splicing mutations result in damaging effects, with patients exhibiting little or no detectable BSEP at the hepatocyte canalculus. Missense mutations are also common defects that can either affect protein processing and trafficking or disrupt functional domains and protein structure [13,15]. Thus, detectable BSEP expression does not preclude functional BSEP deficiency. Some mutations have been functionally characterized and confirm the defect in bile acid secretion [16].

In milder disease such as BRIC2, missense mutations predominate over those leading to failure of protein production, and the mutations are seen in less conserved regions than in the nucleotide-binding folds (NBFs), which contain the Walker A/B motifs and the ATP-binding cassette (ABC) signature. Cholelithiasis has also been reported in BRIC2 patients [14, and personal data]. In addition, heterozygous *ABCB11* mutations have been identified in cases of ICP2 [17], drug-induced cholestasis [18] and transient neonatal cholestasis [1].

PFIC type 3

PFIC3 is caused by a genetic defect in the *ABCB4* gene (also designated *MDR3*) located on chromosome 7. Class III multidrug resistance (MDR3) of P-glycoprotein (P-gp), a phospholipid translocator involved in biliary phospholipid (phosphatidylcholine) excretion (floppase), is predominantly, if not exclusively, expressed in the canalicular membrane of hepatocytes [4]. Cholestasis results from the toxicity of bile in which detergent bile salts are not inactivated by phospholipids, leading to bile canaliculi and biliary epithelium injuries. The mechanism of liver damage in PFIC3 patients is most likely related to the absence of biliary phospholipids. Injury to bile canaliculi and biliary epithelium is probably due to continuous exposure to hydrophobic bile salts, the detergent effects of which are no longer being countered by phospholipids, thereby leading to cholangitis. In addition, the stability of mixed micelles in bile is determined by a three-phase system in which the proper proportion of bile salts and phospholipids is necessary for maintaining solubility of cholesterol. The absence of phospholipids in bile would be expected to destabilize micelles and promote bile lithogenicity through crystallization of cholesterol, which might favor small bile duct obstruction. These cholangiopathy mechanisms fit well with histological findings such as ductular proliferation. PFIC3 represents an important example of canalicular transport defect leading to the development of cholangiopathy.

The phenotypic spectrum of PFIC3 ranges from neonatal cholestasis to cirrhosis in young adults [4,19]. In our experience, *ABCB4* sequence analysis in PFIC3 patients has revealed a large number of different *ABCB4* mutations characterized on both alleles in most cases. In one-third of cases, mutations gave rise to a truncated protein. When tested, no MDR3 P-gp could be detected by liver immunostaining in these patients. The lack of MDR3 protein could be explained in two ways. The truncated protein may be broken down rapidly after synthesis, giving rise to extremely low steady-state levels of the protein. However, the premature stop codon is more likely to lead to instability and decay of the *ABCB4* mRNA. This latter explanation is supported by the near absence of *ABCB4* mRNA on northern blotting of liver samples from multiple patients. The remaining two-thirds of patients had missense mutations, some of which were found in the highly conserved amino-acid sequences of the Walker A/B motifs involved in ATP-binding. Such amino-acid changes in the Walker A or B motif are generally not compatible with ATPase activity and transport processes. Alternatively, missense mutations might result in intracellular misprocessing of MDR3, as shown with other ABC transporters [20]. Indeed, such missense mutations were associated with a decreased level of MDR3 canalicular protein. Whatever the mechanism(s) involved, the low level of biliary phospholipids found in patients with missense mutations demonstrates the MDR3 functional defect [4]. Also, there is now strong evidence that, in addition to PFIC3, a predominantly heterozygous MDR3 defect may be involved in ICP3 [17], cholesterol gallstone disease [21], drug-induced cholestasis [22], and some cases of transient neonatal cholestasis, adult idiopathic cirrhosis and cholangiocarcinoma [19,23,24]. Furthermore, MDR3 deficiency could represent a clinical continuum, as a single patient may experience different phenotypes during the disease course, starting with cholesterol cholelithiasis, followed by ICP and ending with biliary cirrhosis [25].

Diagnosis and diagnostic methods

PFIC should be suspected in children with a clinical history of cholestasis of unknown origin after exclusion of other common causes of cholestasis (such as biliary atresia, Alagille syndrome, alpha-1-antitrypsin deficiency, cystic fibrosis, sclerosing cholangitis and extrahepatic bile duct obstruction) [1,2]. High serum bile acid concentrations exclude primary disorders of bile acid synthesis [26]. Patients with PFIC1 and PFIC2 have normal serum GGT activity, while patients with PFIC3 have high serum GGT activity. PFIC3 patients can also be distinguished from patients with PFIC types 1-2 in that they rarely present with cholestatic jaundice in the neonatal period, but do so later on in infancy, childhood or young adulthood instead. A combined clinical, biochemical, radiological and histological approach, together with liver immunostaining and biliary lipid analysis, allows classification of PFIC types and may lead to adequate molecular diagnosis.

Diagnostic methods

Radiological approach

Initial ultrasonography of the liver must be performed to exclude biliary tract disease. Typically, ultrasonography is normal, but may reveal a huge gallbladder. Sometimes, biliary stones may be identified. If performed, cholangiography may show a normal biliary tree, excluding sclerosing cholangitis, and allows bile to be collected for biliary lipid analysis [1-4].

Liver histology

This is important for diagnosis as it allows liver immunostaining to be performed. Typical features have been described above (see the clinical description section). When signs of biliary obstruction appear on liver biopsy, as may be seen in PFIC3, cholangiography should be performed to exclude sclerosing cholangitis [1-4].

Liver immunostaining

Commercially available MDR3 and BSEP antibodies allow liver immunostaining to be performed [1,3,4,13]. Absence of canalicular or mild immunostaining favors a gene defect. However, normal staining does not preclude a gene defect as a mutation may induce loss of function, but with normal synthesis and expression.

Biliary lipid analysis

This can be performed with gallbladder bile or with bile collected by duodenal aspiration (pure choledochal bile). In cases of gallbladder puncture, bile contamination by blood may prevent proper bile analysis. In cases of duodenal aspiration, bile dilution or bile contamination by alimentary phospholipids may also interfere with proper bile analysis.

Biliary bile salt concentrations may be dramatically decreased (< 1mM) in PFIC2 patients and only mildly decreased in PFIC1 patients (3-8 mM) [3], whereas normal concentrations of biliary primary bile salts distinguish PFIC3 patients from those with PFIC1 or PFIC2 [1,4]. However, in PFIC3 patients, the biliary phospholipid level is dramatically decreased (1-15% of total biliary lipids; normal range: 19-24%). Biliary bile salt-to-phospholipid and cholesterol-to-phospholipid ratios are approximately fivefold higher than in wild-type bile. The residual percentage of biliary phospholipids appears to be directly related to the severity of the *MDR3* mutation and, consequently, to the residual activity of MDR3 P-gp. Patients with "severe" mutations (nonsense, frameshift) have a low percentage of biliary phospholipids (<2%), while patients with missense mutations have a higher percentage of biliary phospholipids (≥2%). In our experience, the threshold predictive of a positive response to ursodeoxycholic acid (UDCA) therapy in PFIC3 is represented by a percentage of biliary phospholipids of around 7%. Thus, a combination of abnormal MDR3 canalicular immunostaining and a low percentage of biliary phospholipids is highly suggestive of MDR3 deficiency.

Molecular analysis

Gene analysis usually involves DNA sequencing of the 27 coding exons and their splice junctions. In cases of silent or intronic mutations, a test *in silico* is helpful for predicting a potential splice defect that would still need to be confirmed by RNA analysis using real-time reverse transcription polymerase chain reaction (RT-PCR) and sequencing [27]. The use of a resequencing chip dedicated to genetic cholestasis could also facilitate identification of a gene mutation [28].

Differential diagnosis

Several other autosomal-recessive PFIC-like diseases are recognized (Table 2). Liver diseases resembling PFIC with normal GGT activity have been identified as inborn errors in primary bile acid synthesis and represent distinct disorders [1,2,26], and other liver diseases resembling PFIC with normal serum GGT activity are also known. Familial Amish hypercholanemia represents a PFIC-like disorder not due to a primary defect of the transport system involved in bile formation, but caused by a tight-junction protein defect combined with a defect of primary bile acid conjugation [1,29]. Cholestasis is caused by impaired transport of unconjugated bile acids into bile and bile leakage into plasma through abnormal canalicular tight junctions, thereby increasing paracellular permeability. Another category of progressive cholestatic liver disease of childhood might be due to abnormal villin expression leading to loss of structural integrity of the canalicular microvilli, thus impairing biliary secretion system function [1]. A case of hypercholanemia due to mutations in the m-epoxide hydrolase gene (*EPHX1*) has also been reported [1]. Arthrogryposis - renal dysfunction - cholestasis syndrome is a complex disease resulting from mutations of *VPS33B/VIPAR*, which are involved in intracellular trafficking and targeting of apical proteins. These gene defects

Table 2 Other progressive familial intrahepatic cholestasis (PFIC)-like diseases

Disease	GGT	Protein, <i>gene</i> (chromosome)
Primary bile acid synthesis or conjugation defects		
3 β -HSD defect	N	3 β -HSD, <i>HSD3B7</i> (16)
Δ^4 -3oxo-R defect	N	Δ^4 -3oxo-5 β R, <i>AKR1D1</i> (7)
Oxysterol 7 α -OHase defect	N	oxysterol 7 α -OHase, <i>CYP7B1</i> (8)
BAAT defect	N	BAAT, <i>BAAT</i> (9)
BACL defect	N	BACL, <i>SLC27A5</i> (19)
Trafficking and canalicular targeting defects		
ARC syndrome	N	VPS33B, <i>VPS33B</i> (15) VIPAR, <i>VIPAR</i> (14)
Tight-junction defects		
NISCH*	E	Claudin-1, <i>CLDN1</i> (3)
Familial Amish hypercholanemia [#]	N	ZO-2, <i>TJP2</i> (9)
Other defects		
Familial hypercholanemia	N	EPHX1, <i>EPHX1</i> (1)
NAICC	E	Cirhin, <i>CIRH1A</i> (16)
PCC	E	Villin, ? (2)
Agenaes syndrome	E	?, (15q26.1)

GGT: Serum gamma-glutamyltransferase activity; N: Normal; E: Elevated; 3 β -HSD: 3 β -hydroxy- Δ^5 -C₂₇-steroid oxydoreductase; Δ^4 -3oxo-R: Δ^4 -3-oxosteroid 5 β -reductase; Oxysterol 7 α -OHase: Oxysterol 7 α -hydroxylase; BAAT: Bile acid-CoA:amino-acid N-acyltransferase; BACL: Bile acid-CoA ligase; ARC: Arthrogyrosis - renal dysfunction - cholestasis; EPHX1: Epoxyde hydroxylase 1; NISCH: Neonatal ichthyosis sclerosing cholangitis; NAICC: North American Indian childhood cirrhosis; PCC: progressive cholestatic liver disease of childhood;

*Claudin-1 defect is present in hepatocytes and cholangiocytes; [#]ZO-2 defect is associated with a bile acid conjugation defect (BAAT defect)

result in a loss of apical protein expression in the liver and kidneys [30]. For the liver, it represents another PFIC-like disorder with normal GGT activity. In cases of high serum GGT activity, sclerosing cholangitis must be excluded [31]. North American Indian childhood cirrhosis due to a defect in the cirhin gene is characterized by high GGT activity, as is Agenaes syndrome, a lymphedema cholestasis syndrome of unknown cause [1].

Genetic counseling and antenatal diagnosis

Genotyping should be used to confirm the diagnosis of PFIC in affected children. Heterozygosity of parents for the defects found in affected patients confirms the recessive inheritance of the disease. This awareness has already allowed prenatal diagnosis. However, antenatal diagnosis of PFIC requires clinical and biochemical expertise [23].

Specific management, including treatment

Therapy with UDCA should be considered in the initial therapeutic management of children with all types of

PFIC [3,4,32]. UDCA therapy may be effective in some patients, especially those with PFIC3 with missense mutations, who have less severe disease in comparison to children with a mutation leading to truncated protein [4].

Some patients with PFIC1 or PFIC2 may also benefit from surgical biliary diversion [33]. Nasobiliary drainage may help to select potential responders to biliary diversion [34]. So far, however, clear genotype - phenotype correlation data are lacking and still need to be defined to identify those PFIC types 1-2 patients who might benefit from UDCA or biliary diversion [3]. Preliminary data suggest that PFIC2 patients with p.D482G or p.E297G mutations may respond well to biliary diversion. Nevertheless, if these therapies fail, liver transplantation represents the only alternative [1]. In our experience, the extrahepatic features, such as diarrhea, liver steatosis and short stature, sometimes associated with PFIC1 do not improve or may be aggravated following successful biliary diversion or liver transplantation [1]. In fact, chronic diarrhea may become intractable when biliary bile salt secretion is restored after liver transplantation [1,11]. It is often associated with severe liver steatosis and/or steatohepatitis that can lead to cirrhosis over time and to indications for retransplantation. Liver steatosis and diarrhea may even recur after retransplantation (personal data). Diarrhea may be favorably managed by bile adsorptive resin treatment [1,11]. In the future, therapies such as

cell, gene and specific targeted pharmacological therapies (for example, FXR inducers and chaperone drugs; Fig. 2) could represent an alternative therapy for all types of PFIC [35-40]. In PFIC2, it is uncertain whether hepatocyte transplantation or gene therapy with modified hepatocytes represents a good therapeutic approach. Indeed, with this approach, it may be risky to leave premalignant liver cells in place, especially in patients with severe biallelic *ABCB11* mutations [41].

who became pregnant [22,42]. Patients with BSEP deficiency, especially those with biallelic truncating mutations, are at considerable risk of hepatobiliary malignancy (hepatocellular carcinoma or cholangiocarcinoma) [3,13,41,43]. These findings justify close monitoring of hepatocellular carcinoma (at the very least with serum alpha-fetoprotein doses every 6 months and liver ultrasonography every year) in PFIC2 patients from the first year of life. Liver tumor monitoring is also justified in PFIC3 [4,24].

Prognosis

In addition to the natural history and complications of all three types of PFIC (portal hypertension, liver failure, cirrhosis, hepatocellular carcinoma, extrahepatic manifestations), children with PFIC types 1-3 are also theoretically at risk of developing biliary stones, drug-induced cholestasis and ICP further along in the disease course. Girls receiving UDCA therapy who reach adulthood with their native liver should not stop UDCA during pregnancy because of the risk of developing severe ICP, as seen in a previously reported patient

Questions to be answered in the future

In rare PFIC cases (< 10%), only one mutated allele or no mutation is identified [3,4]. This may be explained by mutations that map to the regulatory sequences of genes. A gene involved in the transcription of PFIC genes (such as *FXR*) or in trafficking/targeting of canalicular transporters (such as *CDC50*, *Rab11a* and *myosin Vb*) may also be involved [30,44-47]. In addition, it is possible that other, unidentified genes involved in bile formation are responsible for the PFIC types 1-3 phenotypes. Furthermore, it may be

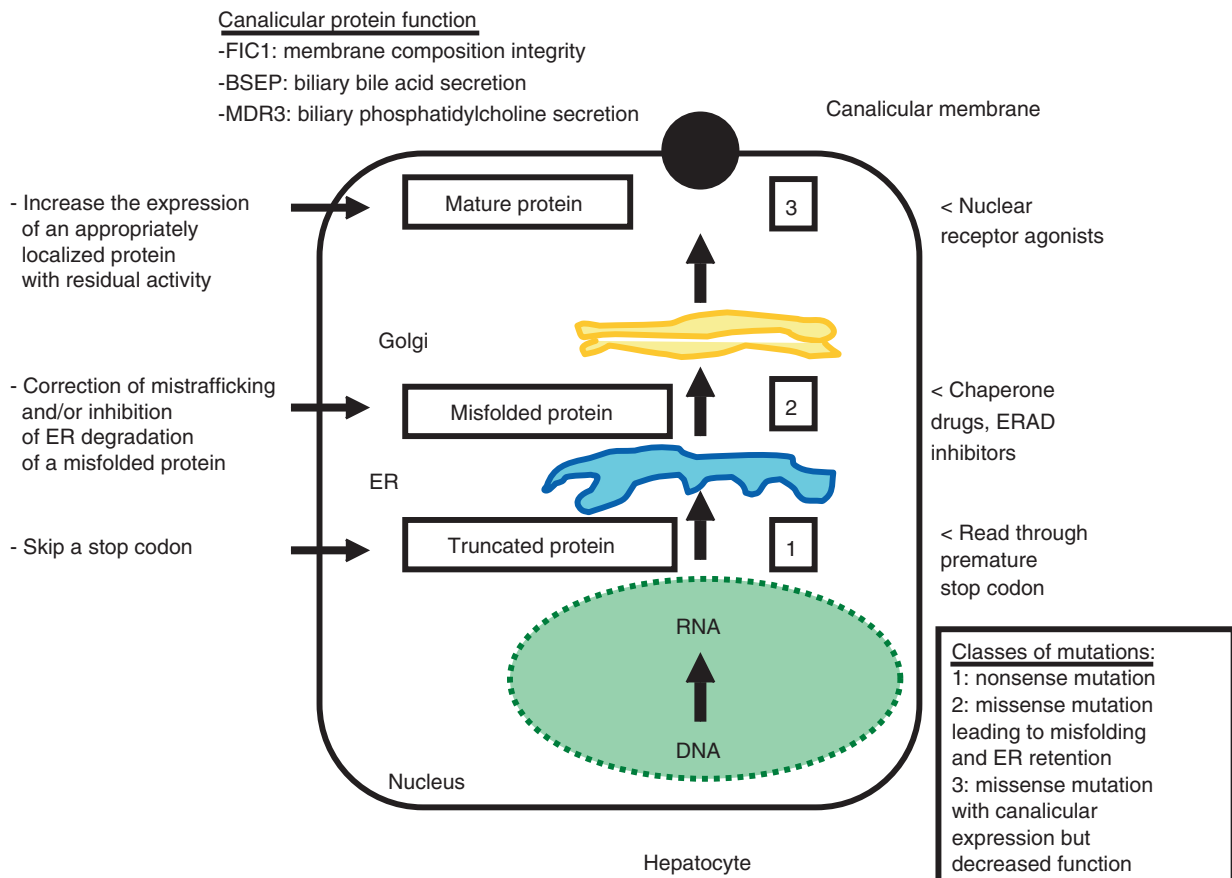


Figure 2 Mutation-specific drug therapy in progressive familial intrahepatic cholestasis (PFIC): Identification of mutation class (nonsense, missense), assessment of canalicular membrane expression *in vivo* of mutant protein (immunohistochemistry), and study *in vitro* of protein trafficking/proteasomal degradation, of residual function of mutated protein as well as the effect of various drugs constitute the rationale guiding a mutation-specific drug therapy strategy. Read-through premature stop codons (mainly UGA) by drugs (for example, aminoglycosides and PTC124), endoplasmic reticulum associated degradation (ERAD) inhibition by ERAD inhibitors (such as MG132), correction of protein misfolding by chaperone drugs (such as 4-phenylbutyrate) and increasing gene transcription by nuclear receptor agonists (such as 6 α -ethyl-chenodeoxycholate, fibrates, statins) are different approaches that could be used to render possible sufficient expression of a functional protein at the canalicular membrane.

hypothesized that combined heterozygous mutations for two genes (say *MDR3* and *BSEP*) may lead to a PFIC-like phenotype [48]. Another interesting possibility is that, in a heterozygous state, the mutated protein may have a dominant negative effect on protein expression/function [49]. Modifier genes and environmental influences could also play a role in the expression of PFIC.

After liver transplantation, the possible recurrence of PFIC on liver graft due to alloimmunization of the recipient against the *BSEP*, *MDR3* or *FIC1* proteins of liver donors remains a theoretical matter of debate. It is hypothesized that PFIC patients with severe mutations leading to a lack of gene product would be immunologically naïve for *FIC1*, *BSEP* or *MDR3* gene products. In this context, alloimmunization could arise following liver transplantation. To our knowledge, this post-transplant complication has been reported so far only in PFIC2 [50], manifesting as an unexplained severe bout of pure hepatocellular cholestasis resembling PFIC2. As yet, the incidence and natural history of this alloimmunization process is not well known.

In addition, in cases of parental living donor transplantation, it could be expected that the heterozygous status of the liver graft may lead to a predisposition for developing lithiasis or cholestasis favored by immunosuppressive drugs [18] that could interfere with canalicular protein function, as seen in a PFIC2 patient [1]. Nevertheless, this complication is likely to be extremely rare, as it has not been reported in a large case series of living donor transplantation for PFIC [51].

Competing interests

The author declares that he has no competing interests.

References

- [1] Davit-Spraul A, Gonzales E, Baussan C, Jacquemin E. Progressive familial intrahepatic cholestasis. *Orphanet J Rare Dis* 2009;4:1.
- [2] Stapelbroek JM, van Erpecum KJ, Klomp LW, Houwen RH. Liver disease associated with canalicular transport defects: current and future therapies. *J Hepatol* 2010;52:258-71.
- [3] Davit-Spraul A, Fabre M, Branchereau S, Baussan C, Gonzales E, Stieger B, et al. ATP8B1 and ABCB11 analysis in 62 children with normal gamma-glutamyl transferase progressive familial intrahepatic cholestasis (PFIC): phenotypic differences between PFIC1 and PFIC2 and natural history. *Hepatology* 2010;51:1645-55.
- [4] Davit-Spraul A, Gonzales E, Baussan C, Jacquemin E. The spectrum of liver diseases related to *ABCB4* gene mutations: pathophysiology and clinical aspects. *Semin Liv Dis* 2010;30:134-46.
- [5] Klomp LWJ, Vargas JC, Van Mil SWC, Pawlikowska L, Strautnieks SS, Van Eijk MJT, et al. Characterization of mutations in ATP8B1 Associated with hereditary cholestasis. *Hepatology* 2004;40:27-38.
- [6] Paulusma ML, Groen A, Kunne C, Ho-Mok KS, Spijkerboer AL, Rudi de Waart D, et al. Atp8b1 deficiency in mice reduces resistance of the canalicular membrane to hydrophobic bile salts and impairs bile salt transport. *Hepatology* 2006;44:195-204.
- [7] Verhulst PM, van der Velden LM, Oorschot V, van Faassen EE, Klumperman J, Houwen RH, et al. A flippase-independent function of ATP8B1, the protein affected in familial intrahepatic cholestasis type 1, is required for apical protein expression and microvillus formation in polarized epithelial cells. *Hepatology* 2010;51:2049-60.
- [8] Groen A, Romero MR, Kunne C, Hoosdally SJ, Dixon PH, Wooding C, et al. Complementary functions of the flippase ATP8B1 and the floppase ABCB4 in maintaining canalicular membrane integrity. *Gastroenterology* 2011;141:1927-37.
- [9] Chen F, Ananthanarayanan M, Emre S, Neimark E, Bull LN, Knisely AS, et al. Progressive familial intrahepatic cholestasis, type 1, is associated with decreased farnesoid X receptor activity. *Gastroenterology* 2004;126:756-64.
- [10] Alvarez L, Jara P, Sánchez-Sabaté E, Hierro L, Larrauri J, Díaz MC, et al. Reduced hepatic expression of farnesoid X receptor in hereditary cholestasis associated to mutation in ATP8B1. *Hum Mol Genet* 2004;13:2451-60.
- [11] Egawa H, Yorifuji T, Sumazaki R, Kimura A, Hasegawa M, Tanaka K. Intractable diarrhea after liver transplantation for Byler's disease: successful treatment with bile adsorptive resin. *Liver Transplant* 2002;8:714-16.
- [12] Jacquemin E, Malan V, Rio M, Davit-Spraul A, Cohen J, Landrieu P, et al. Heterozygous FIC1 deficiency: a new genetic predisposition to transient neonatal cholestasis. *J Pediatr Gastroenterol Nutr* 2010;50:447-9.
- [13] Strautnieks SS, Byrne JA, Pawlikowska L, Cebecauerová D, Rayner A, Dutton L, et al. Severe bile salt export pump deficiency: 82 different ABCB11 mutations in 109 families. *Gastroenterology* 2008;134:1203-14.
- [14] Van Mil SWC, Van den Woerd WL, Van den Brugge G, Sturm E, Jansen PLM, Bull LN, et al. Benign recurrent intrahepatic cholestasis type2 is caused by mutations in ABCB11. *Gastroenterology* 2004;127:379-84.
- [15] Byrne JA, Strautnieks SS, Ihrke G, Pagani F, Knisely AS, Linton KJ, et al. Missense mutations and single nucleotide polymorphisms in ABCB11 impair bile salt export pump processing and function or disrupt pre-messenger RNA splicing. *Hepatology* 2009;49:553-67.
- [16] Lam P, Pearson CL, Soroka CJ, Xu S, Mennone A, Boyer JL. Levels of plasma membrane expression in progressive and benign mutations of the bile salt export pump (Bsep/Abcb11) correlate with severity of cholestatic diseases. *Am J Physiol Cell Physiol* 2007;293:C1709-16.
- [17] Pauli-Magnus C, Lang T, Meier Y, Zodan-Marin T, Jung D, Breyman C, et al. Sequence analysis of bile salt export pump (ABCB11) and multidrug resistance p-glycoprotein 3 (ABCB4, MDR3) in patients with intrahepatic cholestasis of pregnancy. *Pharmacogenetics* 2004;14:91-102.
- [18] Lang C, Meier Y, Stieger B, Ulrich B, Lang T, Kerb R, et al. Mutations and polymorphisms in the bile salt export pump and the multidrug resistance protein 3 associated with drug-induced liver injury. *Pharmacogenet Genomics* 2007;17:47-60.
- [19] Zioli M, Barbu V, Rosmorduc O, Frassati-Biaggi A, Barget N, Hermelin B, et al. ABCB4 heterozygous gene mutations associated with fibrosing cholestatic liver disease in adults. *Gastroenterology* 2008;135:131-41.
- [20] Delaunay JL, Durand-Schneider AM, Delautier D, Rada A, Gautherot J, Jacquemin E, et al. A missense mutation in ABCB4 gene involved in progressive familial intrahepatic cholestasis type 3 leads to a folding defect that can be rescued by low temperature. *Hepatology* 2009;49:1218-27.
- [21] Rosmorduc O, Poupon R. Low phospholipid associated cholelithiasis: association with mutation in the MDR3/ABCB4 gene. *Orphanet J Rare Dis* 2007;2:29-34.
- [22] Ganne-Carrié N, Baussan C, Grando V, Gaudelus J, Cresteil D, Jacquemin E. Progressive familial intrahepatic

- cholestasis type 3 revealed by oral contraceptive pills. *J Hepatol* 2003;38:693-94.
- [23] Jung C, Driancourt C, Baussan C, Zater M, Hadchouel M, Meunier-Rotival M, et al. Prenatal molecular diagnosis of inherited cholestatic diseases. *J Pediatr Gastroenterol Nutr* 2007;44:453-58.
- [24] Wendum D, Barbu V, Rosmorduc O, Arrivé L, Fléjou JF, Poupon R. Aspects of liver pathology in adult patients with MDR3/ABCB4 gene mutations. *Virchows Arch*. 2012;460:291-8.
- [25] Lucena JF, Herrero JI, Quiroga J, Sangro B, Garcia-Foncillas J, Zabalegui N, et al. A multidrug resistance 3 gene mutation causing cholelithiasis, cholestasis of pregnancy, and adulthood biliary cirrhosis. *Gastroenterology* 2003;124:1037-42.
- [26] Gonzales E, Gerhardt MF, Fabre M, Setchell KD, Davit-Spraul A, Vincent I, et al. Oral cholic acid for hereditary defects of primary bile acid synthesis: a safe and effective long-term therapy. *Gastroenterology* 2009;137:1310-20.
- [27] Houdayer C, Dehainault C, Mattler C, Michaux D, Caux-Moncoutier V, Pages-Berhouet S, et al. Evaluation of in silico tools for decision making in molecular diagnosis. *Human Mut* 2008;29:975-82.
- [28] Liu C, Aronow BJ, Jegga AG, Wang N, Miethke A, Mourya R. Novel resequencing chip customized to diagnose mutations in patients with inherited syndromes of intrahepatic cholestasis. *Gastroenterology* 2007;132:119-26.
- [29] Chong CP, Mills PB, McClean P, Gissen P, Bruce C, Stahlschmidt J, et al. Bile acid-CoA ligase deficiency: a new inborn error of bile acid metabolism. *J Inher Metab Dis* 2012;35:521-30.
- [30] Cullinane AR, Straatman-Iwanowska A, Zaucker A, Wakabayashi Y, Bruce CK, Luo G, et al. Mutations in VIPAR cause an arthrogyrosis, renal dysfunction and cholestasis syndrome phenotype with defects in epithelial polarization. *Nat Genet* 2010;42:303-12.
- [31] Grosse B, Cassio D, Yousef N, Bernardo C, Jacquemin E, Gonzales E. Claudin-1 involved in neonatal ichthyosis sclerosing cholangitis syndrome regulates hepatic paracellular permeability. *Hepatology* 2012;55:1249-59.
- [32] Jacquemin E, Hermans D, Myara A, Habes D, Debray D, Hadchouel M, et al. Ursodeoxycholic acid therapy in pediatric patients with progressive familial intrahepatic cholestasis. *Hepatology* 1997;25:519-23.
- [33] Bustorff-Silva J, Sbraggia Neto L, Olímpio H, de Alcantara RV, Matsushima E, De Tommaso AM, et al. Partial internal biliary diversion through a cholecystojejunocolonic anastomosis: a novel surgical approach for patients with progressive familial intrahepatic cholestasis: a preliminary report. *J Pediatr Surg* 2007;42:1337-40.
- [34] Stapelbroek JM, van Erpecum KJ, Klomp LW, Venneman NG, Schwartz TP, van Berge Henegouwen GP, et al. Nasobiliary drainage induces long-lasting remission in benign recurrent intrahepatic cholestasis. *Hepatology* 2006;43:51-3.
- [35] De Vree JML, Ottenhoff R, Bosma PJ, Smith AJ, Aten J, Oude Elferink RPJ. Correction of liver disease by hepatocyte transplantation in a mouse model of progressive familial intrahepatic cholestasis. *Gastroenterology* 2000;119:1720-30.
- [36] Boyer JL. Nuclear receptor ligands: rational and effective therapy for chronic cholestatic liver disease *Gastroenterology* 2005;129:735-40.
- [37] Trauner M, Wagner M, Fickel P, Zollner G. Molecular regulation of hepatobiliary transport systems. Clinical implications for understanding and treating cholestasis. *J Clin Gastroenterol* 2005;39:S111-24.
- [38] Gonzales E, Jacquemin E. Mutation specific drug therapy for progressive familial or benign recurrent intrahepatic cholestasis: a new tool in a near future? *J Hepatol* 2010;53:385-7.
- [39] Gonzales E, Grosse B, Cassio D, Davit-Spraul A, Fabre M, Jacquemin E. Successful mutation-specific chaperone therapy with 4-phenylbutyrate in a child with progressive familial intrahepatic cholestasis type 2. *J Hepatol* 2012 May 16. [Epub ahead of print]
- [40] Lysy PA, Najimi M, Stephenne X, Bourgois A, Smets F, Sokal EM. Liver cell transplantation for Crigler-Najjar syndrome type I: update and perspectives. *World J Gastroenterol* 2008;14:3464-70.
- [41] Knisely AS, Strautnieks SS, Meier Y, Stieger B, Byrne JA, Portmann BC, et al. Hepatocellular carcinoma in ten children under five years of age with bile salt export pump deficiency. *Hepatology* 2006;44:478-86.
- [42] Lemoine M, Revaux A, Francoz C, Ducarme G, Brechignac S, Jacquemin E, et al. Albumin liver dialysis as pregnancy-saving procedure in cholestatic liver disease and intractable pruritus. *World J Gastroenterol* 2008;14:6572-4.
- [43] Scheimann AO, Strautnieks SS, Knisely AS, Byrne JA, Thompson RJ, Finegold MJ. Mutations in bile salt export pump (ABCB11) in two children with progressive familial intrahepatic cholestasis and cholangiocarcinoma. *J Pediatr* 2007;150:556-9.
- [44] Van Mil SWC, Milona A, Dixon PH, Mullenbach R, Geenes VL, Chambers J, et al. Functional variants of the central bile acid sensor FXR identified in intrahepatic cholestasis of pregnancy. *Gastroenterology* 2007;133:507-16.
- [45] Paulusma ML, Folmer DE, Ho-Mok KS, de Waart DR, Hilarius PM, Verhoeven AJ, et al. ATP8B1 requires an accessory protein for endoplasmic reticulum exit and plasma membrane lipid flippase activity. *Hepatology* 2008;47:268-78.
- [46] Chen XQ, Wang LL, Shan QW, Tang Q, Deng YN, Lian SJ, Yun X. A novel heterozygous NR1H4 termination codon mutation in idiopathic infantile cholestasis. *World J Pediatr* 2012;8:67-71.
- [47] Wakabayashi Y, Dutt P, Lippincott-Schwartz J, Arias IM. Rab11a and myosin Vb are required for bile canalicular formation in WIF-B9 cells. *Proc Natl Acad Sci U S A* 2005;102:15087-92.
- [48] Keitel V, Vogt C, Häussinger D, Kubitz R. Combined mutations of canalicular transporter proteins cause severe intrahepatic cholestasis of pregnancy. *Gastroenterology* 2006;131:624-9.
- [49] Ortiz D, Arias IM. MDR3 mutations: A glimpse into Pandora's box and the future of canalicular pathophysiology. *Gastroenterology* 2001;120:1549-52.
- [50] Maggiore G, Gonzales E, Sciveres M, Redon MJ, Grosse B, Stieger B, et al. Relapsing features of bile salt export pump deficiency after liver transplantation in two patients with progressive familial intrahepatic cholestasis type 2. *J Hepatol* 2010;53:981-6.
- [51] Cutillo L, Najimi M, Smets F, Janssen M, Reding R, de Ville de Goyet J, et al. Safety of living-related liver transplantation for progressive familial intrahepatic cholestasis. *Pediatr Transplant* 2006;10:570-74.