

Simplified Access for Division of the Low Cervical/High Thoracic H-Type Tracheoesophageal Fistula

By Albert Ko, Frederic R. DiTirro, Paul A. Glatleider, and Harry Applebaum
Los Angeles, California

H-type tracheoesophageal fistulas (H-TEF) often are located in the low cervical/high thoracic region where determination of the most appropriate surgical approach is difficult. When it can provide adequate exposure, a cervical incision is preferred because of the likelihood of decreased morbidity. A child with VACTERL association presented with recurrent respiratory problems. Esophagogram showed an H-TEF below the level of the clavicle. A vascular guide wire was placed through the H-TEF with the ends brought out through the

mouth. Under fluoroscopic guidance, gentle traction was placed on the wire to bring the fistula into the neck for an easily accessible cervical exposure, thus eliminating the need for a thoracotomy.

J Pediatr Surg 35:1621-1622. Copyright © 2000 by W.B. Saunders Company.

INDEX WORDS: Tracheoesophageal fistula, guide wire, fluoroscopy, cervical incision.

THE APPROPRIATE surgical approach to an H-type tracheoesophageal fistula (H-TEF) is difficult to determine. The passage of a guide wire through the fistula has been recommended for both palpation and fluoroscopic localization of the communication.¹⁻³ Once localized, if the lesion is at or above T₂, the preferred operative exposure is via a cervical incision, whereas below that level a thoracotomy is suggested.⁴⁻⁶ However, many are located in the vicinity of the thoracic inlet where exposure is not optimal via either incision.⁷ We theorized that an H-TEF can be repositioned into a higher, more favorable cervical location for division.

CASE REPORT

A 15-month-old boy with VACTERL association, status post repair of a ventricular septal defect, presented with a history of persistent coughing, choking, emesis, and pneumonias. An esophagogram showed a H-TEF at the T₁ to T₂ level (Fig 1). Bronchoscopy was performed under general anesthesia. In the region of visualized bubbles, an angled 0.035-inch gauge soft tip flexible Glidewire (Boston Scientific Corporation, Watertown, MA) was passed through the fistula into the esophagus and retrieved with an esophagoscope, thus creating a "U" with both ends exiting the mouth. Utilizing fluoroscopy, gentle traction on both ends of the guide wire with the neck extended showed easy mobilization of the fistula into the cervical region (Fig 2). A fluoroscopically directed limited left cervical incision allowed for easy palpation, identification, and division of the fistula. The patient did well postoperatively.

DISCUSSION

Accessing and identifying the H-TEF often is difficult. Procedures used to identify the H-TEF intraoperatively have progressed from simple bronchoscopy or esophagoscopy, to the passage of rubber catheters through the fistula, to the current practice of using guide wires.^{1-3,6,8} Garcia et al² recently combined the guide wire technique with fluoroscopy for simplified identification of the H-TEF.

Our procedure continues the evolution of this concept. Because of the inherent mobility of the infant trachea and esophagus, traction placed on the guide wire with the neck extended under fluoroscopic guidance helped move the fistula from the low thoracic inlet into a more easily accessible cervical location. A small cervical incision could then be precisely placed directly over the fistula. This facilitated a limited dissection with decreased chance of damage to adjacent structures, particularly the recurrent laryngeal nerves.

The vascular Glidewire is ideal for this procedure because of a smooth hydrophilic coating that prevents tissue injury from friction, a soft angled tip that facilitates fistula cannulation, and an adequate thickness that allows for easy palpation, although other similar guide wires can be used in the same manner.

Traction on a guide wire placed through an H-TEF with the neck extended is a quick and easy maneuver to enable an easier and safer surgical approach for this anomaly. The indications for this method likely can be expanded to incorporate lower-lying lesions by increasing the applied traction under fluoroscopic guidance.

From the Departments of Surgery and Head and Neck Surgery, Kaiser Permanente Medical Center, Los Angeles, CA.

Presented at the 33rd Annual Meeting of the Pacific Association of Pediatric Surgeons, Las Vegas, Nevada, May 15-19, 2000.

Address reprint requests to Harry Applebaum, MD, Department of Surgery, Kaiser Permanente Medical Center, 4747 Sunset Blvd, Los Angeles, CA 90029.

Copyright © 2000 by W.B. Saunders Company

0022-3468/00/3511-0021\$03.00/0

doi:10.1053/jpsu.2000.18332

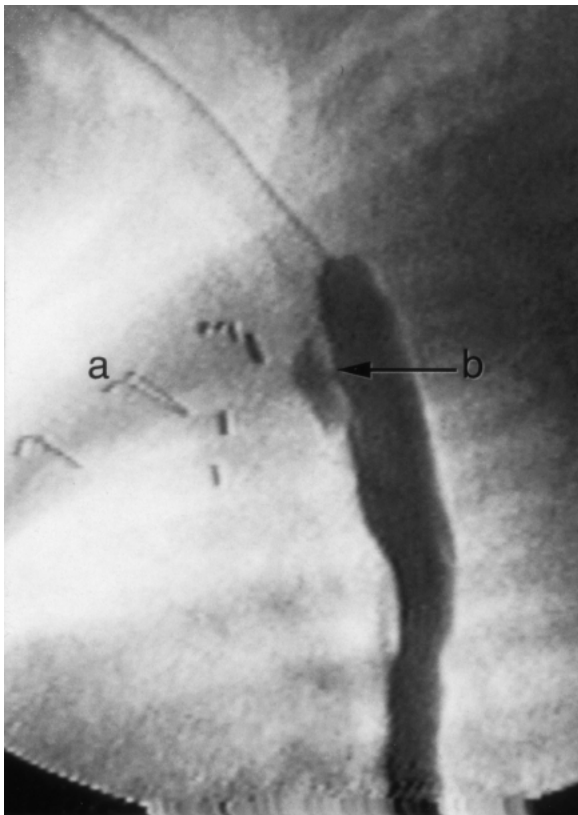


Fig 1. Preoperative esophagogram shows the uppermost sternal closure wire (a) and a tracheoesophageal fistula (b) located at the T₁ to T₂ level.

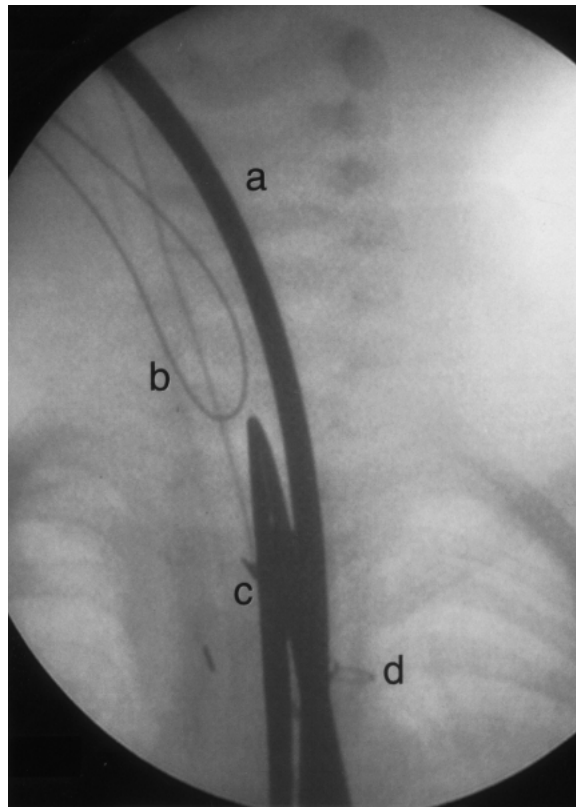


Fig 2. Intraoperative fluoroscopic images show an intraesophageal bougie (a), guide wire placed passing through the fistula (b), clamp designating location of skin incision (c), and the uppermost sternal closure wire (d). The most inferior aspect of the guide wire corresponds to the level of the fistula. With the neck flexed and gentle traction placed on the guide wire, a move of approximately 4 vertebral bodies is shown.

REFERENCES

- Holman WL, Vaezy A, Postlethwait RW, et al: Surgical treatment of H-type tracheoesophageal fistula diagnosed in an adult. *Ann Thorac Surg* 41:453-454, 1986
- Garcia NM, Thompson JW, Shaul DB: Definitive localization of tracheoesophageal fistula using bronchoscopy and esophagoscopy for guide wire placement. *J Pediatr Surg* 33:1645-1647, 1998
- Kirks DR, Briley CA, Currarino G: Selective catheterization of tracheoesophageal fistula. *AJR* 133:763-764, 1979
- Yazbeck S, Dubuc M: Congenital tracheoesophageal fistula without esophageal atresia. *Can J Surg* 26:239-241, 1983
- Karnak I, Senocak ME, Hicsonmez A, et al: The diagnosis and treatment of H-type tracheoesophageal fistula. *J Pediatr Surg* 32:1670-1674, 1997
- LaSalle AJ, Andrassy RJ, Ver Steeg K, et al: Congenital tracheoesophageal fistula without esophageal atresia. *J Thorac Cardiovasc Surg* 78:583-588, 1979
- Andrassy RJ, Ko P, Hanson BA, et al: Congenital tracheoesophageal fistula without esophageal atresia. *Am J Surg* 140:731-733, 1980
- Gans SL, Johnson RO: Diagnosis and surgical management of "H-Type" tracheoesophageal fistula in infants and children. *J Pediatr Surg* 12:233-236, 1977