

Chapter 10

Adrenalectomy

Are there Points Specific to Laparoscopic Pheochromocytoma Surgery?	147
What are Some Pointers to Identify the Adrenal Vein During Laparoscopy?	148
What are the Key Technical Maneuvers During a Laparoscopic Transperitoneal Adrenalectomy?	149
During Laparoscopic Adrenalectomy, How do You Identify the Adrenal Veins?	152
Any Tips for Laparoscopic Adrenalectomy?	153
Any Techniques and Tips for Partial Adrenalectomy?	154
Reference	155

Are there Points Specific to Laparoscopic Pheochromocytoma Surgery?

Dr. Gill

An excellent preoperative medical preparation of the patient is the key. We typically optimize the patient with calcium channel blockers, with secondary use of alpha-

1 blockers and beta blockers in select circumstances. Cardiovascular clearance is essential. Vigorous intravenous hydration, early control of the adrenal vein, and minimal handling of the tumor are essential aspects of surgery. If adequate experience with retroperitoneoscopy is not available, the transperitoneal approach should be preferred in that circumstance. At our institution, we would approach the adrenal pheochromocytoma either transperitoneally or retroperitoneally without any general preference for either approach. Another key approach to adrenal surgery is to stay outside the periadrenal fat, thereby minimizing or completely avoiding handling of the adrenal gland per se, which will uniformly lead to adrenal gland fracture with troublesome hemorrhage.

What are Some Pointers to Identify the Adrenal Vein During Laparoscopy?

Dr. Suzuki

On the left side, it is important to secure wide exposure of the adrenal gland by adequately mobilizing the spleen. This is done by dividing the peritoneal attachments of the spleen all the way to the greater curvature of the stomach. We endeavor always to mobilize the spleen in this manner, because once so mobilized, the spleen falls away from the operative field and provides excellent exposure of the upper pole of the kidney and adrenal.¹

Initially, we do not seek the adrenal vein itself. We identify the landmarks around the upper pole of the

kidney, including the diaphragm, transversus muscle, and quadratus lumborum muscle; and medial to the adrenal, the posterior surface of the pancreas is identified. Following delineation of the above structures, the adrenal vein can be identified. However, if the adrenal vein is to be identified early, we dissect close to the renal hilum, opening the Gerota's fascia. The renal vein can be then identified and then the adrenal vein along its upper border. But, unless indicated, my preference is to dissect and secure the adrenal vein last; as otherwise, it can lead to congestion of the adrenal gland.

On the right side, it is fairly easy to identify the adrenal vein. As on the left side, we initially identify and demarcate the other structures near the superior pole of the kidney including the diaphragm, transversus muscle, quadratus lumborum muscle, and medially the inferior vena cava. The vena cava is an important landmark. The short hepatic vein that drains into the vena cava is a good guide to the adrenal vein, as it lies very close to it and is almost at the same level. But similar to the left side, we prefer to dissect the adrenal vein following the dissection of the gland itself.

What are the Key Technical Maneuvers During a Laparoscopic Transperitoneal Adrenalectomy?

Dr. Gill

The single-most-important thing for me is the anatomic fact that the left main adrenal vein exits the infero-

clipped and divided. At this point, the aim is to identify the psoas muscle immediately posterior to the clip and transected left adrenal vein. Thus, using an atraumatic grasper in the left hand, the adrenal gland is retracted anterolaterally and, using a hook electrode, the fibro fatty tissue along the inferomedial edge of the adrenal gland is divided until the psoas muscle is identified. Now all that remains is taking down the medial attachments of the adrenal gland to the aorta and the inferior attachments of the adrenal gland to the renal hilum. Occasionally, significant-sized adrenal vessels can be encountered which need specific attention. Thus, the key on the left side is to secure and transect the left adrenal vein, and identify the psoas muscle at that location thereby retracting the adrenal laterally and placing its remaining attachments on stretch.

On the right side, the key anatomic fact is that the right main adrenal vein exits the superomedial aspect of the adrenal gland and runs obliquely in a cephalad direction to enter the vena cava. Thus, the right adrenal vein is quite high immediately under the liver. As such, any smaller blood vessels encountered lower down along the medial aspect of the adrenal gland are likely not the main adrenal vein. The initial key aspect is to make the transverse peritoneotomy higher, 1 cm below and parallel to the undersurface of the liver (Figure 10.2). This will allow you to land on the adrenal gland directly. Thereafter, the right lateral edge of the inferior vena cava is visualized, the adrenal gland dissected and retracted laterally from it, and careful dissection performed in a cephalad manner to control the adrenal vein.

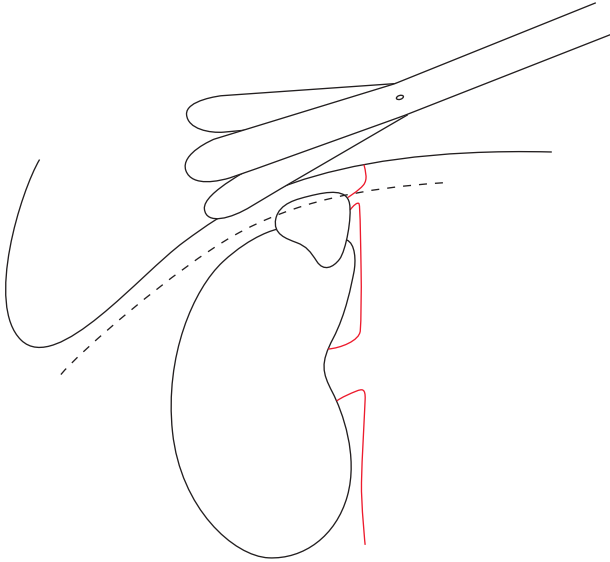


Fig. 10.2 Locating the right adrenal gland.

During Laparoscopic Adrenalectomy, How do You Identify the Adrenal Veins?

Dr. Ono

We have had only about 100 cases during the last ten years. We usually use the transperitoneal approach. On left side, we divide the peritoneum and then reflect the descending colon from the anterior aspect of the kidney and the renal vein is identified. This exposes the anterior surface of the adrenal and also leads us to the adrenal vein. We use medium-size metal clips across the adrenal vein before dividing it. On the right side disease also we use the anterior approach. We divide the peritoneum

between the liver and the kidney and then make an additional incision alongside the inferior vena cava. The upper half of the kidney is exposed. The liver is retracted with a retractor. The renal vein is easily identified draining into the vena cava. Then dissecting along the vena cava to the liver, we can find right adrenal gland. It is important to identify the inferior vena cava first and also the right renal vein.

Any Tips for Laparoscopic Adrenalectomy?

Dr. Kaouk

The retroperitoneal approach is the approach of choice for adrenal masses with a significant retrocaval component.

Fat planes surrounding the adrenal mass should be inspected on preoperative CT or MRI. Presence of such surrounding fat is an indication of preserved planes and absence of local invasion to surrounding organs.

Dr. Stoller

During laparoscopic adrenalectomy, there is no need routinely to identify the adrenal artery. Adrenal arteries are usually arborizations of vessels that come from a variety of areas. In over 280 laparoscopic adrenalectomies, we have only identified a discrete adrenal artery two or three times that required formal ligation. The vast

majority could just be dissected with a hook cautery or the harmonic scalpel.

When I do a laparoscopic adrenalectomy on the left side, I go from the upper left and come down and open it up like a book. On the right side, I dissect the upper edge from underneath the liver, going down to the vena cava and then clip the adrenal veins. On the right side, there is a 10% incidence of an aberrant adrenal vein coming directly from the liver into the adrenal. Therefore, on the right side one needs to be cautious, not of an adrenal artery, but of an aberrant adrenal vein going directly into the liver. It is important not to lose control of that vein but to use a harmonic scalpel or a formal clip ligation to secure it.

Additionally, for large adrenal masses that extend posterior to the renal hilum, one needs to be careful that one does not accidentally transect a segmental renal artery thinking that it is the adrenal artery. Adrenal arteries are the exception and not the rule and rarely need to be formally ligated.

Any Techniques and Tips for Partial Adrenalectomy?

Dr. Suzuki

When the tumor or lesion is located in the peripheral region of the adrenal gland, performing partial adrenalectomy is usually straightforward. Following exposure of the adrenal gland (there is no need to dissect or control the adrenal vein) we excise the mass lesion using

the ultrasonic scalpel to divide the normal adrenal tissue. If bleeding is encountered, it can be controlled with bipolar forceps.

If a tumor is located close to the main adrenal vein, one can still perform partial adrenalectomy, as by preserving the superior adrenal veins/arteries, the function of the adrenal gland can still be preserved.

In patients with primary aldosteronism, recent reports suggest that in many cases, there is persistence of overactivity of the gland despite excision of the adenoma by partial adrenalectomy. This is felt to be due to the presence of microadenomas that may not have been appreciated on pre-operative imaging. We, therefore, have moved away from partial adrenalectomy in patients with primary hyperaldosteronism and instead perform total adrenalectomy.

Partial adrenalectomy is best indicated in patients with pheochromocytoma when associated with MEN type 2 disease (because of the high incidence of bilaterality in such cases).

Reference

1. Suzuki, K., Kageyama, S., Hirano, Y., et al.: Comparison of 3 surgical approaches to laparoscopic adrenalectomy: a nonrandomized, background matched analysis. *J Urol* **166**: 437, 2001