

# Congenital Esophageal Stenosis: Therapeutic Strategy Based on Etiology

By Shigeru Takamizawa, Chikara Tsugawa, Naruaki Mouri, Shiiki Satoh, Kimio Kanegawa,  
Eiji Nishijima, and Toshihiro Muraji  
Kobe, Japan

**Background/Purpose:** The diagnosis and treatment of congenital esophageal stenosis (CES) can be a vexing clinical problem. This study aims at determining the ideal therapeutic strategy for the management of CES.

**Methods:** Medical records of patients with CES were reviewed retrospectively with regard to diagnostic method, therapy, and outcome.

**Results:** During the last 29 years, 36 patients, aged 1 month to 9 years, were found to have CES. Diagnosis was made by fluoroscopy, esophagoscopy, endoscopic ultrasonography (EUS), and pathologic examination. Of the 36 patients, 15 had tracheobronchial remnants (TBR), 13 had fibromuscular stenosis (FMS), 5 had membranous stenosis (MS), and 3 had multiple stenoses (MPS). EUS was diagnostic in distinguishing TBR from FMS. All patients with TBR underwent operative repair in which 13 patients had resection and anastomosis with or without preoperative dilation. The 14th patient had enucleation and the 15th underwent myotomy. Postoperative dilation was needed 2.2 times for 2.1 months on

average in this group of patients. Ten patients with FMS were treated by dilation only (a mean of 4.7 dilations was required for a duration of 2.6 years), whereas 3 patients underwent open surgical intervention. Most patients with MS or MPS were treated by dilation (with or without endoscopic resection of the membranes), whereas 2 patients had surgical intervention. All patients in this study are doing well after a mean follow-up period of 5.3 years (range, 0.5 to 25 years) without any further operative interventions.

**Conclusions:** If the etiologic diagnosis of CES is unclear, EUS is useful in distinguishing TBR from FMS. This distinction is critical, because patients with TBR should undergo surgical resection, whereas most cases of FMS, MS, and MPS can be treated with esophageal dilation alone.

*J Pediatr Surg 37:197-201. Copyright © 2002 by W.B. Saunders Company.*

**INDEX WORDS:** Esophageal stenosis, congenital, therapeutic strategy.

**C**ONGENITAL ESOPHAGEAL STENOSIS (CES) is a rare clinical condition of childhood. The definitive preoperative diagnosis often is difficult to make, and the ideal therapeutic strategy remains controversial. We reviewed retrospectively the medical charts of patients with congenital esophageal stenosis, with the intention of defining the ideal therapeutic strategy for the management of CES.

## MATERIALS AND METHODS

### *Patient Characteristics*

From 1972 to 2001, 36 patients had CES diagnosed at Kobe Children's Hospital. The patients ranged in age from 1 month to 9 years, and the average age at diagnosis was 1.8 years. Symptoms started at 7.4 months of age on average. There were 21 boys and 15 girls in this series, and associated anomalies were found in 17 patients (47%). These were esophageal atresia with distal tracheoesophageal fistula (EA/TEF; n = 13), tracheomalacia with or without subglottic stenosis (n = 2), esophageal hiatal hernia (n = 2), imperforate anus (rectourethral fistula; n = 1), ventricular septal defect (n = 1), vesicoureteral reflux (n = 1), Goldenhar syndrome (n = 1), and Down's syndrome (n = 2). Of the 36 patients with CES, the type of stenosis was classified: (1) tracheobronchial remnants (TBR, n = 15); (2) fibromuscular stenosis (FMS, n = 13); (3) membranous stenosis (MS, n = 5); and (4) multiple stenoses (MPS, n = 3). Twenty-nine patients

(81%) presented with dysphagia or vomiting, and 3 patients (8%) presented with respiratory distress. Four patients (11%) had CES diagnosed on follow-up esophagram after repair of esophageal atresia before clinical symptoms developed. In all patients with CES and EA/TEF repair, the narrowing segment caused by CES is separate from the site of esophageal anastomosis.

### *Diagnostic Methods*

All patients suspected of having CES underwent barium esophagram to confirm the diagnosis of CES (Fig 1). In this study, all but one patient received a correct diagnosis for the type of stenosis by preop-

*From the Departments of Surgery and Radiology, Kobe Children's Hospital, Kobe, Japan and Yamanashi Medical University, Yamanashi, Japan.*

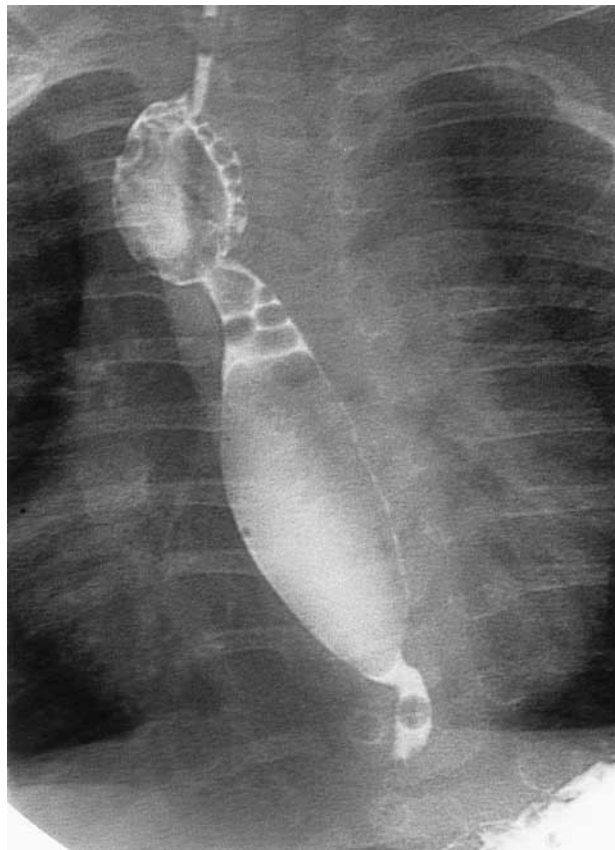
*Presented at the 48th Annual International Congress of the British Association of Paediatric Surgeons, London, England, July 18-21, 2001.*

*Address reprint requests to Shigeru Takamizawa, MD, Department of Surgery, Kobe Children's Hospital, 1-1-1, Takakuradai, Suma-ku, Kobe, 654-0081, Japan.*

*Copyright © 2002 by W.B. Saunders Company*

*0022-3468/02/3702-0011\$35.00/0*

*doi:10.1053/jpsu.2002.30254*



**Fig 1.** The barium esophagram shows an abrupt narrowing of the lower esophagus with dilatation above it. The mild anastomotic stenosis after esophageal atresia repair also is seen at the upper esophagus.

erative esophagram and esophagoscopy with or without endoscopic ultrasonography (EUS: EU-M30S, OLYMPUS Co, Tokyo, Japan; 12 MHz [UM2R] and 20 MHz [UM3R]; Fig 2). The single patient with MS who was misdiagnosed as TBR by esophagram, underwent surgery. In this case, definitive diagnosis was made by histopathologic examination which showed cartilaginous material within the esophageal wall (Fig 3).

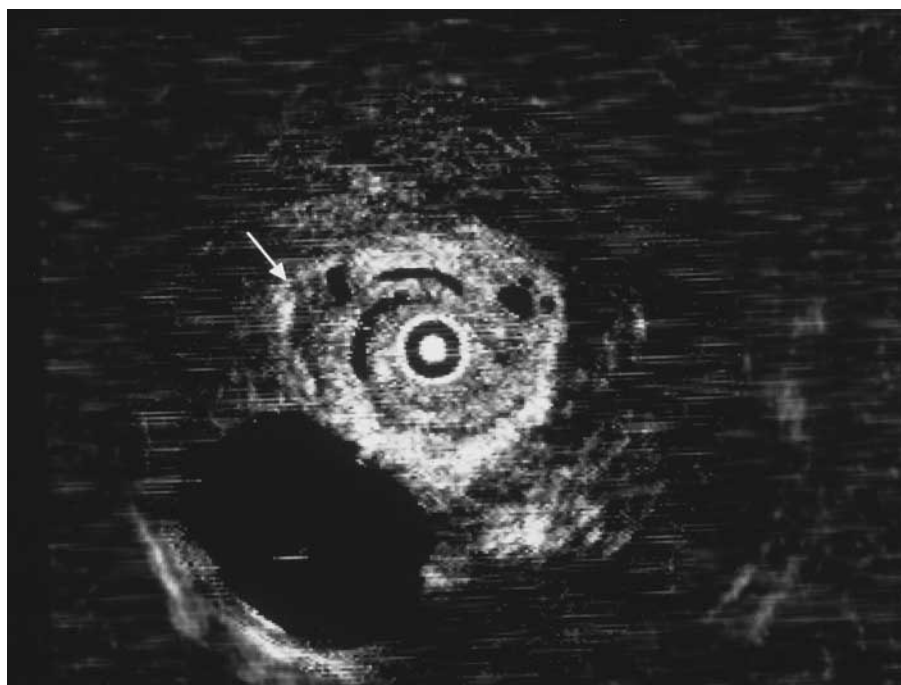
### *Esophageal Dilation*

Esophageal balloon dilation was performed under general endotracheal anesthesia with muscle relaxation. Patients were placed in the left lateral position and a flexible fiberscope (GIF type-PQ 20; OLYMPUS) was introduced. The polyethylene terephthalate (PET) balloon (Bard ELIMINATOR Esophageal PET Balloon Dilator, Bard, Inc, Billerica, MA) was inserted through the side channel and was inflated with air for a duration of 5 to 10 minutes depending on the degree of the stenosis. After dilation, the esophageal wall was examined for laceration or perforation. Balloon dilation was performed only when the patients presented with symptoms.

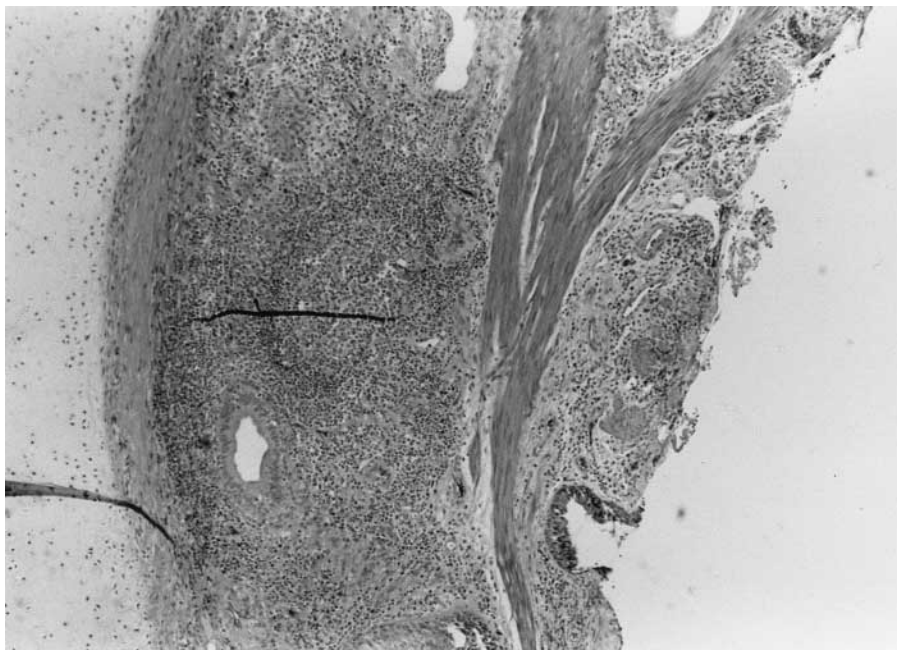
### *Surgical Intervention*

Resection of the tracheobronchial remnants was performed through left posterolateral thoracotomy (sixth to eighth intercostal space was used depending on the location of the stenosis). The stenotic lesion was detected by palpation with assistance of the fiberoptic scope introduced through the mouth. A limited esophageal resection was performed followed by a 2-layer end-to-end primary anastomosis.

Similarly, esophageal myotomy for fibromuscular stenosis was performed through a left posterolateral thoracotomy. The lesion was confirmed macroscopically with assistance of the fiberoptic scope. Once the fibromuscular stenosis was confirmed, a nasogastric tube was inserted, and a longitudinal myotomy was accomplished.



**Fig 2.** The EUS shows that a sonolucent area (arrow) in the 4th layer, which shows cartilaginous component in the muscle layer.



**Fig 3.** The resected specimen contains cartilaginous tissue within the esophageal wall (left: H & E, original magnification  $\times 100$ ).

## RESULTS

### *Tracheobronchial Remnants*

All patients with TBR underwent operative repair in which 13 patients had resection of the stenotic region and end-to-end esophageal anastomosis. One patient underwent enucleation of the tracheobronchial remnants, and, in this particular case, enucleation rather than resection was performed because the tracheobronchial remnants were localized and not encircling the esophageal wall. In the remaining patient who underwent myotomy, the stenotic region seemed to be a narrow fibrous band encircling the lower esophagus without any palpable mass inside. Four of 15 patients with TBR underwent dilatation (preoperative range, 1 to 5 times) for 0.5 years in average. On average postoperative dilatation was needed 2.2 times (range, 0 to 9) for 2.1 months (0 to 9 months). One patient underwent esophageal hiatal hernia repair 3 years after the operation for CES. The total duration of therapy including operative repair plus pre- and/or postoperative esophageal dilatation was 0.7 years in average (range, 1 month to 5 years). No patient required further operative intervention.

### *Fibromuscular Stenosis*

Ten of 13 patients with FMS were treated by dilatation alone (4.7 dilations were required for a duration of 2.6 years on average). Three patients with FMS underwent open surgical intervention (myotomy through thoracotomy,  $n = 2$ ; resection of the stenosis followed by

end-to-end esophageal anastomosis,  $n = 1$ ) because dilations were ineffective (3.0 preoperative dilations were performed within 1.8 years on average). Two of the 3 surgically treated patients underwent postoperative dilatation.

### *Membranous Stenosis*

Four of 5 patients with MS were treated by dilatation alone (1.5 dilations were required for a duration of 0.6 years on average). Two of 4 patients who were treated with dilatation alone underwent endoscopic partial resection of the membranes at the time of dilatation. One patient diagnosed as having TBR preoperatively underwent resection of the stenosis and end-to-end esophageal anastomosis through thoracotomy followed by dilatation. This patient had MS diagnosed by postoperative pathologic examination.

### *Multiple Stenoses*

Two of 3 patients with MPS were treated by esophageal balloon dilatation alone with partial resection of the membranous diaphragm by endoscopic CO<sub>2</sub> laser (Mochida Ltd, Tokyo, Japan; a mean of 6.5 dilations was required for a duration of 2.5 years). The remaining patient underwent cardioplasty via a laparotomy, because the stenosis was severe, followed by esophageal dilatation. Six separate dilations were required for 9 years for the stenoses and the repaired esophagogastric junction.

All patients in this study are doing well after a mean follow-up period of 5.3 years (range, 0.5 to 25 years)

without any further operative interventions or major complications.

### DISCUSSION

The classification of CES has been confusing because of its infrequent presentation (approximately 1 in 25,000 to 50,000 live births) and the difficulty of discriminating this anomaly from esophageal strictures secondary to inflammation and gastroesophageal reflux.<sup>1,2,3</sup> The definition and classification of CES proposed by Nihoul-Fékété et al<sup>4</sup> are perhaps the clearest. They stated that CES is defined as an intrinsic stenosis of the esophagus, present at birth, and associated with congenital malformation of the esophageal wall architecture. This classification delineates 3 forms of CES: (1) tracheobronchial remnants, (2) fibromuscular stenosis, and (3) a membranous diaphragm in the wall of the esophagus. In 2001, Ramesh et al<sup>5</sup> proposed a new classification based on the type of stenosis and the association of segmental stenosis with other anomalies of foregut separation. In this classification, multiple stenoses were included. Because the therapeutic approach to CES depends on the etiology, a correct diagnosis of the exact type of stenosis is mandatory.

In our current review, dilation was found to be ineffective in all patients with TBR, and all these patients eventually underwent operative repair. Based on our results and those of previous reports, it is apparent that TBR must be treated by surgical excision, either by resection of the stenotic region followed by end-to-end anastomosis, or by enucleation of the cartilaginous remnants. Standard preoperative diagnostic studies occasionally are inadequate for distinguishing TBR from FMS. It was reported that the diagnosis of TBR in most cases is made by histopathologic study of the stenotic region.<sup>6</sup> On fluoroscopy, TBR shows an abrupt narrowing of the esophagus, whereas FMS shows a more gradual, regular and well-centered narrowing. Although these typical findings are noted, both types of stenosis exist in the lower third of the esophagus, and fluoroscopy does not always show typical findings. We could not obtain precise preoperative diagnosis by fluoroscopy and esophagoscopy in 5 patients. In these 5 cases, endoscopic ultrasonography (EUS) was found to be useful for distinguishing TBR from FMS. EUS can visualize a sonolucent area in the fourth layer that shows a cartilaginous component in the muscle layer. Histopathology confirmed the aberrant cartilaginous remnants in all EUS-positive patients.

Because most cases of TBR exist in the lower third of the esophagus, a left thoracotomy is recommended. At exploration, it is important to identify the location of the TBR. Palpation by a surgeon is helpful. To confirm our

intraoperative suspicion, we used flexible esophagoscopy during the operation.<sup>7</sup> This enabled inspection of the stenotic portion where the light of the esophagoscope could be seen through the esophageal wall.

The use of longitudinal myotomy for FMS is still unclear. We performed myotomy in 1 patient with TBR and in 2 patients with FMS. Esophageal perforation developed after myotomy in one of the patients with FMS. Two of 3 patients who underwent myotomy required postoperative esophageal dilations.

In most of our patients with FMS, esophageal dilation was effective. Ten of 13 patients with FMS were treated successfully by bouginage or balloon dilation alone without any major complications except one patient in whom esophageal perforation developed. Although antegrade and retrograde tapered dilators were the traditional form of bouginage, we have used balloon dilation that we feel is more effective and safer than bouginage. With the PET balloon, expanding force is transmitted only to the stenotic segment of the esophagus, and correct placement of the balloon can be determined by direct endoscopic visualization. Preoperative dilation was ineffective in 3 patients who eventually required surgery. We recommend that if dilations are required within 6-month intervals and remain ineffective after 3 years, surgical intervention should be undertaken.

In patients with membranous stenosis, we believe that balloon dilation is the treatment of choice. Incision or partial resection of the diaphragm may be added to the esophageal dilation if the stenosis is severe, and the balloon cannot be passed through the stenotic portion. We prefer the CO<sub>2</sub> laser for incising the membranous diaphragm. Although some investigators recommend resection of the web and primary anastomosis, we believe that balloon dilations and endoscopic incision of the membrane (as needed) are the treatment of choice.<sup>4,8</sup>

Multiple stenoses consist of membranous stenosis and fibromuscular stenosis. Both membranous and fibromuscular stenosis could be treated by esophageal dilations alone based on our experience. We operated on one patient with MPS by cardioplasty for severe fibromucular hypertrophy just above the esophagogastric junction. In this particular case, preoperative fluoroscopy suggested a TBR and was treated early in our series.

Precise preoperative diagnosis of CES is important because the type of stenosis determines the modality of treatment. EUS is useful for detecting the cartilaginous tissue and, thus, can distinguish TBR from FMS. TBR should be treated surgically, whereas most cases of FMS, MS, and MPS can be treated by esophageal dilation alone. If serial dilations are ineffective for FMS, MS, and MPS, surgical intervention should be considered.

## REFERENCES

1. Petit P, Borde J, Gubler JP, et al: Les rétrécissements congénitaux de l'oesophage. *Ann Chir Inf* 11:153-170, 1970
2. Ohkawa H, Takahashi H, Hoshino Y, et al: Lower esophageal stenosis in association with tracheobronchial remnants. *J Pediatr Surg* 10: 453-457, 1975
3. Nishina T, Tsuchida Y, Saito S: Congenital esophageal stenosis due to tracheobronchial remnants and its associated anomalies. *J Pediatr Surg* 16: 190-193, 1981
4. Nihoul-Fékété C, De Backer A, Lortat-Jacob S, et al: Congenital esophageal stenosis: A review of 20 cases. *Pediatr Surg Int* 2:86-92, 1987
5. Ramesh JC, Ramanujam TM, Jayaram G: Congenital esophageal stenosis: Report of three cases, literature review, and a proposed classification. *Pediatr Surg Int* 17: 188-192, 2001
6. Karagüzel G, Tanyel FC, Akçören Z, et al: Intramural tracheobronchial remnants associated with esophageal atresia: Diagnostic aids. *Pediatr Surg Int* 8:138-139, 1993
7. Murphy SG, Yazbeck S, Russo P: Isolated congenital esophageal stenosis. *J Pediatr Surg* 30: 1238-1241, 1995
8. Grabowski ST, Andrews DA: Upper esophageal stenosis: Two case reports. *J Pediatr Surg* 31: 1438-1439, 1996

## Discussion

*Dr De Agustin (Madrid, Spain):* Some of the congenital oesophageal stenosis has been proved to have an immunologic basis substrate. Have you performed any immunologic studies in your patients, and what are their results?

*S. Takamizawa (response):* We operated on 20 patients with congenital esophageal stenosis. Of them, 15 specimens from tracheobronchial remnants, 2 from fibromuscular stenosis, and 1 from multiple stenoses were obtained. Basically, we examined these specimens by ordinary H&E staining to confirm the type of stenosis, and no immunologic studies were performed. According to these results, we did not obtain any immunologic findings that cause esophageal stenosis. Does that answer your question?

*Dr De Agustin (Madrid, Spain):* No, the question is, have you performed any immunologic studies to try to

relate the congenital stenosis that responds to immunologic manipulation, for example, corticosteroids? Have you used any corticosteroids in any of your patients?

*S. Takamizawa (response):* We have not performed any studies to find immunologic causes related to esophageal stenosis. Besides, we have not used any materials such as corticosteroids to treat the esophageal stenosis.

*L. Kapila (Nottingham, England):* What about the motility postoperatively in these children. Does dilation solve it, or do you still have an incoordinate oesophagus?

*S. Takamizawa (response):* We have not evaluated the motility of the esophagus pre- and postoperatively. The patients with CES can eat ordinary food postoperatively. Those who were treated by balloon dilation alone sometimes show dysphagia that was resolved by balloon dilation. Presumably, the motility of the esophagus is not compromised with this disease.