

## BRIEF REPORT

# Interferon Alpha 2b Treatment in an Eleven-Year-Old Boy With Disseminated Lymphangiomas

Christian Timke, MD,<sup>1\*</sup> Martin F. Krause, MD,<sup>1</sup> Hans-Conrad Oppermann, MD,<sup>2</sup> Ivo Leuschner, MD,<sup>3</sup> and Alexander Claviez, MD<sup>1†</sup>

Disseminated lymphangiomas is a rare disease mostly observed in children and young adults. If no surgical removal can be achieved, the prognosis is poor, especially for patients with thoracic localization and pleural effusions. Next to pleural drainage, therapeutic options include radiotherapy, local, and systemic pharmacotherapy. An 11-year-old boy presented with disseminated lymphangiomas involving thorax with

massive pleural effusions, retroperitoneum, and bones. In immunohistochemical analysis, the tissue biopsy stained positive for vascular endothelial growth factor-receptor 3 (VEGFR-3). The patient has been treated with interferon alpha 2b for 2 years, and achieved a good clinical and radiological response. *Pediatr Blood Cancer* © 2005 Wiley-Liss, Inc.

**Key words:** interferon; lymphangiomas; vascular endothelial growth factor (VEGF)

### INTRODUCTION

Disseminated lymphangiomas is a rare disease mostly observed in children and young adults. It is represented by a benign proliferation of lymphatic vessels in contrast to a simple dilatation of preexisting lymphatic vessels as in lymphangiectasia [1]. Its histological features are widely spread endothelia forming spaces of few micrometers up to several centimeters in size, surrounded by only little connective tissue. The involved organs usually include thoracic and abdominal organs as well as the skeletal system, but almost any body parts may be affected except the central nervous system due to its lack of lymphatic vessels. The etiology of the disease is unknown, but it might be the result of an abnormal development of the lymphatic system [1].

If surgical resection of the tumor mass cannot be achieved, the overall prognosis is poor, especially for patients with thoracic localization when frequent pleural effusions impair pulmonary function. Next to drainage of the pleural space, therapeutic options are radiotherapy, local, and systemic pharmacological therapy including angiogenesis inhibitory substances [2]. Interferon has been successfully used in the treatment of patients with hemangioendothelioma [3–5]. It has also been reported as treatment for disseminated lymphangiomas in eight cases with positive results in five of them [6–11].

We present the case of an 11-year-old boy with disseminated lymphangiomas involving thorax, retroperitoneum, and bones who presented with massive pleural effusions and has been treated successfully with systemic administration of recombinant interferon alpha 2b (IFN- $\alpha$  2b).

### CASE REPORT

An 11-year-old boy had a medical record of hypoplasia of the right liver lobe and consecutive hyperplasia of the left lobe due to an intrahepatic blood vessel malformation, and partial infarction of the right lobe at the age of 4. He failed to thrive since he was 6 years old and suffered from malnutrition because of frequent regurgitation and vomiting. No definitive diagnosis was made at that time despite many consultations of the general practitioner and different hospitals. At the age of 8 years a computed tomography (CT) of the spine was carried out because of a progressive thoracic scoliosis and revealed hemangioma-like areas in several vertebrae of the lower thoracic spine. The patient was treated with physiotherapy only but with little success.

When he presented in our hospital at the age of 11 years, he suffered from severe dyspnea, abdominal pain, and facial edemas. Clinical examination revealed a pallor and almost no breath sounds over the left lung. The abdomen was hard and painful on palpation. Chest radiography,

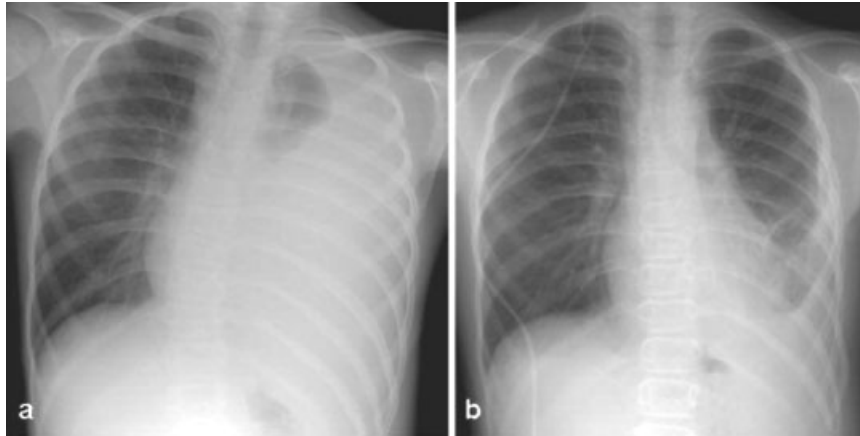
<sup>1</sup>Departments of Pediatrics, University of Kiel, Schwanenweg 20, Kiel, Germany

<sup>2</sup>Departments of Pediatric Radiology, University of Kiel, Schwanenweg 20, Kiel, Germany

<sup>3</sup>Departments of Pediatric Pathology, University of Kiel, Schwanenweg 20, Kiel, Germany

\*Correspondence to: Christian Timke, Department of Pediatrics, Childrens' Hospital, University of Kiel, Schwanenweg 20, 24105 Kiel, Germany. E-mail: ctimke@pediatrics.uni-kiel.de

Received 28 March 2005; Accepted 13 April 2005

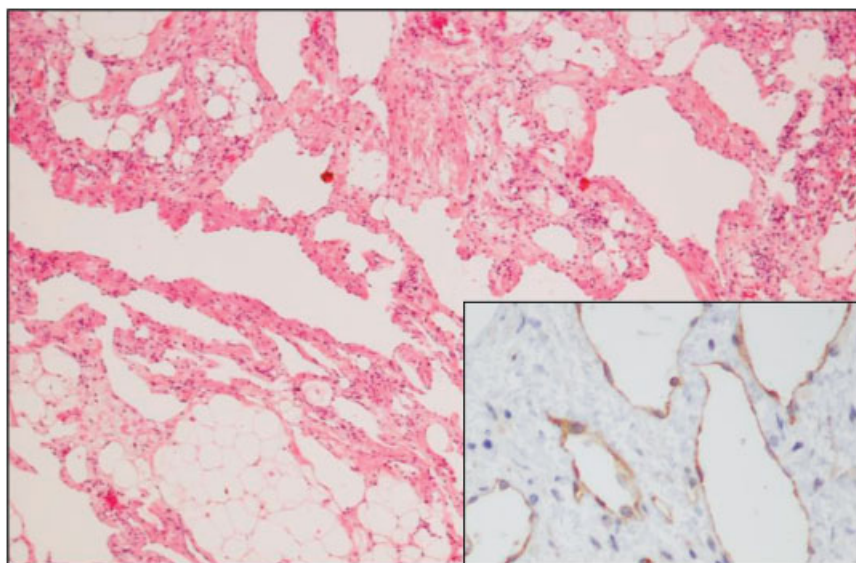


**Fig. 1.** Chest radiograph p.a. at the time of diagnosis (a) with extensive left-sided pleural effusion and only partial aeration of the upper lobe. Inhomogenous spongiosa within the left ribs X-XII, suggestive of skeletal manifestation of the underlying disease. Two years later (b) decreased pleural effusion and partially scarred pleura. Segments 8/9 on the left side and inferior lingula segment are still atelectatic.

sonography, and CT of the thorax showed a massive pleural effusion which almost entirely filled the left hemithorax as well as a dense structure adherent to the lower left thoracic wall (Fig. 1a). Sonography and CT of the abdomen showed ascites, splenomegaly, and disseminated hypodense tissue in the retroperitoneum. The boy underwent multiple thoracenteses, and pleural effusion culminated at 1.5 L per day. The fluid was identified as exudate containing 69 cells/ $\mu$ l (64% granulocytes, 36% lymphocytes), a protein concentration of 19 g/L, and a triglyceride concentration of 440 mg/L.

Since he had developed ascites and pleural effusions simultaneously, implantation of a pleuroperitoneal shunt

was not considered. Total parenteral nutrition with a low lipid fraction was started. Ascites and pleural effusion decreased but still remained at a level of about 100 ml per day. An explorative laparotomy was performed and revealed hypodense lymphatic tissue spreading through the retroperitoneum, the mesentery and epiploic appendices. Because of the infiltrative growth of this tissue and its vicinity to large blood vessels, surgical resection was impossible. A tissue specimen was excised for histological analysis. It consisted of multiple endothelial structures without surrounding smooth muscle cells and only little connective tissue. The vessels stained positive for CD31. In addition, the endothelia were strongly positive for



**Fig. 2.** Excisional biopsy with numerous spaces lined by flat endothelial cells (hematoxylin eosin staining) expressing vascular endothelial growth factor-receptor 3 (VEGFR-3) which is specific for lymphatic endothelium (Insert, monoclonal anti-VEGFR-3 antibody, streptavidin biotin complex).

vascular endothelial growth factor receptor 3 (VEGFR-3) as depicted in Figure 2.

During thoracotomy, the same tissue type was found in the lower left thorax. Talcum powder pleurodesis was performed without success. We then started treatment with 2 million IU/m<sup>2</sup> recombinant IFN- $\alpha$  2b injected subcutaneously 3 days a week and continued total parenteral nutrition with increasing lipid content.

The patient's general status gradually improved in the following months. The pleural effusion gradually decreased (Fig. 1b). Pulmonary function tests, which had previously shown a severe combined restrictive and obstructive pattern improved. The body weight caught up to normal, from 26 kg (3rd percentile) at the beginning of treatment to 39 kg (50th percentile) after 2 years. Moderate side effects of IFN- $\alpha$  2b including nausea, elevated body temperature, and mild headaches were observed in the first months of treatment. These side effects were effectively treated with acetaminophen and no dose modification of IFN- $\alpha$  2b was necessary. After 2 years of follow-up, the patient is now in good physical condition has returned to school and is able to take part in sports. IFN- $\alpha$  2b treatment continues while his parenteral nutrition is steadily reduced.

## DISCUSSION

Disseminated lymphangiomas are characterized by diffuse proliferation and dilatation of lymphatic vessels in multiple organs or body regions. Recent classifications differentiate lymphangiomas from similar diseases, such as lymphangioma, lymphangiectasis, and lymphatic dysplasia syndrome [1]. Due to unspecific symptoms, the diagnosis is often delayed especially if typical radiological features are lacking. Lung involvement and pleural effusions are frequently observed and are associated with a poor prognosis. Involvement of the skeletal system, especially vertebrae, is also common and may lead to scoliosis and pathological fractures. A patient may be cured if surgical removal of the lymphatic channel tissue is possible. Due to the infiltrative character of the lymphatic vessels in lymphangiomas, however, most patients have inoperable disease.

Since surgery and shunt implantation were not feasible in our patient, a talcum pleurodesis was performed but without success. Surgery was confined in obtaining a histopathological diagnosis.

Treatment options for patients with inoperable lymphangioma or lymphangiomas include radiotherapy and local therapy with sclerosing substances [12]. Systemic approaches to suppress lymphatic vessel proliferation have used angiogenesis inhibitors such as thalidomide and interferon [2]. Eight patients with lymphangiomas, treated with interferon have been reported in the literature [6–11] (Table I). A response to IFN therapy was

TABLE I. Characteristics of Children Reported in the Literature Receiving IFN Treatment for Lymphangiomas

Age at diagnosis years/sex	Localization	Duration of IFN therapy (months)	Response to IFN therapy	Reasons for stopping IFN	Outcome	Reference
3/male	Thorax	<1	Regression of symptoms	Thrombocytopenia (resolved)	Died of hemoptysis 4 weeks after discontinuation of IFN	6
3/female	Thorax	"Short"	Not evaluable	N/A	Alive	7
7/male	Thorax	20	Clinical improvement	N/A	Alive	7
10/male	Thorax	"Short"	Not evaluable	Died	Died of respiratory failure	8
13/male	Thorax, abdominal wall	12	Clinical and radiological improvement	N/A	Alive	9
12/male	Thorax, bones, spleen	40	Clinical improvement, no progression	Not reported	Alive	9
1/male	Spleen	"Several"	Not reported	Responded to splenic embolisation	Alive	10
3/male	Lungs, ribs	2/28 (interrupted for 12)	Clinical and radiological improvement, disease progression during IFN pause	Interrupted for concern of neurological side effects	Alive	11

N/A, not applicable; IFN, interferon.

seen in five of these eight reported cases. Laverdiere et al. [11] reported a treatment response in a 3-year-old boy after 2 months of IFN- $\alpha$  2b therapy. Therapy was interrupted because reports of spastic diplegia as a severe complication of IFN were published. Six months later, however, the disease progressed. IFN- $\alpha$  2b was restarted after 1 year. The patient received IFN- $\alpha$  2b for another 28 months with a very good response and without any neurological side effects. Two reported patients did not have a sufficient follow-up or prematurely discontinued therapy respectively for adequate response evaluation [7,10]. In the one case reported not to have responded, therapy duration might have been too short to expect a beneficial effect in the advanced disease [8].

Immunohistochemical analysis of endothelial proliferation in our patient showed extensive expression of VEGFR-3, a protein known to be expressed in lymphatic vessels only. VEGFR-3 expression has not been examined in previously published cases when IFN treatment was used in children with lymphangiomatosis. The VEGF/VEGFR pathway is a potent regulator of vascular proliferation, survival, invasion, and permeability [13]. One possible mechanism of the interferon effect on angiogenesis is the downregulation of VEGF expression. This has recently been shown in neuroendocrine cells in rats [14]. It is therefore possible that IFN- $\alpha$  2b treatment resulted in decreased VEGF expression, and consequently inhibited growth and permeability of lymphatic vessels in our patient.

Neurotoxicity represents a well-known side effect of interferon therapy. There have been reports describing spastic diplegia induced by interferon treatment, which does occur more likely in infants and very young children [15,16]. More common side effects are headache, elevated body temperature, fatigue, and nausea and are better tolerated. Our patient developed only minor side effects during the first months, which responded well to supportive acetaminophen treatment.

In summary, our patient showed a good clinical response to IFN- $\alpha$  2b therapy. His general status improved from critical illness at the time of presentation to normal physical activity. The clinical course reported here demonstrates that recombinant IFN- $\alpha$  2b can provide a successful therapeutic option with tolerable side effects in

inoperable lymphangiomatosis and should be considered early after the confirmation of the diagnosis.

## REFERENCES

1. Faul JL, Berry GJ, Colby TV, et al. Thoracic lymphangiomas, lymphangiectasis, lymphangiomatosis, and lymphatic dysplasia syndrome. *Am J Respir Crit Care Med* 2000;161:1037–1046.
2. Rostom AY. Treatment of thoracic lymphangiomatosis. *Arch Dis Child* 2000;83:138–139.
3. Orchard PJ, Smith CM III, Woods WG, et al. Treatment of haemangioendotheliomas with alpha interferon. *Lancet* 1989;2:565–567.
4. Ezekowitz RA, Mulliken JB, Folkman J. Interferon alfa-2a therapy for life-threatening hemangiomas of infancy. *N Engl J Med* 1992;326:1456–1463.
5. Chang E, Boyd A, Nelson CC, et al. Successful treatment of infantile hemangiomas with interferon-alpha-2b. *J Pediatr Hematol Oncol* 1997;19:237–244.
6. Kelso JM, Kerr DJ, Lie JT, et al. Unusual diffuse pulmonary lymphatic proliferation in a young boy. *Chest* 1991;100:556–560.
7. Tazelaar HD, Kerr D, Yousem SA, et al. Diffuse pulmonary lymphangiomatosis. *Hum Pathol* 1993;24:1313–1322.
8. Margraf LR. Thoracic lymphangiomatosis. *Pediatr Pathol Lab Med* 1996;16:155–160.
9. Reinhardt MA, Nelson SC, Sencer SF, et al. Treatment of childhood lymphangiomas with interferon-alpha. *J Pediatr Hematol Oncol* 1997;19:232–236.
10. Patton DF, Kaye R, Dickman P, et al. Partial splenic embolization for treatment of disseminated intravascular coagulation in lymphangiomatosis. *J Pediatr* 1998;132:1057–1060.
11. Laverdiere C, David M, Dubois J, et al. Improvement of disseminated lymphangiomatosis with recombinant interferon therapy. *Pediatr Pulmonol* 2000;29:321–324.
12. Claesson G, Kuylenstierna R. OK-432 therapy for lymphatic malformation in 32 patients (28 children). *Int J Pediatr Otorhinolaryngol* 2002;65:1–6.
13. Hicklin DJ, Ellis LM. Role of the vascular endothelial growth factor pathway in tumor growth and angiogenesis. *J Clin Oncol* 2005;23:1011–1027.
14. Rosewicz S, Detjen K, Scholz A, et al. Interferon-alpha: Regulatory effects on cell cycle and angiogenesis. *Neuroendocrinology* 2004;80(Suppl 1):85–93.
15. Barlow CF, Priebe CJ, Mulliken JB, et al. Spastic diplegia as a complication of interferon alfa-2a treatment of hemangiomas of infancy. *J Pediatr* 1998;132:527–530.
16. Michaud AP, Bauman NM, Burke DK, et al. Spastic diplegia and other motor disturbances in infants receiving interferon-alpha. *Laryngoscope* 2004;114:1231–1236.