

## REVIEW ARTICLE

# Non-cirrhotic portal fibrosis: Current concepts and management

SK SARIN AND D KAPOOR

*Department of Gastroenterology, GB Pant Hospital, New Delhi, India*

**Abstract** Non-cirrhotic portal hypertension (NCPH) comprises diseases having an increase in portal pressure (PP) due to intrahepatic or prehepatic lesions, in the absence of cirrhosis. The lesions are generally vascular, either in the portal vein, its branches or in the perisinusoidal area. Because the wedged hepatic venous pressure is near normal, measurement of intravariceal or intrasplenic pressure is needed to assess PP. The majority of diseases included in the category of NCPH are well-characterized disease entities where portal hypertension (PHT) is a late manifestation and, hence, these are not discussed. Two diseases that present only with features of PHT and are common in developing countries are non-cirrhotic portal fibrosis (NCPF) and extrahepatic portal vein obstruction (EHPVO). Non-cirrhotic portal fibrosis is a syndrome of obscure etiology, characterized by ‘obliterative portovenopathy’ leading to PHT, massive splenomegaly and well-tolerated episodes of variceal bleeding in young adults from low socioeconomic backgrounds, having near normal hepatic functions. In some parts of the world, NCPF is called idiopathic portal hypertension (IPH) or ‘hepatoportal sclerosis’. Because 85–95% of patients with NCPF and EHPVO present with variceal bleeding, treatment involves management with endoscopic sclerotherapy (EST) or variceal ligation (EVL). These therapies are effective in approximately 90–95% of patients. Gastric varices are another common cause of upper gastrointestinal bleeding in these patients and these can be managed with cyanoacrylate glue injection or surgery. Other indications for surgery include failure of EST/EVL, and symptomatic hypersplenism. The prognosis of patients with NCPF is good and 5 years survival in patients in whom variceal bleeding can be controlled has been reported to be approximately 95–100%.

© 2002 Blackwell Publishing Asia Pty Ltd

**Key words:** beta-blockers, endoscopic sclerotherapy, endoscopic variceal ligation, extrahepatic portal vein obstruction, idiopathic portal hypertension, non-cirrhotic portal fibrosis, portal hypertensive gastropathy, shunt surgery, variceal hemorrhage.

## INTRODUCTION

Non-cirrhotic portal hypertension (NCPH) comprises a group of diseases that are characterized by an increase in portal pressure due to intrahepatic or prehepatic lesions, in the absence of cirrhosis of the liver. It is not merely absence of cirrhosis, but also of hepatic venous outflow obstruction, such as veno-occlusive disease and Budd–Chiari syndrome. The lesion in NCPH is generally vascular, present in the portal vein, its branches or in the perisinusoidal area of the liver. Wedged hepatic venous pressure (WHVP) is near normal or mildly elevated in these patients and is significantly lower than portal vein pressure.<sup>1,2</sup>

The majority of diseases that are grouped under this category of NCPH (Table 1) have portal hypertension (PTH) as a late manifestation of the disease. Two diseases, which are very common in developing countries

and almost always present only with features of PTH, include non-cirrhotic portal fibrosis (NCPF) and extrahepatic portal vein obstruction (EHPVO; Fig. 1).

The present review describes our existing knowledge of NCPF. The topic of EHPVO has been recently reviewed by us elsewhere.<sup>3</sup>

## HISTORICAL PERSPECTIVE

Attention was drawn to a condition characterized by congestive splenomegaly, anemia, with or without gastrointestinal bleeding and ascites as early as the late 19th century.<sup>4</sup> Awareness about this condition as being distinct from cirrhotic causes of PHT emerged in the Indian subcontinent in the late 1950s. In 1962, Indian scientists drew attention to splenomegaly with non-

cirrhotic liver disease in North Indian patients.<sup>5</sup> Soon after, Boyer *et al.*, while working in Calcutta, reported a series of similar patients but used the term idiopathic portal hypertension (IPH).<sup>6</sup> At the same time, Mikkelsen *et al.* described 36 patients with PHT without cirrhosis who had phlebosclerosis of intra- and extrahepatic portal veins and coined the term 'hepatoportal sclerosis'.<sup>7</sup> In 1969, a workshop organized by the Indian Council of Medical Research (ICMR) reviewed all available information on this condition and christened this distinct clinicopathological entity as 'non-cirrhotic portal fibrosis'.<sup>8</sup> This condition was simultaneously reported from Japan, where the condition is known as IPH,<sup>9,10</sup> and subsequently from Iran<sup>11</sup> and Pakistan.<sup>12</sup>

**EPIDEMIOLOGY**

Non-cirrhotic portal fibrosis has been reported from all over the Indian continent.<sup>5,12-14</sup> It is believed to account for nearly one-sixth to one-quarter of all causes of PTH seeking medical attention. The condition has been commonly seen in people who are socioeconomically disadvantaged, not only in India, but also in Iran.<sup>11</sup> Improved hygiene and standards of living could explain the relative rarity of the disease in the West and its declining incidence in Japan. While in 1985 the reported inci-

dence of IPH in Japan was 0.75/10<sup>5</sup> population, in 1992 only an average of 11 new patients were reported.<sup>15</sup> The incidence of IPH has not been prospectively studied in India. Except for an occasional report, most studies indicate a male predominance.<sup>13,14</sup> This is in contrast to IPH in Japan, Europe and the USA, where the disease is more common in females (Table 2). The mean age of NCPF patients varies from 25 to 35 years, which is much younger than for IPH patients.

**ETIOLOGY**

The etiopathogenesis of NCPF is poorly understood. A number of hypotheses have been proposed.

**Infective hypothesis**

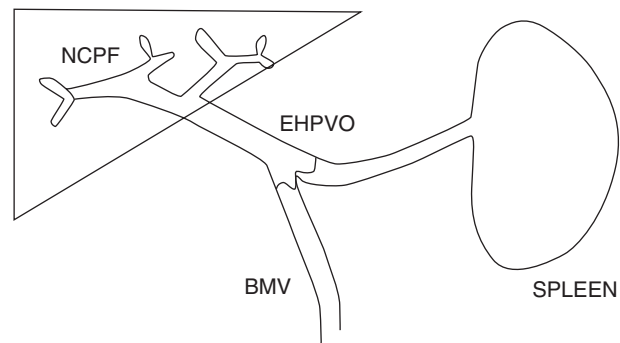
Non-cirrhotic portal fibrosis has been commonly seen in patients from a low socioeconomic background. Abdominal infection at birth or in early childhood has been alleged to play an important role.<sup>14</sup> Umbilical sepsis, bacterial infections and diarrheal episodes in infancy and in early childhood are likely to lead to por-

**Table 1** Common causes of non-cirrhotic portal hypertension†

|   |
|---|
| Extrahepatic portal venous obstruction*                         |
| Non-cirrhotic portal fibrosis or idiopathic portal hypertension |
| Schistosomiasis   |
| Primary or secondary biliary cirrhosis (pre-cirrhotic stage)    |
| Congenital hepatic fibrosis                                     |
| Veno-occlusive disease*   |
| Nodular regenerative hyperplasia                                |
| Partial nodular transformation                                  |
| Hepatoportal sclerosis  |
| Peliosis hepatitis  |

\*May present acutely.

†Most causes are chronic conditions.



**Figure 1** Schematic diagram to show the main sites of obstruction in non-cirrhotic portal fibrosis (NCPF) and extrahepatic portal vein obstruction (EHPVO).

**Table 2** Comparison between non-cirrhotic portal fibrosis and idiopathic portal hypertension

|                                   | NCPF                 | IPH               |
|-----------------------------------|----------------------|-------------------|
| Age (years)                       | 25-35                | 43-56             |
| Male : female ratio               | 2 : 1                | 1 : 3             |
| Hematemesis/melena (%)            | 94                   | 40                |
| Mass in LUQ (%)                   | 6                    | 40                |
| Ascites (%)                       | 2                    | 10                |
| Autoimmune features               | Rare                 | Common            |
| Pathology                         |                      |                   |
| Irregular parenchymal nodules (%) | 53                   | 29                |
| Bile duct proliferation (%)       | 38                   | 4                 |
| Wedged hepatic venous pressure    | Normal/mildly raised | Moderately raised |

NCPF, non-cirrhotic portal fibrosis; IPH, idiopathic portal hypertension; LUQ, left upper quadrant.

tal pyemia, pylephlebitis, resulting in thrombosis, sclerosis and obstruction of small- and medium-sized portal vein radicals.

#### *Experimental studies*

Idiopathic portal hypertension like changes in the liver and the development of PTH, has been reported after injecting dead non-pathogenic colon bacilli into the portal vein of rabbits and dogs.<sup>16,17</sup> In another model of indwelling cannulation of the gastrosplenic vein, repeated injections of *Escherichia coli* resulted in the development of splenomegaly and an increase in portal pressure at 3 months.<sup>18</sup>

### **Exposure to trace metals and chemicals**

Prolonged ingestion of arsenic has been incriminated in the causation of NCPF.<sup>19</sup> Liver histology in patients with chronic arsenic ingestion reveals periportal fibrosis, incomplete septal cirrhosis, with or without development of neovascularization within the expanded portal zones suggestive of NCPF or IPH. In a Belgian study, a previous intake of arsenic as Fowler's solution for the treatment of psoriasis was reported in eight of 47 NCPH patients.<sup>20</sup> Interestingly, these patients had florid skin stigmata of arsenicosis, something not commonly experienced by us. From our center, seven patients diagnosed as NCPF did not have elevated arsenic content in the liver, as assayed by electron probe microanalysis. In patients from Iran, a history of pica was obtained in nearly half the patients.<sup>11</sup>

A histological picture resembling NCPF has been observed following chronic exposure to vinyl chloride monomers, copper sulfate (vineyard sprayers), protracted treatment with methotrexate, hypervitaminosis A and in renal allograft recipients receiving treatment with 6-mercaptopurine, azathioprine and corticosteroids.

#### *Experimental studies*

To investigate whether chronic arsenic exposure could produce NCPF, we undertook studies in albino mice with chronic oral arsenic feeding. While arsenic was found to induce a four- to 14-fold increase in hepatic hydroxyproline and hepatic collagen compared with control mice, features of NCPF or PTH did not develop in any animal.<sup>21</sup> These observations suggest that although arsenic ingestion could induce hepatic fibrogenesis, it cannot be directly incriminated in the causation of NCPF.

### **Immunologic and immunogenetic hypotheses**

Evidence supporting these hypotheses includes: (i) a reduction in the suppressor/cytotoxic T lymphocytes

(T8) in NCPF patients and a decreased T4/T8 lymphocyte ratio;<sup>22</sup> (ii) a reduction in the cell-mediated immune status in NCPF patients; and (iii) a poor autologous mixed lymphocyte reaction (MLR).<sup>23</sup>

In Japan, IPH is frequently associated with autoimmune disorders such as systemic lupus erythematosus (SLE), progressive systemic sclerosis (PSS), thyroiditis and mixed connective tissue disease (MCTD).<sup>24</sup> Nearly two-thirds of Japanese female patients with IPH test positive for anti-ds DNA antibody and one-quarter test positive for antinuclear antibody.<sup>25</sup> Such a high prevalence of associated autoimmune conditions has not been the experience in the Indian subcontinent. However, familial aggregation and a high frequency of HLA-DR3 has been found in our patients.<sup>26</sup>

#### *Experimental studies*

Repeated injections of splenic extract, Freund's adjuvant and egg albumin have been shown to produce splenomegaly and histological lesions similar to IPH in rabbits.<sup>27</sup> In a recent study, injection of splenic extract in presensitized rabbits resulted in the development of an NCPF-like picture, with splenomegaly and an increase in portal pressure with negligible parenchymal injury.<sup>18</sup>

### **Proposed hypothesis**

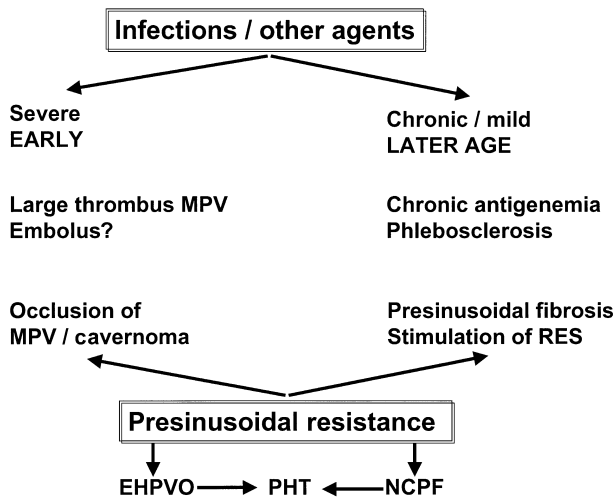
Based on the available information, we propose a hypothesis for the development of NCPF and EHPVO. Both these venous inflow tract diseases could develop in a genetically predisposed individual when infection or a prothrombotic event could precipitate thrombosis in the portal vein or its radicals. If it is a major thrombotic event, occurring at an early age in life, the main portal vein becomes occluded, leading to the development of EHPVO (Fig. 2). However, in the event of repeated microthrombotic events, the small or medium branches of the portal vein are affected, leading to the development of NCPF in a young adult.

## **PATHOLOGY**

When NCPF was first recognized, salient histological features characteristic of this condition were described. In fact, NCPF was termed as a distinct clinicopathological entity.

### **Gross pathology**

Early experience was derived from systematic study of wedge hepatic specimens, obtained from patients undergoing surgery. In patients with NCPF, the liver may be normal to markedly nodular. This nodularity,



**Figure 2** A proposed hypothesis for the pathogenesis of non-cirrhotic portal fibrosis (NCPF) and extrahepatic portal vein obstruction (EHPVO). MPV, main portal vein; RES, reticuloendothelial system.

seen in 10–15% of cases, is confined to the liver surface. The portal vein and its branches are prominent and have sclerosed walls. Autopsy series commonly show thrombosis in the medium and small (diameter < 300 μm) portal vein branches.<sup>23,24</sup>

**Histopathology**

Histological changes in NCPF were aptly summarized by Nayak and Ramalingaswamy as ‘obliterative porto-venopathy of liver’.<sup>28</sup> Essentially, there is a marked but patchy and segmental subendothelial thickening of the large and medium-sized branches of the portal vein. These changes are summarized in an excellent review by Nakanuma *et al.* (Table 3).<sup>29</sup> The intimal thickening of intrahepatic portal venous channels, associated with obliteration of small portal venules and emergence of new aberrant portal channels, is quite characteristic of NCPF. Evidence of previous phlebothrombosis is suggested by the presence of old mural thrombi incorporated in the wall, mural thickening of the extrahepatic portal vein and coexistence of lesions characteristic of NCPF as well as EHPVO in the same patient.

**Ultrastructure**

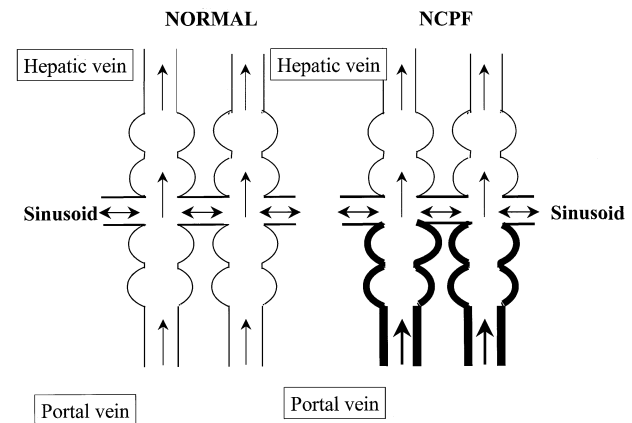
A widening of the space of Disse with haphazardly arranged collagen bands in the perisinusoidal space leading to capillarization of sinusoids may be seen. Whether these electron microscopic changes correlate with the severity of PHT or occurrence of ascites, which is seen in a small proportion of NCPF patients, has not been determined.

**Table 3** Histological findings in idiopathic portal hypertension

|   | Frequency (%) |
|---|---------------|
| Dense portal fibrosis and portal venous obliteration        |               |
| Mild  | 48            |
| Moderate to severe  | 52            |
| Portal inflammation   | 47            |
| Irregular intimal thickening of portal veins                | 75–100*       |
| Organizing thrombotic and/or recanalization of portal veins | 20–100*       |
| Nodular hyperplasia of the parenchyma                       | 40            |
| Abnormal blood vessels in the lobules                       | 75            |
| Intralobular fibrous septa                                  | 95            |
| Subcapsular atrophy   | 70            |
| Periductal fibrosis of interlobular bile ducts              | 50            |

Modified from Nakanuma *et al.*<sup>29</sup> based on a study of 66 patients with idiopathic portal hypertension.

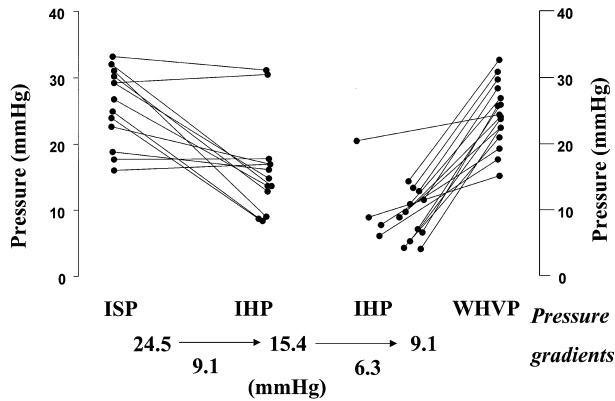
\*100% abnormalities were observed only in autopsy specimens.



**Figure 3** The pathoanatomic sites of resistance to portal blood flow in patients with non-cirrhotic portal fibrosis (NCPF), namely presinusoidal and perisinusoidal, caused by thickening and obstruction to the medium-sized and small branches of portal veins and the collagenization of the space of Disse, respectively.

**HEMODYNAMICS**

The intrasplenic and portal vein pressures are markedly elevated in patients with NCPF. The WHVP may be normal or slightly elevated in approximately half the patients. Two pathoanatomic sites of obstruction (Fig. 3) have been identified: a pressure gradient between the spleen (intrasplenic pressure; ISP) and the liver (intrahepatic pressure; IHP) and another between the liver (IHP) and the WHVP (Fig. 4).<sup>30</sup> Variceal pressure has also been studied in these patients and found comparable to that in cirrhotic PHT.<sup>30,31</sup> Splenic and



**Figure 4** Two pressure gradients, between the spleen and liver (intrasplenic pressure (ISP)–intrahepatic pressure (IHP)) and between the liver and the wedged hepatic venous pressure (IHP–WHVP) are observed in patients with non-cirrhotic portal fibrosis (NCPF). In effect, they represent presinusoidal and perisinusoidal resistance to portal blood flow.

portal vein blood flow are known to be markedly increased in IPH patients from Japan, suggestive of a hyperdynamic circulatory state. Pulmonary hemodynamics in patients with NCPF have also been reported.<sup>32</sup> Two of 22 patients in that study had features of primary pulmonary hypertension (PPH). Pulmonary angiography was reported normal in the single patient in whom it was performed.

**CLINICAL PROFILE**

Non-cirrhotic portal fibrosis is a disease of young patients coming from a low socioeconomic background. Most studies quote a slight male preponderance (male : female ratio 2 : 1).<sup>13,14</sup> The patients may present with one or more well-tolerated episodes of gastrointestinal hemorrhage, long-standing mass in the left upper quadrant (splenomegaly) and consequences of hypersplenism. Development of ascites, jaundice and hepatic encephalopathy is uncommon and are only seen after an episode of gastrointestinal hemorrhage. Of all the causes of PHT, a massive and disproportionately large spleen is most commonly seen in NCPF. It is not uncommon to see patients presenting with repeated attacks of left upper quadrant pain due to perisplenitis and splenic infarction.<sup>33</sup> The clinical presentation of NCPF is distinct from IPH in several regards (Table 2). Like cirrhosis, NCPF may also have odd presentations, such as glomerulonephritis<sup>34,35</sup> or hypoxemia.<sup>36</sup>

Over a 12-year period (1983–1995), we had seen 2137 patients with PTH; 1133 bleeders and 1004 non-bleeders. Non-cirrhotic portal fibrosis comprised 35.4% of all bleeders and 4.1% of non-bleeders. Non-cirrhotic portal fibrosis was diagnosed in 207 patients, while EHPVO was diagnosed in 236 patients. The clinical and laboratory profiles of these patients are shown in Table 4.

**Table 4** Profile of non-cirrhotic portal fibrosis and extra-hepatic portal vein obstruction patients

|                         | NCPF<br>(n = 207) | EHPVO<br>(n = 236) |
|-------------------------|-------------------|--------------------|
| Mean age (years)        | 30.7              | 13.9               |
| Sex (males : females)   | 117 : 90          | 168 : 68           |
| Hematemesis/melena (%)  | 84.5              | 94.5               |
| Mass in LUQ (%)         | 13.5              | 3.5                |
| Ascites (transient) (%) | 10                | 12.7               |
| Jaundice (%)            | –                 | 12.7               |
| Liver functions tests   | Near normal       | Near normal        |
| Esophageal varices (%)  | 92                | 94                 |
| Gastric varices (%)     | 22.3              | 40.7               |
| Portal gastropathy      |                   |                    |
| Presclerotherapy (%)    | 1.6               | 0.5                |
| Post-sclerotherapy (%)  | 17                | 15                 |
| Portal biliopathy (%)   | 40                | 90                 |
| Portal colopathy (%)    | 40                | 44                 |

Data are based on the experience at the GB Pant Hospital, New Delhi, India.<sup>37</sup>

NCPF, non-cirrhotic portal fibrosis; EHPVO, extrahepatic portal vein obstruction; LUQ, left upper quadrant.

**LABORATORY FEATURES**

Tests of liver function are, by and large, normal in NCPF patients. These include semiquantitative tests of liver function, such as monoethylglycineylidide (MEGX) extraction.<sup>38</sup> Biliary lipid composition is normal in NCPF patients.<sup>39</sup> The frequency of hepatitis B and C in non-transfused NCPF patients is approximately 5 and 3%, respectively (SK Sarin, unpubl. obs., 2000); similar to the figures in the general population.

Anemia is a common finding in the majority of NCPF patients. This may be microcytic, hypochromic (due to gastrointestinal blood loss) or normocytic, normochromic (hypersplenism). Leukopenia (<4000/mm<sup>3</sup>) and thrombocytopenia (<50 000/mm<sup>3</sup>) may also be present. These changes are due, in part, to an increase in plasma volume and splanchnic pooling of the blood. Bone marrow is hypercellular. While asymptomatic hypersplenism is common, symptomatic hypersplenism is rather rare in NCPF.<sup>40</sup> Coagulation and platelet function anomalies have been observed in NCPH patients (Table 5).<sup>41</sup> A state of mild compensated disseminated intravascular coagulation secondary to endotoxemia or portosystemic collaterals has been reported in a fair proportion of these patients.<sup>41,42</sup>

Autonomic dysfunction is increasingly being recognized in patients with cirrhosis. We have recently observed these anomalies in EHPVO patients, possibly because these patients do have some degree of hepatic dysfunction.<sup>43</sup> However, autonomic dysfunction does occur even in patients with NCPF, with near-normal liver function, suggesting some contribution of PTH *per se*.

**Table 5** Coagulation and platelet function in non-cirrhotic portal hypertension<sup>39</sup>

| Parameter (normal range)                    | NCPF (n = 18) | EHPVO (n = 18) |
|---|---------------|----------------|
| INR   | 1.8 ± 0.68*   | 1.7 ± 0.4*     |
| PTT (28–31 s)                               | 29 ± 4.2      | 30 ± 4.2*      |
| Fibrinogen (250–350 mg%)                    | 196 ± 57**    | 199 ± 61**     |
| Fibrinogen degradation products (< 8 µg/mL) | < 8           | > 8**          |
| Platelet aggregation (40–60%)               | 33 ± 16.5     | 22 ± 11.3**    |
| Platelet MDA (6–12 nmol/mL)                 | 9.0 ± 3.6     | 9.6 ± 3.8      |

\* $P < 0.05$ , \*\* $P < 0.001$  compared with controls.

NCPF, non-cirrhotic portal fibrosis; EHPVO, extrahepatic portal vein obstruction; INR, international normalized ratio; PTT, partial thromboplastin time; MDA, malondialdehyde.

**Table 6** Natural history of portal hypertensive gastropathy<sup>48</sup>

| Course of PHG | Cirrhosis (n = 53) | NCPF (n = 17) | EHPVO (n = 16) | Total (%) (n = 86) |
|---------------|--------------------|---------------|----------------|--------------------|
| Transient     | 13 (35%)*          | 10 (59%)      | 7 (44%)        | 30 (35%)           |
| Persistent    | 35 (66%)           | 4 (24%)       | 9 (56%)        | 48 (56%)           |
| Progressive   | 5 (9%)             | 3 (18%)       | 0              | 8 (9%)             |

\* $P < 0.01$  between cirrhosis and non-cirrhotic portal fibrosis (NCPF).

EHPVO, extrahepatic portal vein obstruction; PHG, portal hypertensive gastropathy.

## IMAGING

Splenoportovenography, often used in the past, shows a dilated and thickened vein with venous collaterals.<sup>44</sup> On ultrasonography, the portosplenic axis is seen to be dilated and patent. Occasionally, thrombus is seen in the intrahepatic branch of the portal vein. We have observed the wall thickness (echogenic boundary of portal vein) of the main portal vein (at hilum) to be significantly more in NCPF than for other etiologies of PHT. Spontaneous lienorenal shunts are also seen more frequently in NCPF patients than in patients with cirrhosis.

Hepatic venography and radionuclide scintigraphy (using <sup>99m</sup>Tc phytate or sulfur colloid) have been used to distinguish between NCPF and cirrhosis.<sup>12,45,46</sup> High marrow uptake on scintigraphy is almost pathognomonic of cirrhosis. Some Japanese workers have used computed tomography (CT) portography and CT hepatic angiography to show aberrant vessels in the periphery of hepatic parenchyma in these patients.<sup>23</sup>

Portal biliopathy, defined as anomalies of the biliary system and gallbladder in patients with PTH, is commonly seen in patients with EHPVO. It is also not uncommon in NCPF patients.<sup>47</sup> However, because tests of liver function are generally normal, endoscopic retrograde cholangiopancreatography (ERCP) is not routinely recommended in NCPF patients.

## ENDOSCOPY

Esophagogastric varices have been reported in 85–95% of patients with NCPF.<sup>37</sup> In a series from North India, large varices were far more common in NCPH (90%)

than in patients with cirrhosis (70%).<sup>48</sup> Similarly, anorectal varices were also more commonly reported in NCPH than in cirrhosis (90 vs 56%) and were likely to be larger in the former condition.<sup>48</sup> El Atti *et al.* found variceal pressure (using a pressure gauge) to be similar in NCPH and cirrhosis but, for any given variceal pressure, cirrhotic patients are more likely to bleed.<sup>31</sup> El Atti *et al.* found the prevalence of red signs and the NIEC (North Italian Endoscopy Club) index to be similar in the two groups of portal hypertensive patients.

We had also reported that variceal pressure in patients with NCPF and cirrhosis is comparable. Similar findings were reported by El Atti *et al.*<sup>31</sup> Portal hypertensive gastropathy is uncommon in NCPF patients and is a rare cause of upper gastrointestinal bleeding at the initial presentation.<sup>49</sup> Gastropathy, however, develops after endoscopic sclerotherapy or variceal ligation in a fair proportion of patients. Post-variceal obliteration gastropathy is often transitory or non-progressive in NCPF patients (Table 6).

## DIFFERENTIAL DIAGNOSIS

For most physicians and gastroenterologists practising in India, NCPF is a distinct and easily identifiable disease. While NCPF can be easily differentiated from EHPVO (Table 7), it may be difficult to diagnose when there is coexisting thrombosis of one of the main branches of the portal vein. Non-cirrhotic portal fibrosis generally develops insidiously, while portal vein thrombosis may have an acute presentation (sudden increase in variceal size, development of an upper gastrointestinal bleed, abdominal pain and ascites).

**Table 7** Differentiating features between extrahepatic portal vein obstruction, non-cirrhotic portal fibrosis and cirrhosis of liver

| Parameter                       | EHPVO                        | NCPF  | Cirrhosis                               |
|---------------------------------|------------------------------|---|---|
| Mean age (years)                | 10                           | 28  | 40                                      |
| Ascites                         | Absent/transient after bleed | Absent/transient after bleed  | + to +++                                |
| Encephalopathy                  | –                            | –   | +                                       |
| Jaundice/signs of liver failure | –                            | –   | +                                       |
| Liver function tests            | Normal*                      | Normal  | Deranged                                |
| Liver                           |                              |   |   |
| Gross                           | Normal/small                 | Normal, rarely irregular  | Shrunken, nodular                       |
| Microscopic                     | Normal                       | Normal/portal fibrosis  | Necrosis, regeneration                  |
| Splenoportovenography/US        | Portal/splenic vein block    | Normal splenoportal axis, 'withered tree' appearance, periportal fibrosis | Dilated, patent portal and splenic vein |

\*Occasional impairment may be observed.

NCPF, non-cirrhotic portal fibrosis; EHPVO, extrahepatic portal vein obstruction; US, ultrasound.

Child's A cirrhosis may mimic NCPF, but tests of liver function, viral serology and histology (lobular disarray, pseudolobule formation) can distinguish between the two. Moreover, a disproportionately large spleen with a dilated and thickened portal vein favors the diagnosis of NCPF.

Tropical splenomegaly syndrome (TSS) is another condition sometimes seen in the tropics, which presents with massive splenomegaly. However, PHT is uncommon in patients with TSS and the WHVP is within normal limits.<sup>50</sup> Moreover, elevated serum IgM levels and high malarial antibody titers are common in TSS patients.

Histologically, NCPF needs to be distinguished from conditions like nodular regenerative hyperplasia, partial nodular transformation and incomplete septal cirrhosis.

## MANAGEMENT

The key management issues in patients with NCPF are gastrointestinal hemorrhage and hypersplenism. For acutely bleeding patients, endoscopic variceal ligation (EVL) and endoscopic sclerotherapy (EST) are equally efficacious (95% success in the control of an acute bleed).<sup>51</sup> Emergency shunt surgery is required in less than 5% of cases.<sup>52</sup> Selective shunts, like a distal lienorenal shunt, are preferred because they have a lower incidence of post-shunt encephalopathy. The number of sessions of sclerotherapy required for obliteration of varices is similar in patients with cirrhosis and NCPF.<sup>53</sup> Variceal recurrence has been reported in approximately 20% of cases, but recurrent bleed is quite uncommon (approximately 3%).<sup>52,53</sup> Prevention of rebleeding has been reported in patients with schistosomiasis in an isolated study using non-selective beta-blockers.<sup>54</sup> These data have not been confirmed in NCPF patients. In our recently reported experience of primary prophylaxis using beta-blockers or EVL, both modalities were found to be comparable and efficacious, even in non-cirrhotic patients, although the number of NCPF patients in each group was small.<sup>55</sup> Gastric varices are seen in nearly one-quarter of NCPF patients, more often than

that seen in cirrhotic patients.<sup>56</sup> These varices can often be managed with cyanoacrylate glue injection and rarely require surgical intervention.<sup>57</sup>

Interventional radiological procedures have been reported to be effective in IPH patients. These include splenic embolization, percutaneous transhepatic obliteration and transjugular intrahepatic portosystemic shunt (TIPS) procedure.<sup>58</sup> We have also performed a TIPS in three NCPF patients with gastric varices and the shunt remained patent at 12 months post-procedure.

Surgery has been reported to be an effective alternative to endoscopic therapy, especially in patients who fail to respond to endoscopic therapy.<sup>59</sup> Surgery is also indicated for patients with symptomatic hypersplenism–spontaneous bleeding episodes or severe anemia requiring transfusion or repeated splenic infarcts. In those patients who hail from far-flung areas or who desire one-time treatment, elective shunt surgery is a reasonable option. The most important cause of death in NCPF or IPH patients is exsanguinating hemorrhage. Prophylactic devascularization has been advocated by certain Japanese workers.<sup>23</sup>

Surgical mortality after emergency shunts is approximately 10%. Shunt occlusion, overt chronic portosystemic encephalopathy and rebleeding after elective shunt surgery are seen in approximately 10% of patients.<sup>60,61</sup> The morbidity and mortality after shunt surgery and the limited expertise available to perform these procedures have restricted the use of surgery in the management of patients with NCPF. Recently, development of membranoproliferative glomerulonephritis and other renal anomalies have been reported following shunt surgery in NCPF patients.<sup>34</sup>

## PROGNOSIS

The prognosis for patients with NCPF is excellent. The mortality from an acute bleed in NCPF is significantly lower than that observed in cirrhotic patients.<sup>23</sup> After successful eradication of esophagogastric varices, a 2- and 5-year survival of nearly 100% has been observed in

these patients. If these patients are managed with selective shunt surgery, shunt occlusion and post-shunt encephalopathy may cause some morbidity, but dietary manipulations (protein restriction) can ameliorate the symptoms to a large extent.

## CONCLUDING REMARKS

Non-cirrhotic portal fibrosis continues to be a common cause of PHT in selected geographic areas of the world, especially in socially disadvantaged people. The etio-pathogenesis of this condition is possibly multifactorial. The clinical presentation of patients is with splenomegaly and/or complications of PTH. The patients have a relatively well-preserved liver function. The diagnosis is based on clinical and endoscopic evidence of PHT, as well as radiological and histological features. If managed suitably, these patients have a life expectancy similar to that of the population at large. Future research should aim to elucidate pathogenetic mechanisms so that the condition can be effectively prevented.

## REFERENCES

- 1 Reynolds T, Ito S, Iwatsuki S. Measurement of portal pressure and its clinical application. *Am. J. Med.* 1970; **49**: 649–58.
- 2 Bosch J, Mastai R, Kravetz D, Navasa M, Rodes J. Hemodynamic evaluation of the patient with portal hypertension. *Semin. Liver Dis.* 1986; **6**: 309–17.
- 3 Sarin SK, Agarwal SR. Extrahepatic portal vein obstruction. *Semin. Liver Dis.* 2002; **22**: 43–58.
- 4 Banti G. Splenomegalic mit Leberzirrhose. Beitrage sur pathologischen. *Anat. Allgemein. Pathol.* 1889; **24**: 21–33.
- 5 Ramalingaswamy B, Wig KL, Sama SK. Cirrhosis of the liver in northern India. A clinicopathological study. *Arch. Intern. Med.* 1962; **110**: 350–8.
- 6 Boyer JL, Sengupta KP, Biswas SK *et al.* Idiopathic portal hypertension: Comparison with the portal hypertension of cirrhosis and extrahepatic portal vein obstruction. *Ann. Intern. Med.* 1967; **66**: 41–68.
- 7 Mikkelsen WP, Edmondson HA, Peters RL, Redeker AG, Reynolds TB. Extra- and intrahepatic portal hypertension without cirrhosis (hepatoportal sclerosis). *Ann. Surg.* 1965; **162**: 602–20.
- 8 Ramalingaswamy B, Nayak NC, eds. *Proceedings of the Workshop on Non-Cirrhotic Portal Fibrosis*. New Delhi: Indian Council of Medical Research, 1969.
- 9 Kobayashi Y, Inokuchi K, Saku M. Epidemiology of idiopathic portal hypertension based on a nation-wide survey. In: Suguira M, ed. *Report of the Ministry of Health and Welfare Research Committee on Idiopathic Portal Hypertension*. Tokyo: Japan Ministry of Health and Welfare, 1976; 10–15.
- 10 Okuda K, Kono K, Onishi K, Kimura K, Omata M, Koen H. Clinical study of eighty-six cases of idiopathic portal hypertension and comparison with cirrhosis with splenomegaly. *Gastroenterology* 1984; **86**: 600–4.
- 11 Vakili C, Farahvash MJ, Bynum TE. ‘Endemic’ idiopathic portal hypertension. Report on 32 patients with non-cirrhotic portal fibrosis. *World J. Surg.* 1992; **16**: 118–25.
- 12 Qureshi H, Kamal S, Khan RA, Zuberi SJ, Alam SE. Differentiation of cirrhotic vs idiopathic portal hypertension using <sup>99m</sup>Tc-Sn colloid dynamic and static scintigraphy. *J. Pak. Med. Assoc.* 1991; **41**: 126–9.
- 13 Sama SK, Bhargawa S, Gopi Nath N *et al.* Non-cirrhotic portal fibrosis. *Am. J. Med.* 1971; **51**: 160–9.
- 14 Sarin SK. Non-cirrhotic portal fibrosis. *Gut* 1989; **5**: 336–51.
- 15 Imai F, Kuga K, Komaba M *et al.* Interim report on IPH survey. In: Futagawa S, ed. *1992 Report of the Research Committee on Aberrant Portal Hemodynamics*. Tokyo: Ministry of Health and Welfare, 1993; 107–10.
- 16 Sugita S, Ohnishi K, Saito M, Okuda K. Splanchnic hemodynamics in portal hypertensive dogs with portal fibrosis. *Am. J. Physiol. Gastrointest. Liver Physiol.* 1987; **252**: G748–54.
- 17 Kohno K, Ohnishi K, Omata M *et al.* Experimental portal fibrosis produced by intraportal injection of killed non-pathogenic *Escherichia coli* in rabbits. *Gastroenterology* 1988; **94**: 787–96.
- 18 Kathayat R, Pandey GK, Malhotra V, Sarin SK. Development of a model of non-cirrhotic portal fibrosis with repeated immunosensitization by rabbit splenic extract. *Hepatology* 1999; **30**: A284 (Abstract).
- 19 Guha Mazumdar DN, Gupta JD, Dasgupta JD. Arsenic and non-cirrhotic portal hypertension. *J. Hepatol.* 1991; **13**: 376.
- 20 Nevens F, Fevery J, Steenberg Van W *et al.* Arsenic and non-cirrhotic portal hypertension. A report of eight cases. *J. Hepatol.* 1990; **11**: 80–5.
- 21 Sarin SK, Sharma G, Banerjee S, Kathayat R, Malhotra V. Hepatic fibrogenesis using chronic arsenic ingestion studies in a murine model. *Ind. J. Exp. Biol.* 1999; **37**: 147–51.
- 22 Nayyar AK, Sharma BK, Sarin SK, Malhotra P, Broor SL, Sachdeva GK. Characterization of peripheral blood lymphocytes in patients with non-cirrhotic portal fibrosis: A comparison with cirrhotics and healthy controls. *J. Gastroenterol. Hepatol.* 1990; **5**: 554–9.
- 23 Okuda K, Obata H. Idiopathic portal hypertension (hepatoportal sclerosis). In: Okuda K, Benhamou JP, eds. *Portal Hypertension. Clinical and Physiological Aspects*. Tokyo: Springer, 1992; 271–87.
- 24 Nakanuma Y, Nonomura A, Hayashi M *et al.* Pathology of the liver in ‘idiopathic portal hypertension’ associated with autoimmune disease. *Acta Pathol. Jpn.* 1989; **39**: 586–92.
- 25 Saito K, Nakanuma Y, Takegoshi K *et al.* Nonspecific immunological abnormalities and association of autoimmune diseases in idiopathic portal hypertension. A study by questionnaire. *Hepatogastroenterology* 1993; **40**: 163–6.
- 26 Sarin SK, Malhotra V, Mehra NK, Anand BS, Taneja V. Familial aggregation in non-cirrhotic portal fibrosis: A study of four families. *Am. J. Gastroenterol.* 1987; **82**: 1130–4.
- 27 Okabayashi A. Experimental production of non-cirrhotic portal hypertension and splenomegaly with prolonged stimulation. In: Okuda K, Omata M, eds. *Idiopathic Portal Hypertension*. Tokyo: University of Tokyo Press, 1983; 197–205.



- 28 Nayak NC, Ramalingaswamy V. Obliterative portal venopathy of the liver. *Arch. Pathol.* 1979; **87**: 359–69.
- 29 Nakunuma Y, Hosono M, Sasaki M *et al.* Histopathology of the liver in non-cirrhotic portal hypertension of unknown etiology. *Histopathology* 1996; **28**: 195–204.
- 30 Sarin SK, Sethi KK, Nanda R. Measurement and correlation of wedged hepatic, intrahepatic, intrasplenic and intravariceal pressure in patients with cirrhosis of liver and non-cirrhotic portal fibrosis. *Gut* 1987; **28**: 260–6.
- 31 El Atti EA, Nevens F, Bogaerts K, Verbeke G, Fevery J. Variceal pressure is a strong predictor of variceal hemorrhage in patients with cirrhosis as well as in patients with non-cirrhotic portal hypertension. *Gut* 1999; **45**: 618–21.
- 32 De BK, Pal A, Santra A *et al.* Primary pulmonary hypertension in non-cirrhotic portal fibrosis. *Ind. J. Gastroenterol.* 1997; **16**: 85–7.
- 33 Vasia M, Curciorello JO, Corron SF *et al.* Idiopathic portal hypertension with splenic infarct. An unreported complication. *Acta Gastroenterol. Latinoam.* 2001; **31**: 27–30.
- 34 Soma J, Saieto T, Sato H, Ootaka T, Abe K. Membranoproliferative glomerulonephritis induced by portosystemic shunt surgery for non-cirrhotic portal hypertension. *Clin. Nephrol.* 1997; **48**: 274–81.
- 35 Kumar A, Bhuyan UN, Nundy S. Glomerulonephritis complicating non-cirrhotic portal fibrosis. *J. Gastroenterol. Hepatol.* 1998; **13** (Suppl. 1): 271–5.
- 36 Babbs C, Warnes TW, Haboubi NY. Non-cirrhotic portal hypertension with hypoxaemia. *Gut* 1998; **29**: 129–31.
- 37 Sarin SK, Agarwal SR. Idiopathic portal hypertension. *Digestion* 1998; **59**: 420–3.
- 38 Misra A, Guptan RC, Sarin SK. Momehtylglycenyxylidide (MEGX): a sensitive non-invasive method to differentiate NCPF and Child's A chronic liver disease. *Indian J. Gastroenterol.* 1997; **16** (Suppl. 2): A101 (Abstract).
- 39 Sarin SK, Lal K, Sachdev G, Nanda R, Tandon RK. Biliary lipid composition in patients with non-cirrhotic portal fibrosis: A comparison with compensated cirrhosis of the liver. *Liver* 1987; **7**: 38–42.
- 40 Mehta S, Gondal R, Saxena S, Sarin SK. Profile of hypersplenism in cirrhotic and non-cirrhotic portal hypertension. *Hepatology* 1994; **20**: A217 (Abstract).
- 41 Bajaj JS, Bhattacharjee J, Sarin SK. Coagulation profile and platelet functions in patients with extrahepatic portal vein obstruction and non-cirrhotic portal fibrosis and influence of hypersplenism. *J. Gastroenterol. Hepatol.* 2001; **16**: 641–6.
- 42 Sheth SG, Deo AM, Bichile SK *et al.* Coagulation abnormalities in non-cirrhotic portal fibrosis and extra-hepatic portal vein obstruction. *J. Assoc. Phys. India* 1996; **44**: 790–9.
- 43 Rangari M, Sinha S, Kapoor D, Mohan JC, Sarin SK. Prevalence of autonomic dysfunction in cirrhotic and non-cirrhotic portal hypertension. *Am. J. Gastroenterol.* 2002. in press.
- 44 Misra SP, Sarin SK, Gulati PK, Singal AK, Broor SL. Splenoportovenography. Safety, success rate and hemodynamic changes and natural history of splenic hematoma. *Ind. J. Gastroenterol.* 1991; **10**: 49–50.
- 45 Futagawa S, Fukazawa M, Musha H *et al.* Hepatic venography in non-cirrhotic idiopathic portal hypertension. Comparison with cirrhosis of the liver. *Radiology* 1981; **141**: 303–9.
- 46 Okuda K, Kimura K, Takayasu K. Percutaneous transhepatic portography and sclerotherapy. *Semin. Liver Dis.* 1982; **2**: 57–66.
- 47 Chandra R, Kapoor D, Tharakan A, Chaudhury A, Sarin SK. Portal biliopathy. *J. Gastroenterol. Hepatol.* 2001; **16**: 1086–92.
- 48 Chawla Y, Dilawari JB. Anorectal varices: Their frequency in cirrhotic and non-cirrhotic portal hypertension. *Gut* 1991; **32**: 309–11.
- 49 Sarin SK, Shahi HM, Jain M, Jain AK, Issar SK, Murthy NS. The natural history of portal hypertensive gastropathy: Influence of variceal eradication. *Am. J. Gastroenterol.* 2000; **95**: 2888–93.
- 50 Raval N, Shah N, Vani SN. Tropical splenomegaly syndrome. *Ind. J. Pediatr.* 1999; **58**: 679–81.
- 51 Sarin SK, Govil A, Jain AK *et al.* Prospective randomized trial of endoscopic sclerotherapy versus variceal band ligation for esophageal varices: Influence on gastric varices and variceal recurrence. *J. Hepatol.* 1994; **26**: 826–32.
- 52 Sarin SK, Nanda R, Gaur SK, Kumar N, Vij JC, Anand BS. Repeated endoscopic sclerotherapy for active variceal bleeding. *Ann. Surg.* 1985; **202**: 708–11.
- 53 Kochhar R, Goenka MK, Mehta SK. Outcome of injection sclerotherapy using absolute alcohol in patients with cirrhosis, non-cirrhotic portal fibrosis, and extrahepatic portal venous obstruction. *Gastrointest. Endosc.* 1991; **37**: 460–4.
- 54 Kire CF. Controlled trial of propranolol to prevent recurrent variceal bleeding in patients with non-cirrhotic portal fibrosis. *BMJ* 1989; **298**: 1363–5.
- 55 Sarin SK, Lamba GS, Kumar M, Misra A, Murthy NS. Comparison of endoscopic ligation and propranolol for the primary prevention of variceal bleeding. *N. Engl. J. Med.* 1999; **340**: 988–93.
- 56 Sarin SK, Lahoti D, Saxena SP, Murthy NS, Makwana UK. Prevalence classification and natural history of gastric varices: A long-term follow-up study in 568 portal hypertension patients. *Hepatology* 1992; **16**: 1343–9.
- 57 Sarin SK, Jain AK, Jain M, Gupta R. A randomized controlled trial of cyanoacrylate vs. alcohol injection in patients with isolated fundic varices. *Am. J. Gastroenterol.* 2002. in press.
- 58 Hiirota S, Ichikawa S, Matsumoto S *et al.* Interventional radiologic treatment of idiopathic portal hypertension. *Cardiovasc. Intervent. Radiol.* 1999; **22**: 311–14.
- 59 Mitra SK, Rao KL, Narasimhan KL *et al.* Side-to-side lienorenal shunt without splenectomy in non-cirrhotic portal hypertension in children. *J. Pediatr. Surg.* 1993; **28**: 398–401.
- 60 Warren WD, Henderson JM, Millikan WJ, Galambos JT, Bryan FC. Management of variceal bleeding in patients with noncirrhotic portal vein thrombosis. *Ann. Surg.* 1988; **207**: 623–34.
- 61 Mathur SK, Shah SR, Nagral SS, Soonawala ZF. Transabdominal extensive esophagogastric devascularization gastroesophageal stapling for management of noncirrhotic portal hypertension: Long-term results. *World J. Surg.* 1999; **23**: 1168–74.