

# Feasibility of Thoracoscopic Repair of Esophageal Atresia With Distal Fistula

By Klaas(N) M.A. Bax and David C. van der Zee  
Utrecht, The Netherlands

**Background/Purpose:** Evaluation of the feasibility of thoracoscopic correction of esophageal atresia with distal fistula.

**Methods:** Eight consecutive neonates with esophageal atresia and distal fistula were treated thoracoscopically. Mean birth weight was 3,048 g (range, 2,140 to 3,770). The patients were intubated endotracheally and placed in a  $\frac{3}{4}$  left prone position. Three cannulae were inserted along the inferior tip of the scapula. CO<sub>2</sub> was insufflated at a pressure of 5 mm Hg and a flow of 0.5 L/min. The fistula was either clipped or ligated. The proximal esophagus was opened and an anastomosis was made over a 6F or 8F nasogastric tube with interrupted 5-0 Vicryl.

**Results:** All procedures were completed thoracoscopically without major perioperative complications. The mean oper-

ating time was 198 minutes (range, 138 to 250). One patient had a major leak, resulting in a stormy postoperative course, but the leak healed on conservative treatment. This patient and 3 others had stenosis requiring dilatation, respectively, 3, 6, 12, and 1 times. The babies were fed after a median period of 8 days. The median hospital stay was 13 days.

**Conclusions:** Thoracoscopic repair of esophageal atresia with distal fistula is feasible. Larger series are needed to determine the exact place of the thoracoscopic approach. *J Pediatr Surg* 37:192-196. Copyright © 2002 by W.B. Saunders Company.

**INDEX WORDS:** Esophageal atresia, thoracoscopy, thoracoscopic repair.

SINCE THE DEVELOPMENT of endoscopic surgical techniques at the end of the 1980s of the last century, much progress has been made. Many of the operations that were performed classically open now can be performed endoscopically. This also has happened in pediatric surgery.<sup>1</sup> Reports of endoscopic repair of esophageal atresia are scarce. Esophageal atresia has been approached in a thoracoscopically assisted way through a minithoracotomy,<sup>2</sup> but there are only 2 case reports of complete thoracoscopic repair.<sup>3,4</sup> The evaluation of this operation is in phase 1 of technology assessment according to Jennett's classification, namely the evaluation of its feasibility and safety.<sup>5</sup> Our experience with a pure thoracoscopic approach in 8 consecutive patients with esophageal atresia and distal fistula forms the basis of this report.

*From the Department of Pediatric Surgery, Wilhelmina Children's Hospital, University Medical Center Utrecht, The Netherlands.*

*Presented at the 48th Annual International Congress of the British Association of Paediatric Surgeons, London, England, July 18-21, 2001.*

*Address reprint requests to Klaas(N) M.A. Bax, MD, PhD, FRCS(Ed), Department of Pediatric Surgery (KE.04.140.5), Wilhelmina Children's Hospital, University Medical Center Utrecht, P.O. Box 85090, 3508 AB Utrecht, The Netherlands.*

*Copyright © 2002 by W.B. Saunders Company*

*0022-3468/02/3702-0010\$35.00/0*

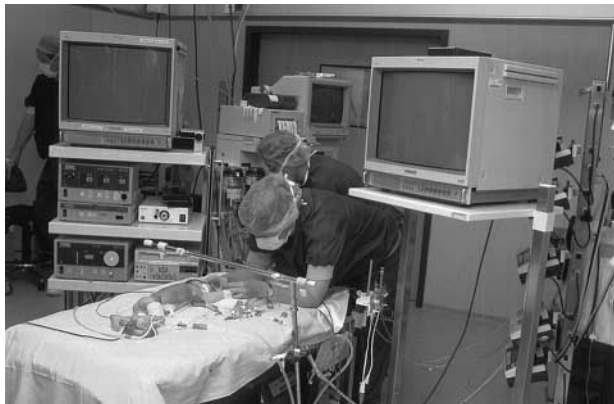*doi:10.1053/jpsu.2002.30253*

## MATERIALS AND METHODS

Eight consecutive patients with esophageal atresia and distal fistula were approached solely thoracoscopically. The mean gestational age was 39 weeks, and mean birth weight was 3,048 g (range, 2,140 to 3,770). Six babies had additional malformations, respectively: CHARGE association and patent ductus arteriosus, dextrocardia, VSD and horse shoe kidney, grade 3 vesicoureteric reflux, tracheal stenosis, and low anorectal anomaly.

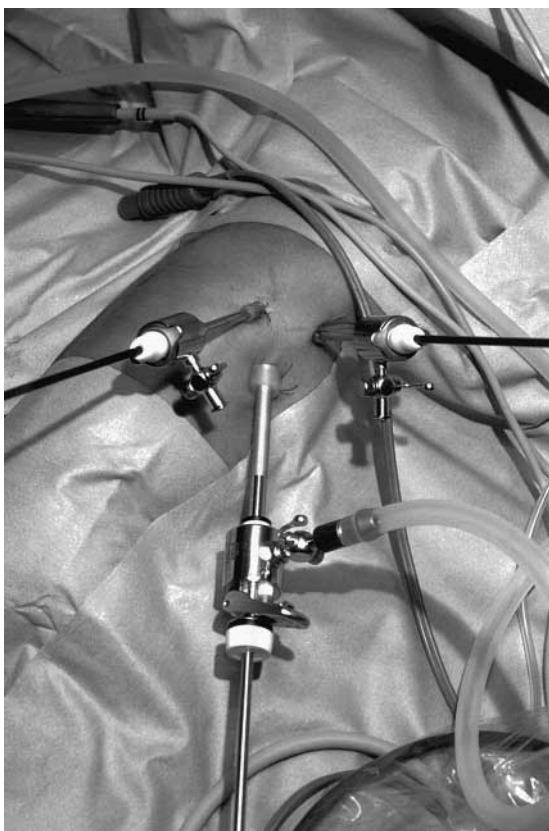
Preoperatively informed consent was obtained from the parents in the presence of the intensive care nurse caring for the particular baby. Apart from talking about esophageal atresia and its possible associated malformations, we talked extensively about the surgical approach. They were told that the classic repair is done through a thoracotomy, but that we thought that the same operation could be performed thoracoscopically. We explained the advantages in terms of reduced trauma to the thoracic wall and the better cosmetic result, but told them also that a thoracoscopic repair would be more difficult and would take more time. At the same time we explained that we started to do endoscopic surgical operations in children in 1992, and we had gained a considerable experience in doing this type of surgery even in the newborn. For each new patient with esophageal atresia we told the parents how many we had operated on endoscopically and what the outcome had been.

The patients were intubated endotracheally and placed in a  $\frac{3}{4}$  left prone position (Fig 1). The surgeon stood at the left side of the table with the screen opposite at the right upper end of the table. The camera operator stood at the patient's right side, and the scrub nurse at the bottom end of the table. Three cannulae were inserted in a V-shape. The first cannula, a 6-mm one to take a 5-mm 30° telescope, was inserted in an open way about 1 cm below the angle of the scapula. Two 3.8-mm cannulae, to be used for 3-mm working instruments, were inserted symmetrically higher, 1 posterior and 1 anterior to the scapula (Fig 2). CO<sub>2</sub> was insufflated at a pressure of 5 mm Hg and a flow of 0.5 L/min. The approach was transpleural. An excellent view of the

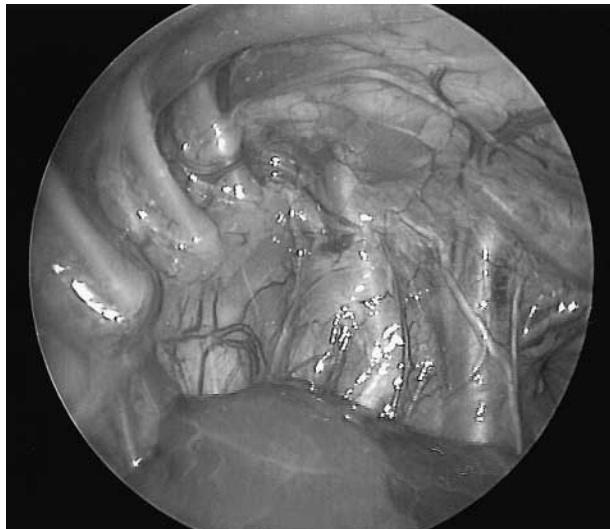

**Fig 1.** The patient is placed in a 3/4 left prone position. Two television screens are positioned at either side of the upper end of the table.

regional anatomy was obtained with the vena cava and overlying phrenic nerve anteriorly and the vertebral column posteriorly (Fig 3). The vagus nerve was seen clearly and used as a guide to identify the esophagus. The azygos vein was freed and preferably transected between 000 Vicryl ligatures. Next the mediastinal pleura behind the



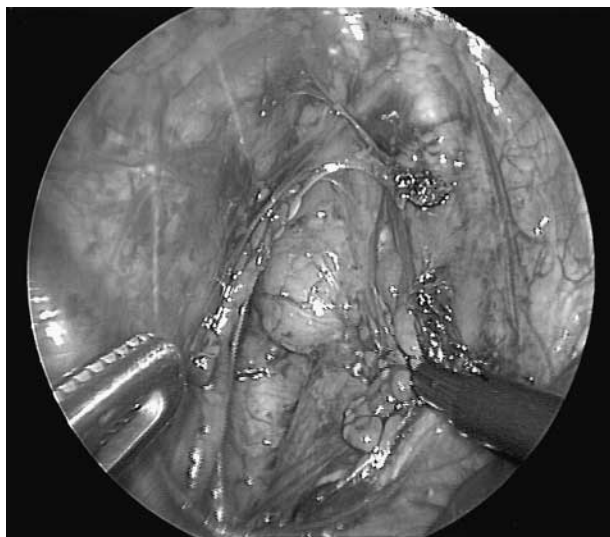**Fig 2.** Position of the cannulae. View taken from the left, where the surgeon is standing. A 6-mm cannula was inserted 1 cm below the inferior angula of the scapula to hold a 5-mm 30° telescope. Two 3.8-mm cannulae were inserted in a symmetrical way higher up, 1 anterior and 1 posterior to the scapula.



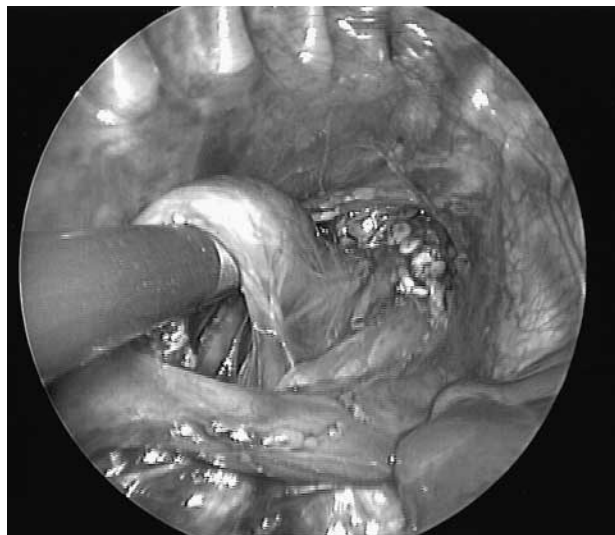**Fig 3.** Internal view of the apex of the right chest. The collapsed lung is at the inferior part of the picture. More proximal and medial the superior caval vein accompanied by the phrenic nerve is seen. Posteriorly, the heads of the ribs can be seen making contact with the vertebral column.

proximal esophageal blind pouch was opened and mobilized (fig 4). For guidance, the anesthesiologist pushed on the double lumen tube in the proximal esophagus. Grasping of the esophagus was avoided. The cleavage plane between the proximal esophagus and trachea was only approached after the proximal esophagus had been mobilized as far as possible. The cleavage plane always was opened above the distal end of the pouch where there are no connecting muscle fibers between the pouch and the trachea. By doing so, the distal connecting muscle fibers could be identified and transected without damage to the pouch or trachea.

The site of the distal fistula was suspected by the expansion during



**Fig 4.** The posterior pleura has been incised, and the proximal esophageal pouch is being mobilized. Muscle fibers connecting the proximal esophagus with the trachea are seen clearly.



**Fig 5.** The distal esophagus has been dissected free just at the site of the fistula. The azygos vein is still intact.

inspiration. The most proximal end of the distal esophagus was isolated as close to the trachea as possible to avoid transection of vagal nerve branches to the distal esophagus (Fig 5). Next, the fistula was ligated with 00 Vicryl and transected distal to the ligature (Fig 6). The proximal esophagus then was opened, and an anastomosis was performed over a 6F or 8F nasogastric tube with interrupted 5-0 Vicryl and knotted within the chest. It is best to start the anastomosis at the left side of the esophagus. Starting the anastomosis on the right side obscures vision and makes the left part of the anastomosis more difficult. By leaving the end of a suture a little longer, traction can be applied so that the next suture can be placed more easily.

No chest drainage tube was used, the cannulae were removed, and the skin ports were closed with SteriStrips. A routine chest radiograph was obtained on the table. No routine postoperative esophagograms nor dilations were carried out.

## RESULTS

None of the procedures needed to be converted to an open approach, and there were no intraoperative complications. The mean operating time was 198 minutes (range, 138 to 250). There were no deaths. One patient (CHARGE association together with a clinically relevant patent ductus arteriosus, requiring operative ligation) had a major leak on day 2. This resulted in a stormy postoperative course. The right chest was drained, and the leak eventually closed. Anastomotic stenosis requiring dilatation developed in this baby and 3 others, respectively, 3, 6, 12, and 1 times. The mean postoperative artificial ventilation period was 4.5 days (range, 3 to 34), and oral feeding was started on day 8 as a median (range, 2 to 15). The median hospital stay was 13 days (range, 10 to 65).

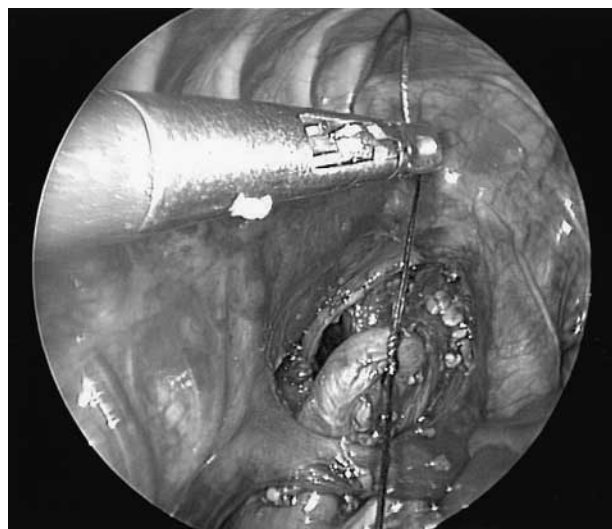
## DISCUSSION

A classical posterolateral thoracotomy generally is considered to be a major insult to the body, and the

morbidity that has been ascribed to it includes winged scapula, elevation or fixation of the shoulder, asymmetry of the chest wall, rib fusion, scoliosis, and breast and pectoral muscle maldevelopment.<sup>6-13</sup> Chronic pain after thoracic surgery, at least in adults, is a serious problem and has been reported in more than 50% of patients.<sup>14,15</sup> There is no information available in infants and children regarding chronic pain after classical thoracotomy.

Pediatric surgeons have tried to avoid the classic posterolateral thoracotomy. Sir Denis Browne<sup>16</sup> made a vertical skin incision, detached the serratus anterior muscle and then opened the intercostal space. Soucy et al<sup>17</sup> introduced the muscle-sparing thoracotomy into pediatric surgery, whereas Bianchi et al<sup>18</sup> advocate a transaxillary thoracotomy. In adults, muscle-sparing thoracotomies do preserve muscle strength but do not eliminate long-term wound-related discomfort.<sup>19</sup> This suggests that the spreading of the ribs after entering the thoracic cavity is one of the causes of postoperative pain.

There appears to be no doubt that the trauma to the thoracic wall during pure thoracoscopic operations is less when compared with a more classical approach both in terms of trauma to the skin and muscles and of trauma related to spreading of the ribs. The view obtained during a thoracoscopic approach is excellent, permitting a very precise dissection and conservation of small structures such as the fine branches of the vagus nerve to the esophagus. The transpleural route required for thoracoscopy could be regarded as a disadvantage. However, there are no hard data on the superiority of a retropleural thoracotomy when compared with a transpleural one. In contrast, several nonrandomised series have been published in which no difference in mortality and morbidity



**Fig 6.** The fistula is ligated close to the trachea and will be divided distal to the ligature.

could be established between the retropleural and transpleural route.<sup>20,21</sup> The insufflation of CO<sub>2</sub> at a pressure up to 5 mm Hg into the right chest was not a problem and was counteracted easily by a concomitant increase in inspiratory ventilator pressure. The ¾ left prone position together with the use of CO<sub>2</sub> kept the right lung well out of the way without any need for a lung retractor. In open surgery, the lung has to be retracted, and this interferes much more with ventilation than CO<sub>2</sub> insufflation.

An important discussion with a thoracoscopic repair of esophageal atresia with distal fistula is the level of endoscopic surgical expertise that has to be gained before this can be done. Especially, the intrathoracic suturing is not easy, not only because of the limited working space but also because appropriate needles currently are not available. To accommodate a 5-0 Vicryl-loaded needle through a 3.8-mm cannula, the needle has to be straightened. This has to be done manually and results in a less than optimal bend in the needle. Moreover, as a result of the straightening, the needle becomes quite long. The knotting in this series was done within the chest.

Extracorporeal knotting may be simpler and may save operating time, but we have no experience with it. With further experience, the operating time will come down as it has in all other types of endoscopic surgical operations.

Although this may be bias, the intensive care nurses and neonatologists caring for the patients are convinced that the thoracoscopic approach is much less painful.

A major anastomotic leak developed in 1 patient, the second in the series. This might have been caused by a technical error, eg, incomplete anastomosis as it became apparent on the second postoperative day. However, during the early postoperative period the child was unstable hemodynamically as a result of a patent ductus arteriosus, which required ligation. This baby and 3 others had clinically relevant stenosis requiring dilatation. Three of the 4 children are now symptom free. The remaining child, now 8 months old, still has recurrent symptomatic stenosis, despite optimal conservative anti-reflux therapy. The stomach pH is around 7 during day and night. The high incidence of stenosis seems to have been related to a technical error. Initially, we made too small an esophagotomy in the proximal esophagus. Even when only a tiny hole is made, the 10F Replogle tube is passed easily through it by dilation. In the last 3 patients, the proximal pouch was opened widely, and no stenosis has been observed.

This series shows that an esophageal atresia with distal fistula can be repaired thoracoscopically. More experience is needed to determine the exact place of this approach.

## REFERENCES

1. Bax NMA, Georgeson KE, Najmaldin AS, et al: Endoscopic surgery in children, Berlin, Springer, Germany, 1999
2. Robert M, Lardy H: Video-assisted repair of esophageal atresia, in Bax NMA, Georgeson KE, Najmaldin AS, et al (eds): Endoscopic surgery in children, Berlin, Germany, Springer, 1999, pp 130-133
3. Lobe TE, Rothenberg SS, Waldschmidt J, et al: Thoracoscopic repair of esophageal atresia in an infant: A surgical first. *Pediatr Endosurg Innov Techn* 3:141-148, 1999
4. Rothenberg SS: Thoracoscopic repair of a tracheoesophageal fistula in a newborn infant. *Pediatr Endosurg Innov Techn* 4:289-294, 2000
5. Jennett B: High technology medicine. Benefits and burdens. Oxford, England, Oxford University Press, 1986
6. Freeman NV, Walkden J: Previously unreported shoulder deformity following right lateral thoracotomy for esophageal atresia. *J Pediatr Surg* 4:627-636, 1969
7. Durning RP, Scoles PV, Fox OD: Scoliosis after thoracotomy in tracheoesophageal fistula patients. *J Bone & Joint Surg (AM)* 62:1156-1158, 1980
8. Jaureguizar E: Morbid musculoskeletal sequelae of thoracotomy for tracheoesophageal fistula. *J Pediatr Surg* 20:511-514, 1985
9. Cherup LL, Siewers RD, Futrell JW: Breast and pectoral muscle maldevelopment after anterolateral and posterolateral thoracotomies in children. *Ann Thorac Surg* 41:492-497, 1986
10. Westfelt JN, Nordwall A: Thoracotomy and scoliosis. *Spine* 16:1124-1125, 1991
11. Chetcuti P, Myers NA, Phelan PD, et al: Chest wall deformity in patients with repaired esophageal atresia. *J Pediatr Surg* 24:244-247, 1989
12. Emmel M, Ulbach P, Herse B, et al: Neurogenic lesions after posterolateral thoracotomy in young children. *Thorac Cardiovasc Surg* 44:86-91, 1996
13. Schier F, Korn S, Michel E: Experiences of a parent support group with the long-term consequences of esophageal atresia. *J Pediatr Surg* 36:605-610, 2001
14. Perttunen K, Tasmuth T, Kalso E: Chronic pain after thoracic surgery: A follow-up study. *Acta Anaesthesiol Scand* 43:563-567, 1999
15. Rogers ML, Duffy JP: Surgical aspects of chronic post-thoracotomy pain. *Eur J Cardiothorac Surg* 18:711-716, 2000
16. Browne D: patent ductus arteriosus. *Proc R Soc Med* 45:719-722, 1952
17. Soucy P, Bass J, Evans M: The muscle sparing thoracotomy in infants and children. *J Pediatr Surg* 26:1323-1325, 1991
18. Bianchi A, Sowande O, Alizai NK, et al: Aesthetics and lateral thoracotomy in the neonate. *J Pediatr Surg* 33:1798-800, 1998
19. Khan IH, McManus KG, McCraith A, et al: Muscle sparing thoracotomy: A biomechanical analysis confirms preservation of muscle strength but no improvement in wound discomfort. *Eur J Cardiothorac Surg* 18:656-661, 2000
20. Hicks LM, Masfield PB: Esophageal atresia and tracheoesophageal fistula. Review of thirteen years experience. *J Thorac Cardiovasc Surg* 81:358-363, 1981
21. McKinnon LJ, Koloske AM: Prediction and prevention of anastomotic complications of esophageal atresia and tracheoesophageal fistula. *J Pediatr Surg* 25:778-781, 1990

## Discussion

*Mr MacKinlay (Edinburgh, Scotland):* Congratulations on very nice results in this pioneering work. What was the smallest baby that you operated on? We tried it recently on a 1.6-kg infant. It was fairly difficult, but the view was tremendous. Unfortunately, in mine there was a right-sided aortic arch so that made the problem even greater. We successfully divided the azygos vein and then the fistula, but the upper pouch was inaccessible. Have you encountered any such problems, and what is the smallest baby?

*N.M.A. Bax (response):* The smallest baby was 2.4 kg, and the one intrathoracic anomaly that we encountered was a dextrocardia without intracardiac anomaly. The

repair was done through the right chest and went fine.

*L. Spitz (London, England):* Congratulations on your success. Can I ask you how you cope with a wide gap when you can only tie one suture at a time?

*N.M.A. Bax (response):* The easiest way to do that is not to open the proximal oesophagus but to have the anaesthetist pushing on the tube in the proximal oesophagus. In that way, the distal end of the proximal oesophagus is pouched quite far down. You then can make a few sutures between the distal fistula and the muscular layer of the proximal oesophagus. Next, you open the proximal oesophagus and make the rest of the anastomosis.